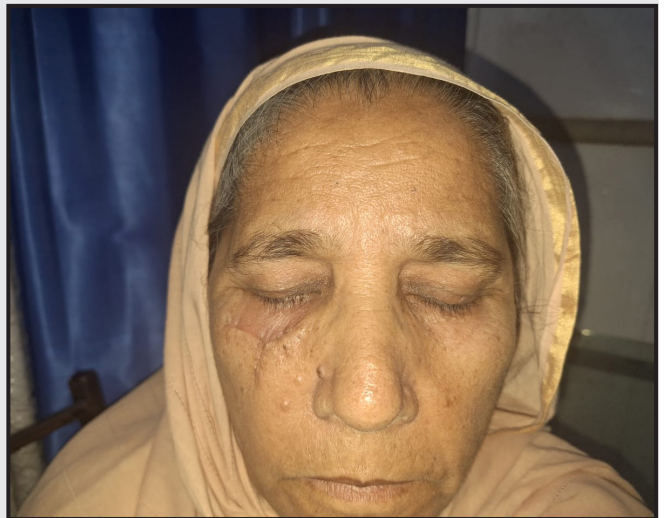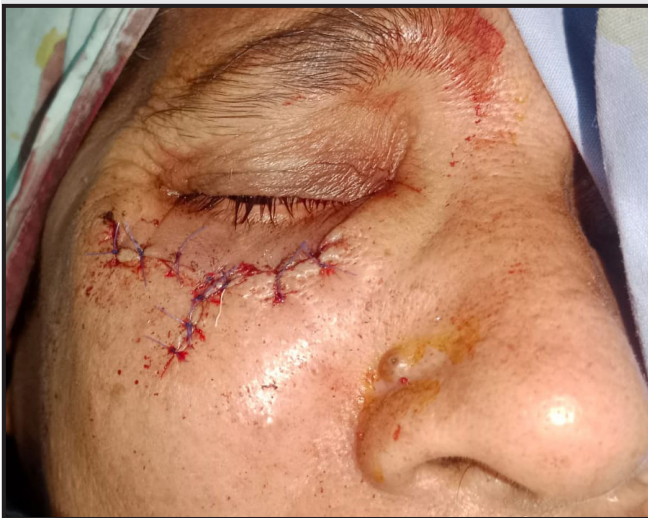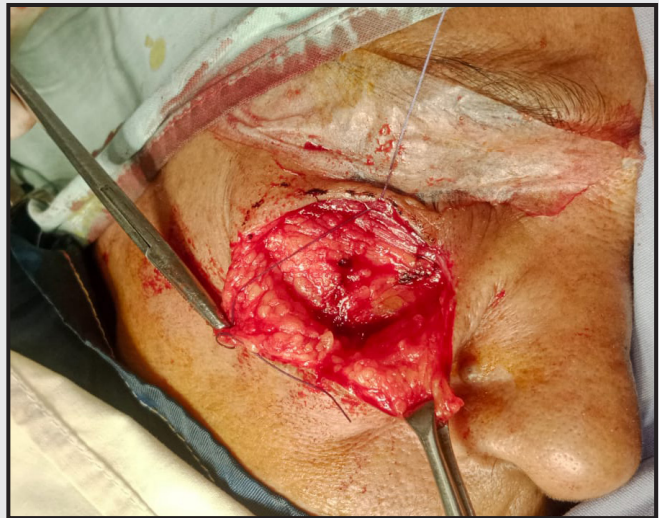


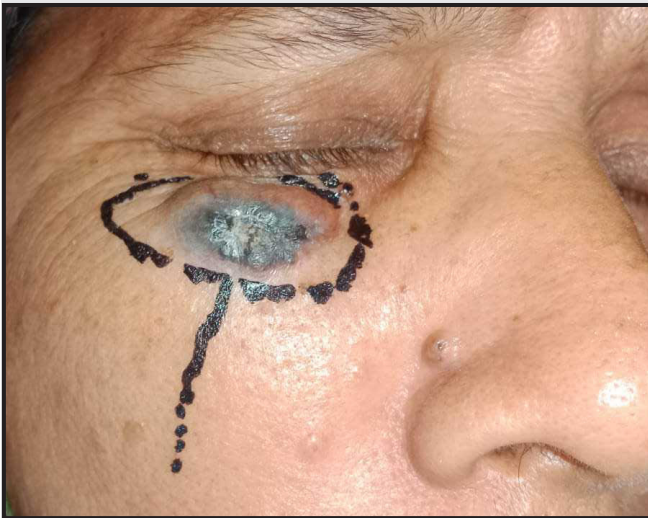MONTHLY

IMAGE

JUNE 2025

BCC (BASAL CELL CARCINOMA)



A 58 year old female presented with malignant skin lesion on right cheek. She underwent wide excision biopsy. The report revealed a basal cell carcinoma with clear margins. The post-operative recovery was unremarkable.

Patient recovered well.

Courtesy:

Prof. Awais Shuja FRCS, FCPS, MCPS-HPE
Department of Surgery
Independent Medical College, Faisalabad.

Kindly send interesting medical images
with brief clinical summary at:
editor@theprofesional.com