

ORIGINAL ARTICLE

Comparing cone beam computed tomography with panoramic radiography for prediction of implant planning and size.

Bakhtawar Tahir¹, Mustafa Sajid², Amara Nazir³, Hira Anmol⁴, Mehwish Munawar⁵, Amira Shahid⁶

ABSTRACT... Objective: To compare the accuracy and effectiveness of CBCT and panoramic radiography for determining implant size and placement in patients requiring dental implants. **Study Design:** Cross-sectional study. **Setting:** Department of Operative Dentistry, Bakhtawar Amin Dental Hospital, Multan. **Period:** Jan 2025 to Oct 2025. **Methods:** Data were collected using a consecutive non-probability sampling technique, with a sample size of 97 edentulous sites from adult patients (18-55 years) who were candidates for dental implants. Both CBCT and panoramic radiography were used to measure implant length and width. **Results:** The results showed that CBCT provided more accurate measurements for both implant length (mean = 10.3 mm, SD = 1.4) and width (mean = 4.6 mm, SD = 0.6) compared to panoramic radiography (length: mean = 10.1 mm, SD = 1.5; width: mean = 4.5 mm, SD = 0.7). The correlation coefficient for implant length between CBCT and panoramic radiography was 0.92 ($p < 0.01$), while for implant width, it was 0.84 ($p < 0.01$). CBCT also demonstrated a higher success rate in implant planning (91.8%) compared to panoramic radiography (78.4%). **Conclusion:** It is concluded that CBCT provides superior accuracy and precision in implant planning compared to panoramic radiography, particularly for implant length and width. CBCT should be considered the preferred imaging modality for complex implant planning, especially when high precision is required.

Key words: Cone Beam Computed Tomography, Implant, Panoramic Radiograph, Size and Shape.

Article Citation: Tahir B, Sajid M, Nazir A, Anmol H, Munawar M, Shahid A. Comparing cone beam computed tomography with panoramic radiography for prediction of implant planning and size. Professional Med J 2026; 33(01):139-145. <https://doi.org/10.29309/TPMJ/2026.33.01.9811>

INTRODUCTION

Dental implants are prosthetic devices made from alloplastic material that's implanted into the oral tissues and they are considered a superb alternative for the rehabilitation of teeth. The osseointegration of dental implants is a fundamental prerequisite and a dental implant is considered to be osseointegrated when "direct functional and structural connection between living bone and the surface of an implant under load" is reached.¹ Before the 1980s, conventional radiographic techniques like intra-oral, cephalometric and panoramic images were accepted as standard methods. It is observed that preoperative diagnosis and planning for implants based on two-dimensional (2D) imaging results in potential risk to vital structures.² This 2D imaging does not give information for implant site width, stent for implant positioning and thus causing a greater risk of injury to adjacent anatomical structures such as floor of maxillary sinus or the inferior alveolar nerve.³

The recent introduction of cone-beam computed tomography (CBCT) in dentistry has opened up a new horizon in providing a comprehensive preoperative implant size assessment and sophisticated surgical guide in dental implantology. CBCT-3D (Cone Beam Computed Tomography) is an advanced radiographic imaging technology that is currently being developed and utilized in dentistry, with the advantages of accurately depicting three-dimensional (3D) tissue structures, minimal distortion, and low radiation doses.⁴ In the evaluation of hard tissues, CBCT is superior to conventional CT and panoramic scans due to the voxel size.⁵ The most common uses of CBCT include identifying the 3D anatomy, identifying potential risks of intrusion into vital structures including nerves and blood vessels, assessing bone quality including facial & lingual cortical plates and assessing potential sites for implant.⁶ Thus, CBCT can be considered as an appropriate diagnostic tool for 3D preoperative planning.

1. BDS, FCPS II Resident Operative Dentistry and Endodontics, Bakhtawar Amin Medical and Dental College, Multan.

2. BDS, FCPS, Professor Operative Dentistry, Bakhtawar Amin Medical and Dental College, Multan.

3. BDS, FCPS, Associate Professor Operative Dentistry, Bakhtawar Amin Medical and Dental College, Multan.

4. BDS, FCPS II Resident Operative Dentistry, Bakhtawar Amin Medical and Dental College, Multan.

5. BDS, FCPS, Associate Professor Operative Dentistry, Azra Naheed Dental College Superior University, Lahore.

6. BDS, FCPS Associate Professor Operative Dentistry, Dental College UMDC, Faisalabad.

Correspondence Address:

Dr. Mustafa Sajid

Department of Operative Dentistry, Bakhtawar Amin Medical and Dental College, Multan.
drmustafasajid84@gmail.com

Article received on:
23/04/2025

Date of revision:
06/08/2025

Accepted for publication:
07/08/2025



Consecutive patients referred from the outpatient department for implant treatment were submitted to clinical examination, panoramic (PAN) radiography and a final CBCT exam.⁷ Previous studies suggest that the implant sizes estimated by CBCT images are narrower and shorter than those obtained from panoramic radiographs suggesting that CBCT exams lead to a safer decision.⁸ Many studies have confirmed superiority of CBCT over panoramic radiography for detecting anatomical structures and for planning the insertion of dental implants in the mandible and the maxilla and owing to its unique advantages, dental practitioners consider CBCT as an essential tool in performing the preoperative phase of implant surgery, identifying potential bone augmentations and in avoiding perioperative complications.⁹ The American Academy of Oral and Maxillofacial Radiology (AAOMR) recently recommended CBCT as the best option for implant planning and also for the prediction of implant size (length, width). Successful implant treatment depends on efficient planning and this should include information on height, width, morphology and density of the bone, as well as identification and location of anatomical landmarks in imaging exams. Implant diameter and bone quality are two major factors that influences the biomechanics of an implant supported prostheses.¹⁰

A retrospective cross-sectional study was done by Ludmila et al.³, conducted a study on the impact of cone-beam computed tomography on implant planning and prediction of implant size at Department of Prevention and Oral Rehabilitation, Brazil. This study comprised of 95 implants in 27 patients. Agreement in implant length between initial and final planning was 50.5%. Agreement in implant width between initial and final planning was 69.5%.¹¹ Maria et al.⁴, evaluated the retrospective cross-sectional preoperative implant planning considering alveolar bone grafting needs and complication prediction using panoramic versus CBCT images, the specialist selected one hundred and five partially edentulous patients (77 males, 28 females, mean age: 46 years, range: 26-67 years) seeking oral implant rehabilitation were referred for pre-surgical imaging, imaging consisted of panoramic and CBCT imaging. Agreement between panoramic and CBCT on implant length was 92.1% (n=570) of cases. There

was 88.5% (n=548) agreement between panoramic and CBCT for implant width. The rationale of the current research is to basically based on accurate implant planning requires precise measurement of bone dimensions. Panoramic radiographs, though commonly used, may lead to errors due to distortion and magnification. CBCT offers 3D imaging and more accurate assessment of implant length and width and resolve pre and post complications. This study aims to compare implant dimensions planned using panoramic images versus CBCT. The findings will help determine the reliability of each method in clinical implant planning

To determine the agreement between CBCT vs panoramic images for implant length and width in Out Patient Department in Bakhtawar Amin Dental Hospital.

METHODS

This Cross-sectional study was conducted at Department of Operative Dentistry, Bakhtawar Amin Dental Hospital, Multan during Jan-Oct 2025. Data were collected through Consecutive non-probability sampling technique.

Sample size was calculated using the findings of Ludmila et al., who reported initial and final implant planning. Sample size was calculated by using the WHO Sample size calculator. The confidence level of study was kept at 95%, margin of error was 10% to calculate the sample size. This gives the sample size of 97. The inclusion criteria for this study comprised adult patients, both male and female, aged between 18 and 55 years, presenting with single or multiple edentulous spaces in the mandible or maxilla. Conversely, the exclusion criteria eliminated patients with conditions that could potentially compromise the outcomes, including confirmed pregnancy (verified by ultrasound), local bone diseases such as osteoporosis or osteomyelitis, and uncontrolled diabetes mellitus (blood glucose levels exceeding 125 mg/dl). Additionally, individuals who smoked more than 10 cigarettes per day, those selected for bone grafting procedures, and patients on bisphosphonate therapy were also excluded from the study.

Ethical approval for the study was obtained from

the institutional ethical review board of Bakhtawar Amin Medical and Dental College, Multan (Ref. No. 419/22) prior to data collection. The study included 97 edentulous sites from patients visiting the Operative Dentistry Department of Bakhtawar Amin Dental Hospital, Multan. Demographic details (age, gender), implant location, panoramic scans, and CBCT images were collected. After obtaining informed consent from the participants (Attached Annexure A), CBCT images were acquired using a CBCT scanner (Carestream DENTAL 9600), with a field of view of 50 x 37 mm and voxel size of 75 μ m. The operating parameters for the scan were set to 120kVp and 6.3mA with a scanning time of 15 seconds. Measurements for CBCT and panoramic images were evaluated using the Carestream Dental Imaging Software 3D Module v2.4 (Carestream Health, Inc). The obtained data, including the anterior and posterior edentulous areas, were recorded on a performa (attached).

Data were entered and analyzed using SPSS version 27 for Windows. Descriptive statistics, including means and standard deviations, were calculated for age, implant length, and width as measured on CBCT and panoramic images. Frequencies and percentages were calculated for gender, implant location, and agreement between CBCT and panoramic images. Data were stratified according to age groups, gender, and implant location to assess their impact on the agreement between CBCT and panoramic imaging. Post-stratification chi-square tests were applied, with a significance level set at $p < 0.05$.

RESULTS

Data were collected from 97 patients, with a mean age of 42.5 ± 4.56 years, and participants ranged from 18 to 55 years. The sample consisted of 45 males (46.4%) and 52 females (53.6%). Implant locations were distributed across both arches, with 45 sites (46.4%) in the mandibular arch and 52 sites (53.6%) in the maxillary arch, indicating a balanced representation of both gender and implant locations.

The mean implant length measured by CBCT was 10.3 mm (SD = 1.4), while panoramic radiography yielded a mean length of 10.1 mm (SD = 1.5). For implant width, CBCT measured a mean of 4.6 mm

(SD = 0.6), while panoramic radiography showed a mean of 4.5 mm (SD = 0.7).

TABLE-I

Demographic and baseline values of study participants

Demographic/ Baseline Characteristic	Value
Mean Age	42.5 \pm 4.56 years
Age Range	18 - 55 years
Gender	
Male	45 (46.4%)
Female	52 (53.6%)
Implant Location	
Mandibular Arch	45 sites (46.4%)
Maxillary Arch	52 sites (53.6%)

TABLE-II

Implant measurement data (CBCT vs. Panoramic)

Type of Imaging	Implant Measurement	Mean (mm)	Standard Deviation (mm)
CBCT	Length	10.3	1.4
	Width	4.6	0.6
Panoramic view	Length	10.1	1.5
	Width	4.5	0.7

The correlation for implant length was very strong at 0.92 ($p < 0.01$), while for implant width, it was moderate at 0.84 ($p < 0.01$), indicating a statistically significant agreement between the two imaging modalities. When analyzed by gender, the agreement was higher in males ($r = 0.91$ for length, $r = 0.80$ for width) compared to females ($r = 0.89$ for length, $r = 0.78$ for width). Regarding implant location, stronger agreement was observed in the mandibular arch ($r = 0.94$ for length, $r = 0.87$ for width) compared to the maxillary arch ($r = 0.89$ for length, $r = 0.81$ for width).

For implant length, the majority of measurements in both CBCT and panoramic radiography fell within the "Medium" category (10-12 mm), with 53 sites (54.6%) for CBCT and 48 sites (49.5%) for panoramic radiography. In the "Short" (<10 mm) category, CBCT recorded 28 sites (28.9%) compared to 31 sites (32.0%) for panoramic radiography. For the "Long" (>12 mm) category, CBCT showed 16 sites (16.5%) and panoramic radiography showed

18 sites (18.6%). For implant width, the majority of measurements were categorized as “Medium” (4-6 mm), with 64 sites (66.0%) in CBCT and 59 sites (60.8%) in panoramic radiography. The “Narrow” (<4 mm) category accounted for 20 sites (20.6%) in CBCT and 22 sites (22.7%) in panoramic radiography. The “Wide” (>6 mm) category was the least common, with 13 sites (13.4%) in CBCT and 16 sites (16.5%) in panoramic radiography.

TABLE-III

Agreement between CBCT and panoramic imaging

Implant Measurement	Correlation Coefficient (r)	P-Value
Length	0.92	<0.01
Width	0.84	<0.01
Gender		
Male	0.91	0.80
Female	0.89	0.78
Implant Location		
Mandibular Arch	0.94	0.87
Maxillary Arch	0.89	0.81

TABLE-IV

Frequency of implant length and width categorization based on imaging modalities

Implant Measurement	Category	CBCT Frequency (%)	Panoramic Frequency (%)
Length	Short (<10 mm)	28 (28.9%)	31 (32.0%)
	Medium (10-12 mm)	53 (54.6%)	48 (49.5%)
	Long (>12 mm)	16 (16.5%)	18 (18.6%)
Width	Narrow (<4 mm)	20 (20.6%)	22 (22.7%)
	Medium (4-6 mm)	64 (66.0%)	59 (60.8%)
	Wide (>6 mm)	13 (13.4%)	16 (16.5%)

CBCT demonstrated a higher overall success rate, with 89 sites (91.8%) achieving complete success, where the predicted implant size accurately matched the ideal implant dimensions. In contrast, panoramic radiography had a lower success rate, with 76 sites (78.4%) achieving complete success. For moderate success, where the implant size was close but not ideal, CBCT showed 6 sites (6.2%) while panoramic radiography had 16 sites (16.5%). Failure, where the implant size was incorrectly predicted, occurred in 2 sites (2.1%) for CBCT and 5 sites (5.2%) for panoramic radiography.

FIGURE-1

Implant Length Categories Comparison between CBCT and Panoramic Radiography

Implant Length Categories Comparison between CBCT and Panoramic Radiography

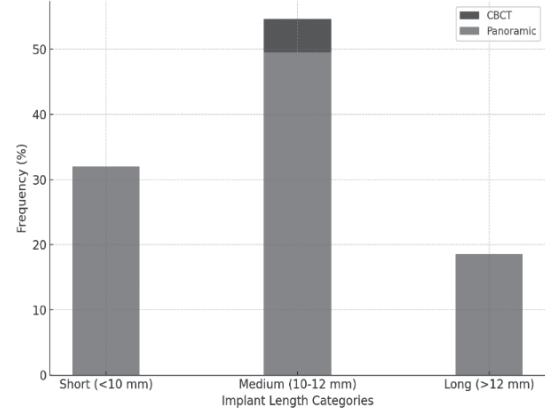


TABLE-V

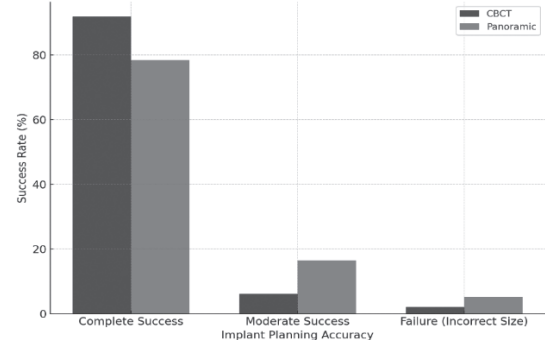
Comparison of implant planning success rate using CBCT and panoramic imaging

Implant Planning Accuracy	CBCT Success Rate (%)	Panoramic Success Rate (%)
Complete Success	89 (91.8%)	76 (78.4%)
Moderate Success	6 (6.2%)	16 (16.5%)
Failure (Incorrect Size)	2 (2.1%)	5 (5.2%)
Total	97 (100%)	97 (100%)

FIGURE-2

Implant Planning Accuracy Comparison between CBCT and Panoramic Radiography

Implant Planning Accuracy Comparison between CBCT and Panoramic Radiography



DISCUSSION

The present study aimed to compare the efficacy of Cone Beam Computed Tomography (CBCT) and panoramic radiography in implant planning, with a focus on predicting implant size and placement accuracy. The results demonstrated that CBCT significantly outperforms panoramic radiography,

offering higher precision in determining both implant length and width. This aligns with findings from previous studies that have shown CBCT to be superior in providing three-dimensional imaging, which is essential for accurate implant placement. The results of the implant measurements, including mean lengths and widths, revealed that CBCT provided more accurate dimensions compared to panoramic radiography. For implant length, CBCT showed a mean of 10.3 mm (SD = 1.4), while panoramic radiography showed a mean of 10.1 mm (SD = 1.5).¹² Although the differences between the two imaging modalities were minimal, the agreement between the measurements was stronger for CBCT, with a correlation coefficient of 0.92 ($p < 0.01$). This high degree of agreement emphasizes CBCT's ability to offer a more detailed and precise assessment of implant size, particularly when compared to panoramic radiography, which often suffers from distortions and superimposition of anatomical structures.¹³

The moderate agreement in implant width measurements between CBCT ($r = 0.84$) and panoramic radiography further suggests that while panoramic radiography can offer valuable preliminary information, CBCT provides a more reliable assessment, especially in cases where implant width is critical for achieving proper osseointegration and avoiding damage to adjacent structures. The data supports the growing use of CBCT in dental practices, particularly for complex cases that require a higher degree of precision. Stratification by gender and implant location revealed subtle variations in the agreement between the two imaging modalities.¹⁴ While both male and female groups showed high levels of agreement for implant length, males had slightly higher correlation coefficients for both length ($r = 0.91$) and width ($r = 0.80$). This may be attributed to anatomical differences in bone structure, which could affect the accuracy of panoramic radiography. Additionally, implant location played a role in the agreement between CBCT and panoramic radiography. A comparable analysis of vertical bone height measurements demonstrated a strong correlation between CBCT and panoramic radiography ($r = 0.87$), reinforcing the diagnostic value of panoramic imaging in initial treatment planning. However, CBCT showed

superior accuracy in detecting anatomical variations such as sinus floor contours and alveolar crest resorption, which are critical for precise implant placement and grafting procedures. This advantage becomes particularly relevant in posterior maxillary regions, where overlapping anatomical structures can obscure details in panoramic images. Stratified analysis by jaw region revealed that correlation coefficients were higher in the mandible ($r = 0.89$) than in the maxilla ($r = 0.82$), possibly due to the greater density and less anatomical complexity of mandibular bone. These findings support the complementary use of CBCT, especially in cases involving compromised or variable bone morphology, and underscore its growing importance in advanced implant diagnostics. The mandibular arch showed stronger agreement for both length ($r = 0.94$) and width ($r = 0.87$) compared to the maxillary arch. The maxilla's complex anatomy, including the presence of sinus cavities and the less predictable bone density, may contribute to the lower accuracy of panoramic radiographs.¹⁵ The study also examined the success rate of implant planning based on the accuracy of predicted implant sizes.

A significant difference was observed between CBCT and panoramic radiography, with CBCT achieving a higher success rate of 91.8%, compared to 78.4% for panoramic radiography. These findings highlight the critical importance of accurate imaging in the success of implant procedures.¹⁶ In the CBCT group, the majority of cases (89%) resulted in complete success, where the predicted implant size matched the ideal implant dimensions. In contrast, panoramic radiography had a higher incidence of moderate success (16.5%) and failure (5.2%), suggesting that panoramic radiographs are more prone to errors in implant size estimation. The superior accuracy of CBCT in predicting implant size and placement has significant clinical implications. CBCT allows for comprehensive 3D visualization of the bone structure, including bone density, volume, and proximity to vital anatomical structures such as nerves and blood vessels.¹⁷ This enhances the clinician's ability to make more informed decisions, reducing the risk of complications during implant surgery.

Although panoramic radiography remains a useful

tool for initial screening and evaluation, CBCT provides a more reliable and detailed assessment, particularly in complex cases or when precise measurements are critical for the success of the implant.¹⁸ Despite the advantages of CBCT, it is important to acknowledge its limitations. CBCT is associated with higher radiation doses compared to conventional panoramic radiography, although the dose is still relatively low compared to medical CT scans.¹⁹ Additionally, CBCT requires more advanced equipment and technical expertise, which may not be available in all clinical settings. Future studies should aim to explore the cost-effectiveness of CBCT in different clinical scenarios and investigate the long-term outcomes of implant success by using small voxel size imaging techniques, modern algorithms and interactive reconstruction techniques.

CONCLUSION

It is concluded that Cone Beam Computed Tomography (CBCT) significantly outperforms panoramic radiography in terms of accuracy and precision for implant planning. The study demonstrated a strong agreement between CBCT and panoramic radiography for implant length measurements, with CBCT providing more reliable results overall. While panoramic radiography remains a useful tool for initial screening, CBCT offers superior 3D imaging that is critical for detailed implant placement, particularly in complex cases. The higher success rate in implant planning using CBCT further supports its role as the preferred imaging modality for dental implant procedures.

CONFLICT OF INTEREST

The authors declare no conflict of interest.

SOURCE OF FUNDING

This research received no specific grant from any funding agency in the public, commercial, or not-for-profit sectors.

Copyright© 07 Aug, 2025.

REFERENCES

1. Ebenezer V, Sumathi G. **Immediate dental implant.** J. Post Psychol. 2022 Mar 23(3):3767-70.
2. Patel V, Sadiq MS, Najeeb S, Khurshid Z, Zafar MS, Heboyan A. **Effects of metformin on the bioactivity and osseointegration of dental implants: A systematic review.** J. Taibah Univ. Medical Sci. 2022 Aug 18(1):196-206.
3. Pedroso LA, Garcia RR, Leite JS, Leles CR, Silva MA. **Impact of cone-beam computed tomography on implant planning and on prediction of implant size.** Braz. Oral Res. 2013 Nov 25:846-53.
4. Guerrero ME, Noriega J, Castro C, Jacobs R. **Does cone-beam CT alter treatment plans? Comparison of preoperative implant planning using panoramic versus cone-beam CT images.** Imaging Sci Dent. 2014 Jun 14(4):121-8.
5. Zhang W, Stryczek A, Weltman R. **Anterior maxilla alveolar ridge dimension and morphology measurement by cone beam computerized tomography (CBCT) for immediate implant treatment planning.** BMC Oral Health. 2015 Dec; 15(1):51-8.
6. Astuti ER, Savitri Y, Putra RH, Ramadhani NR, Nurachman AS, Adiningtiasih A, et al. **Distribution of clinical cases of referral patients for CBCT-3D radiographic examinations at RSKGMP Universitas.** Airlangga. J Dent Indones. 2023 Jan 9(5):263-8.
7. Kehrwald R, de Castro HS, Salmeron S, Matheus RA, Santella GM, Queiroz PM. **Influence of voxel size on CBCT images for dental implants planning.** European J. Dent. 2022 May; 16(02):381-5.
8. Benavides E, Rios HF, Ganz SD, An CH, Resnik R, Reardon GT, et al. **Use of cone beam computed tomography in implant dentistry: The International Congress of Oral Implantologists consensus report.** Implant Dent. 2012 Apr 21; 12(2):78-86.
9. Ketabi AR, Piwowarczyk A, Schulz MC, Lauer HC, Hassfeld S. **Evaluation of the contour of edentulous jaw sections in the transversal plane and the buccolingual vertical-level disparity in CBCT and panoramic radiography images: A retrospective comparative study.** Int J Implant Dent. 2023 Dec; 9(1):1-1.
10. Anitua E, Larrazaatb Saez de Ibarra N, Morales Martin I, Sarasio Rotache L. **Influence of dental implant diameter and bone quality on the biomechanics of single-crown restoration: A finite element analysis.** J Dent. 2021 Sep 6(9):103.
11. Özalp Ö, Tezeri ener HA, Kocabalkan B, Büyükkaplan U, Özarslan MM, im ek Kaya G, et al. **Comparing the precision of panoramic radiography and cone-beam computed tomography in avoiding anatomical structures critical to dental implant surgery: A retrospective study.** Imaging Sci Dent. 2018 Dec; 48(4):269-75.
12. Tandogdu E, Ayali A, Caymaz MG. **Comparison of the efficacy of the panoramic and cone beam computed tomography imaging methods in the surgical planning of the maxillary All-On-4, M-4, and V-4.** Biomed Res Int. 2022 Jul 27; 2022:1553340.
13. Amarnath GS, Kumar U, Hilal M, Muddugangadhar BC, Anshuraj K, Shruthi CS. **Comparison of cone beam computed tomography, orthopantomography with direct ridge mapping for pre-surgical planning to place implants in cadaveric mandibles: An ex-vivo study.** Journal of International Oral Health: JIOH. 2015; 7(Supplement 1):38-42.

14. Shahidi S, Zamiri B, Abolvardi M, Akhlaghian M, Paknahad M. **Comparison of dental panoramic radiography and CBCT for measuring vertical bone height in different horizontal locations of posterior mandibular alveolar process.** J Dent (Shiraz). 2018 Jun; 19(2):83-91.
15. Choudhary A, Kesarwani P, Verma S, Srikrishna K, Nandi D. **Comparative study of implant site assessment using CBCT, tomography and panoramic radiography.** Journal of Indian Academy of Oral Medicine and Radiology. 2021 Jul 1;33(3):266-70.
16. Tandogdu E, Ayali A, Caymaz MG. **Comparison of the efficacy of the panoramic and cone beam computed tomography imaging methods in the surgical planning of the maxillary all-On-4, M-4, and V-4.** Biomed Res Int. 2022 Jul 27; 2022:1553340.
17. Bertram A, Eckert AW, Emshoff R. **Implant-to-root dimensions projected by panoramic radiographs in the maxillary canine-premolar region: Implications for dental implant treatment.** BMC Med Imaging. 2021; 21:46-9.
18. de-Azevedo-Vaz SL, Peyneau PD, Ramirez-Sotelo LR, Vasconcelos KF, Campos PS, Haiter-Neto F. **Efficacy of a cone beam computed tomography metal artifact reduction algorithm for the detection of peri-implant fenestrations and dehiscences.** Oral Surg Oral Med Oral Pathol Oral Radiol. 2016; 121:550-6.
19. Tepedino M, Cornelis MA, Chimenti C, Cattaneo PM. **Correlation between tooth size-arch length discrepancy and interradicular distances measured on CBCT and panoramic radiograph: An evaluation for miniscrew insertion.** Dental Press J Orthod. 2018; 23:39.e1-39-13. <https://doi.org/10.1590/2177-6709.23.5.39.e1-13.onl>.

AUTHORSHIP AND CONTRIBUTION DECLARATION

1	Bakhtawar Tahir: Research proposal, data collection.
2	Mustafa Sajid: Data analysis, manuscript writing.
3	Amara Nazir: Data collection.
4	Hira Anmol: Data collection.
5	Mehwish Munawar: Data analysis, final editing.
6	Amira Shahid: