



HEPATOTOXICITY; PROTECTIVE EFFECT OF SILYMARIN AGAINST METHOTREXATE INDUCED IN MICE

Aamna Khokhar¹, Aisha Qayyum², Momina Khokhar³

1. MBBS, M.Phil. (Pharmacology)
Assistant Professor
Women Medical and Dental
College, Abbottabad.
2. MBBS, M.Phil, Ph.D.
Associate Professor of
Pharmacology
Fazaia Medical College, Islamabad.
3. MBBS, MCPS,
Registrar,
Pakistan Institute of Medical
Sciences, Islamabad.

Correspondence Address:

Aamna Khokhar
Assistant Professor
Women Medical and Dental College,
Abbottabad.
dr.aamnakhokhar@yahoo.com

Article received on:

12/01/2017

Accepted for publication:

15/05/2017

Received after proof reading:

08/08/2017

ABSTRACT... Objectives: To evaluate the protective role of silymarin against methotrexate (MTX) induced hepatotoxicity in mice. **Study design:** Randomized controlled trial on animal model. **Period:** 06 months from March 2016 to August 2016. **Settings:** Department of Pharmacology and Therapeutics, Army Medical College, Rawalpindi. **Material and Methods:** Thirty male BALB/c mice were randomly divided into five groups (n=6). Group A received 0.2 ml normal saline intraperitoneally served as control for MTX. Group B received 0.2 ml distilled water orally for 7 days served as control for oral silymarin. Group C received single intraperitoneal injection of MTX 20 mg/kg. Group D received silymarin 25 mg/kg orally for seven days. Group E received silymarin 25 mg/kg orally for 7 days with MTX 20 mg/kg intraperitoneally at day 4. Blood samples for measuring serum ALT (Alanine Transaminase), AST (Aspartate transaminase) and ALP (Alkaline Phosphatase) along with liver samples for hepatic histological examination were taken after 24 hours of last dose. **Results:** Silymarin show hepatoprotective effect against MTX induced hepatotoxicity. **Conclusion:** Silymarin has hepatoprotective potential when administered along with MTX.

Key words: Hepatoprotective, Hepatotoxicity, Methotrexate, Silymarin.

Article Citation: Khokhar A, Qayyum A, Khokhar M. Hepatotoxicity; Protective effect of silymarin against methotrexate induced in mice. Professional Med J 2017;24(8):1200-1205. DOI: 10.17957/TPMJ/17.3820

INTRODUCTION

Methotrexate (MTX) is an antifolate subclass of antimetabolites. It is widely used in cancer chemotherapy as well as in autoimmune diseases, alone or in combination with other drugs. It is used in low doses (< 50 mg/m²) in rheumatoid arthritis and in high doses (> 500 mg/m²) in leukemias and in severe psoriasis resulting in hepatic fibrosis and cirrhosis.¹

The incidence of hepatotoxicity with mean dose of 12.5 mg/wk MTX when used for 3.5 to 4 years has been calculated for both elevated liver enzymes and liver biopsies. The incidence of LFTs above upper normal limit is 49 percent and 17 percent of rheumatoid arthritis patients have raised LFTs 2 to 3 times the upper normal limit. Liver biopsies showed 15.3 percent of patients with mild fibrosis, 1.3 percent with moderate to severe fibrosis and 0.5 percent with cirrhosis showing chronic liver damage.^{2,3}

Silymarin is a natural active ingredient of plant Milk thistle or Saint Mary's thistle. The botanical name of this plant is *Silybum marianum*. The standardized dried seed extracts of *Silybum marianum* contains 70–80 percent of a flavonolignan complex known as silymarin and 20–30 percent chemically undefined polyphenolic compounds.⁴ It is the inhibitor of free radicals and decreases the levels of oxidized glutathione. Standard extract has 50 percent more antioxidative potential as compared to individual standard compounds present in the extract.⁵ Silymarin is therapeutically efficacious in the management of hepatic cirrhosis, hepatic cirrhosis along with diabetes mellitus, toxin or drug induced hepatotoxicity, Amanita phalloides mushroom intoxication and various cancers due to its anti-cancerous and chemoprotective activities.^{4,6,7} Moreover, silymarin is a cheap, easily available over the counter drug in Pakistan which is commonly used in all types of hepatitis.

The purpose of this study is to establish the

hepatoprotective role of silymain in MTX induced hepatotoxicity in mice.

MATERIAL AND METHODS

Study place and duration

The study was a laboratory based randomized controlled trial that was carried out in animal house of the Department of Pharmacology and Therapeutics, Army Medical College, Rawalpindi from March 2016 to August 2016. The biochemical serum analysis and histopatological analysis of liver was performed with the collaboration of Department of Chemical Pathology, Army Medical College, Rawalpindi.

Sampling technique and sample size

Thirty animals were selected by non-probability convenience sampling method and divided randomly into 5 groups by lottery method. All groups contained 6 animals each.

Animals used

Male BALB/c mice of age 8-12 weeks and weighing 30-40 grams were obtained from NIH (National Institute of Health), Islamabad, Pakistan. The animals were kept in the animal house of Army medical college, Rawalpindi, Pakistan for two weeks before the commencement of actual study for acclimatization to the new environment. Standard laboratory conditions of twelve hour light and dark cycle, 20-25^o C temperature and 70 ± 15 percent humidity were maintained. Mice were given same rodent pellet diet and tap water ad libitum for the entire time period. Study protocol was approved by Ethical Committee of Centre for Research in Experimental and Applied Medicine (CREAM) Army Medical College, Rawalpindi.

Chemicals used

Methotrexate in injectable form manufactured by Korea United Pharm. Inc., Korea, was purchased from the local market. Pure extract of silymarin was procured from Pharmherb CO., limited, Qingdao, China through a licensed dealer. Other chemical used in the current study were of the analytical grade from standard companies.

Experimental design

Five groups (n=6) were intervened as follows

Group A (Control with intraperitoneal normal saline)

Mice in this group served as control for Group C and received 0.2 ml of normal saline intraperitoneally.

Group B (Control with oral distilled water)

This group received 0.2 ml distilled water per oral via oral gavage for 7 days and served as control for Group D

Group C (MTX)

Mice in this group served as toxic group in which hepatotoxicity was induced by single intraperitoneal injection of methotrexate 20 mg/kg.⁸

Group D (Silymarin)

Mice in this group received silymarin 25 mg/kg orally for 7 days.⁹

Group E (MTX + Silymarin)

Mice in this group received silymarin 25 mg/kg orally for 7 days with methotrexate 20 mg/kg intraperitoneally at day 4.

Assessment of liver dysfunction

Blood was collected by cardiac puncture under ether anesthesia, and the liver was also removed for histopathological analysis after 24 hours of last dose. The blood was allowed to clot at 25°C, and serum was analyzed for liver dysfunction by measuring ALT, AST and ALP levels using commercially available kits. For histopathological evaluation, samples of liver were fixed in 10 percent buffered formalin. Paraffin embedded sections of liver were prepared and stained with haematoxylin and eosin (H&E) before light microscope examination.

Statistical Analysis

Results were expressed as mean ± S.E.M. Statistical analysis was done on SPSS 23. One way ANOVA followed by Post Hoc Tukey Test was

used for multiple comparisons of biochemical markers between the groups. Histopathological results were assessed through Chi Square test. The difference between two observations were considered as significant if the p value was < 0.05.

RESULTS

MTX induced hepatotoxic model was standardized in our laboratory using different doses and time interval before animal sacrifice. A single intraperitoneal injection of MTX in dose of 20 mg/kg followed by sacrifice after 24 hours, produced marked hepatic damage as evident by elevated serum ALT, AST and ALP levels and significant histopathological changes.

EFFECT ON SERUM ALT, AST and ALP

Serum ALT, AST and ALP levels in animals of the Group A and Group B were remained within the normal limits showing no signs of liver damage (Table-I and Figure-1).

In group C (MTX) there was significant rise in serum ALT, AST and ALP as compared to its control Group A (Table-I and Figure-1).

In group D (Silymarin) there was insignificant difference in serum ALT, AST and ALP as compared to its control Group B (Table-I and Figure-1).

In group E (MTX + Silymarin) there was significant attenuation of serum ALT, AST and ALP in when compared with toxic group C (Table-I and Figure-1).

HISTOPATHOLOGICAL ANALYSIS

Microscopic examination of Group A, B and D showed normal hepatic architecture (Figure-2).

Histopathological analysis of liver of Group C that received MTX showed steatosis with focal nuclear pleomorphism (Figure-3). This is statistically significant ($p < 0.05$) when compared with its control group A.

Histopathological analysis of liver of Group E (MTX + Silymarin) showing focal inflammation with the preservation of liver architecture which is statistically significant ($p < 0.05$) when compared with its toxic group C (Figure-4)

Comparative groups	ALT (IU/L)	AST (IU/L)	ALP (IU/L)
Group A (Control with Intraperitoneal Normal Saline)	31.33 ± 3.28	87.83 ± 3.57	94.67 ± 4.91
Group C (MTX)	73.67 ± 3.67	128.50 ± 7.77	315.33 ± 12.44
Between groups p value	0.000*	0.000*	0.000*
Group B (Control with Oral Distilled Water)	32.00 ± 2.03	89.17 ± 3.68	98.50 ± 3.98
Group D (Silymarin)	35.67 ± 1.61	90.33 ± 3.8	100.33 ± 9.33
Between groups p value	0.928	1.000	1.000
Group C (MTX)	73.67 ± 3.67	128.50 ± 7.77	315.33 ± 12.44
Group E (MTX + Silymarin)	49.17 ± 4.66	96.83 ± 3.66	195.17 ± 11.55
Between groups p value	0.000*	0.001*	0.000*

**Table-I. Comparative analysis of serum ALT, AST and ALP of different groups of mice.
p < 0.05 (significant *)**

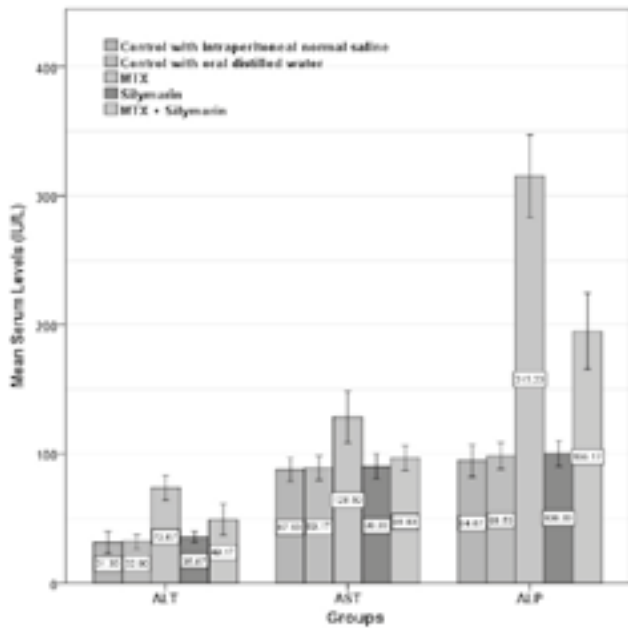


Figure-1. Bar Chart Showing Mean Serum ALT, AST and ALP of All the Groups

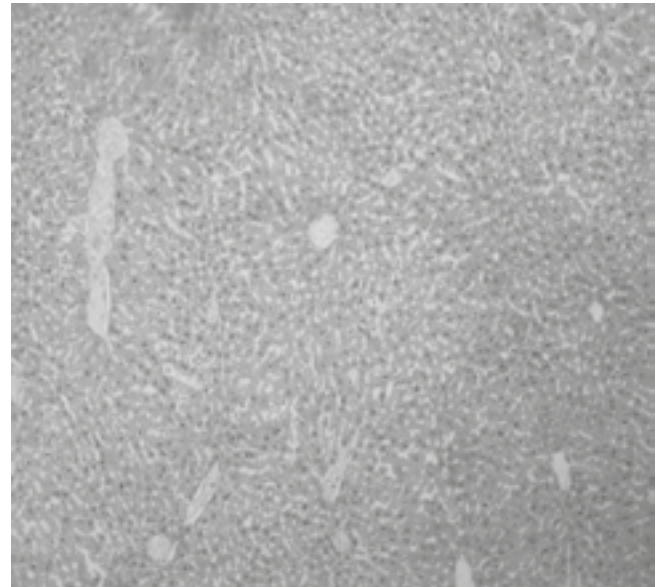


Figure-3. Photomicrograph of the liver tissue in Group C (MTX) showing mild steatosis and focal nuclear pleomorphism (H&E 10X)

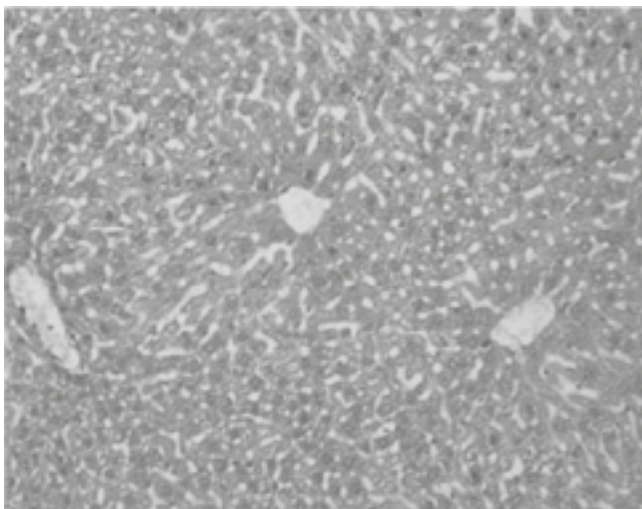


Figure-2. Photomicrograph of the liver tissue in Group A, B, and D showing normal hepatic architecture (H&E 10X)

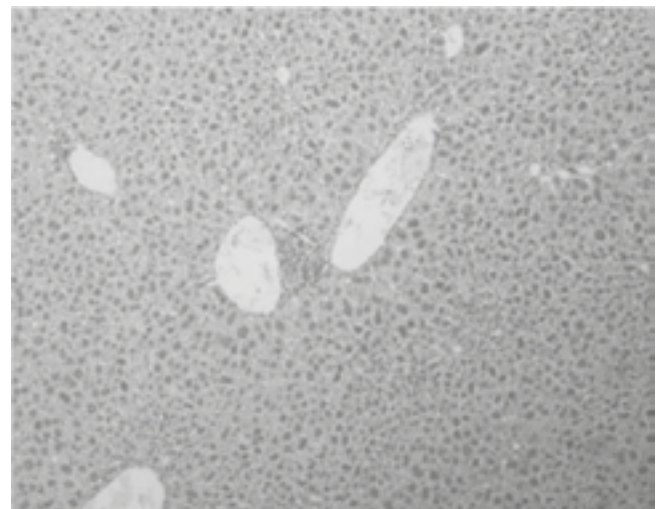


Figure-4. Photomicrograph of the liver tissue in Group E (MTX + Silymarin) showing focal inflammation (H&E 10X)

DISCUSSION

Rheumatoid arthritis is the third most common type of arthritis with the global prevalence of approximately 1 percent.¹⁰ MTX is commonly used DMARD, used in low doses. MTX, though relatively safe in low doses in RA, can cause in myelosuppression, hepatotoxicity, gastrointestinal and mucocutaneous adverse effects.¹¹ The pooled data of 21 studies showed hepatotoxicity on low dose of MTX is the

second common cause (18.5 percent) after gastrointestinal adverse effects resulting in 10 – 37 percent cases of treatment discontinuation.¹²

The results of our study suggests that MTX treatment causes substantial hepatic damage in mice after single intra peritoneal injection. Serum ALT, AST and ALP raised significantly as compared to its control group. ALT is a cytosolic enzyme of liver cells and its raised serum levels

depict distortion in membrane permeability. It is the best marker of hepatic necrosis.⁸ The raised levels of ALP more than that of ALT shows obstructive liver disease though no cholestasis is seen on histopathological analysis. It may be because of the single dose of MTX along with early sample collection. The findings are consistent with the Akbulut et al¹³ and Tag⁸ who also demonstrated elevation of LFTs in experimental rodents treated with MTX in same dose and route of administration. The exact pathogenesis of MTX induced hepatotoxicity is still unclear though different mechanisms are thought to participate in causing liver damage like accumulation of polyglutamates in hepatocytes, depletion of hepatic folate store resulting in decrease nucleic acid synthesis, inhibition of methionine biosynthesis and resultant increased homocysteine leading to increase cellular sensitization to reactive oxygen species (ROS) and reactive nitrogen species (RNS) along with lipid peroxidation of biological membranes and microvascular derangement. High homocysteine levels, in addition to the oxidative stress, can also mediate endoplasmic reticulum (ER) stress which disturbs the metabolism of cholesterol and triglycerides resulting in fatty infiltration of liver.¹⁴⁻¹⁶ MTX also decreases the availability of intracellular NADPH leading to depletion of cellular glutathione making cells more vulnerable to damage by ROS.¹⁷

In current study, silymarin administration with MTX in mice showed hepatoprotective effects which is also depicted by significant attenuation of serum ALT, AST and ALP. The findings are in accordance with the study of Naik et al¹⁸ in which highly significant decrease in the levels of liver enzymes were documented with the administration of these two drugs to experimental rats.

Silymarin is an antioxidant, which suppresses lipid peroxidation of biological membranes by interfering directly with the cell membrane constituents, which is depicted by reduced level of its marker malondialdehyde by silymarin as well.¹⁹ Silymarin stabilizes hepatocyte cell membrane and blocks the entrance of toxins

into the hepatocytes.²⁰ Moreover, Silymarin also regenerate liver by promoting the formation of structural and functional proteins by stimulating DNA dependent RNA polymerase I.²¹ Silymarin scavenges both ROS and RNS by potentiating the activity of various antioxidant enzymes. In addition to this, silymarin also possess anti-proliferative and anti-fibrotic, anti-inflammatory and antiviral properties.²⁰ These may be the mechanisms by which silymarin is effective for protecting MTX induced hepatotoxicity.

CONCLUSION

Our results suggest that single dose of methotrexate (20mg/kg) causes substantial hepatic damage in mice which may be protected by anti-oxidant potential of silymarin. However, further research is necessary to understand the mechanisms by which silymarin prevents liver damage against MTX toxicity.

ACKNOWLEDGEMENT

We are sincerely thankful to Pathology department, Army medical college for their support in running biochemical markers.

Copyright© 15 May, 2017.

REFERENCE


1. Bath RK, Brar NK, Forouhar FA, Wu GY. **A review of methotrexate-associated hepatotoxicity.** Journal of digestive diseases 2014; 15(10): 517-24.
2. Visser K, Van der Heijde D. **Risk and management of liver toxicity during methotrexate treatment in rheumatoid and psoriatic arthritis: a systematic review of the literature.** Clin Exp Rheumatol 2009; 27(6): 1017-25.
3. Romão VC, Lima A, Bernardes M, Canhão H, Fonseca JE. **Three decades of low-dose methotrexate in rheumatoid arthritis: Can we predict toxicity?** Immunologic research 2014; 60(2-3): 289-310.
4. Gazak R, Walterova D, Kren V. **Silybin and silymarin-new and emerging applications in medicine.** Current medicinal chemistry 2007; 14(3): 315-38.
5. Kvasnička F, Biba B, Ševčík R, Voldřich M, Kratka J. **Analysis of the active components of silymarin.** Journal of Chromatography A 2003; 990(1): 239-45.
6. Pradhan S, Girish C. **Hepatoprotective herbal drug, silymarin from experimental pharmacology to**

- clinical medicine.** Indian Journal of Medical Research 2006; 124(5): 491.
7. Saller R, Meier R, Brignoli R. **The use of silymarin in the treatment of liver diseases.** Drugs 2001; 61(14): 2035-63.
 8. Tag HM. **Hepatoprotective effect of mulberry (Morus nigra) leaves extract against methotrexate induced hepatotoxicity in male albino rat.** BMC complementary and alternative medicine 2015; 15(1): 1.
 9. Amat N, Upur H, Blažeković B. **In vivo hepatoprotective activity of the aqueous extract of Artemisia absinthium L. against chemically and immunologically induced liver injuries in mice.** Journal of ethnopharmacology 2010; 131(2): 478-84.
 10. Gibofsky A. **Overview of epidemiology, pathophysiology, and diagnosis of rheumatoid arthritis.** The American journal of managed care 2012; 18(13 Suppl): S295-302.
 11. Albrecht K, M ler-Ladner U. **Side effects and management of side effects of methotrexate in rheumatoid arthritis.** Clinical and Experimental Rheumatology-Incl Supplements 2010; 28(5): S95.
 12. Salliot C, van der Heijde D. **Long term safety of methotrexate monotherapy in rheumatoid arthritis patients: a systematic literature research.** Annals of the rheumatic diseases 2008.
 13. Akbulut S, Elbe H, Eris C, Dogan Z, Toprak G, Otan E, et al. **Cytoprotective effects of amifostine, ascorbic acid and N-acetylcysteine against methotrexate-induced hepatotoxicity in rats.** World journal of gastroenterology: WJG 2014; 20(29): 10158.
 14. Matte C, Stefanello FM, Mackedanz V, Pederzolli CD, Lamers ML, Dutra-Filho CS, et al. **Homocysteine induces oxidative stress, inflammatory infiltration, fibrosis and reduces glycogen/glycoprotein content in liver of rats.** International Journal of Developmental Neuroscience 2009; 27(4): 337-44.
 15. de Carvalho SCR, Muniz MTC, Siqueira MDV, Siqueira ERF, Gomes AV, Silva KA, et al. **Plasmatic higher levels of homocysteine in non-alcoholic fatty liver disease (NAFLD).** Nutrition journal 2013; 12(1): 1.
 16. Dai Y, Zhu J, Meng D, Yu C, Li Y. **Association of homocysteine level with biopsy-proven non-alcoholic fatty liver disease: a meta-analysis.** Journal of clinical biochemistry and nutrition 2016; 58(1): 76.
 17. Paul M, Hemshekhar M, Thushara RM, Sundaram MS, NaveenKumar SK, Naveen S, et al. **Methotrexate promotes platelet apoptosis via JNK-mediated mitochondrial damage: alleviation by N-acetylcysteine and N-acetylcysteine amide.** PloS one 2015; 10(6): e0127558.
 18. Naik M, Chakraborty M, Ahmed R, Hamza S. **Investigation of nephroprotective effect of silymarin against methotrexate and ifosfamide induced toxicity in rats.** International Journal of Pharma Sciences and Research 2015; 6(1): 174-179.
 19. Shaker E, Mahmoud H, Mnaa S. **Silymarin, the antioxidant component and Silybum marianum extracts prevent liver damage.** Food and Chemical Toxicology 2010; 48(3): 803-6.
 20. Vargas-Mendoza N, Madrigal-Santillán E, Morales-González A, Esquivel-Soto J, Esquivel-Chirino C, García-Luna Y, et al. **Hepatoprotective effect of silymarin.** World J Hepatol 2014; 6(3): 144-9.
 21. AliReza G, Hamid N, Ali O, Morteza G, Parviz A. **The effects of milk thistle on hepatic fibrosis due to methotrexate in rat.** Hepatitis monthly 2011; 2011(6, Jun): 464-8.

PREVIOUS RELATED STUDY

Ghulam Abbas Khan Niazi, Abdul Rehman Arshad, Manzar Zakaria, Waqar Ahmed, Irfan Najam Sheen. HEPATOTOXICITY OF ATT (Original) Prof Med Jour 17(3) 444-448 Jul, Aug, Sep 2010.

AUTHORSHIP AND CONTRIBUTION DECLARATION

Sr. #	Author-s Full Name	Contribution to the paper	Author=s Signature
1	Aamna Khokhar	Main researcher & script writer	
2	Aisha Qayyum	Intellectual contribution	
3	Momina Khokhar	Intellectual contribution	