



# OVARIAN VEIN THROMBOSIS; A CASE REPORT

1. FCPS (Gen Surg)  
Department of Surgery,  
Canadian Specialist Hospital,  
Dubai, UAE.

**Correspondence Address:**  
Dr. Muhammad Umar Younis  
Department of Surgery,  
Canadian Specialist Hospital,  
Dubai, UAE.  
umar000@hotmail.com

**Article received on:**  
24/10/2016  
**Accepted for publication:**  
15/05/2017  
**Received after proof reading:**  
08/08/2017

**Muhammad Umar Younis<sup>1</sup>**

**ABSTRACT... Introduction:** Ovarian Vein Thrombosis is a rare presentation in the surgical emergency. It usually is reported in the postpartum period but may present as an acute abdomen in the ER. **Case Presentation:** A 38 years old female presented with a history of Dilation and Curettage 3 days back Presented with severe lower abdominal pain, fever and vomiting. An exploratory laparotomy revealed left ovarian thrombosis with 1L hemorrhagic fluid in the peritoneal cavity. Left oophorectomy was done and anticoagulation started post op. **Conclusion:** OVT poses a diagnostic dilemma for the patient presenting to the emergency with an acute abdomen because prompt diagnosis and treatment are necessary to prevent further complications.

**Key words:** Acute Abdomen, Gynecology, Oophorectomy, Pelvic Inflammatory Disease.

**Article Citation:** Younis MU. Ovarian vein thrombosis; a case report. Professional Med J 2017;24(8):1256-1258. DOI: 10.17957/TPMJ/17.3529

## INTRODUCTION

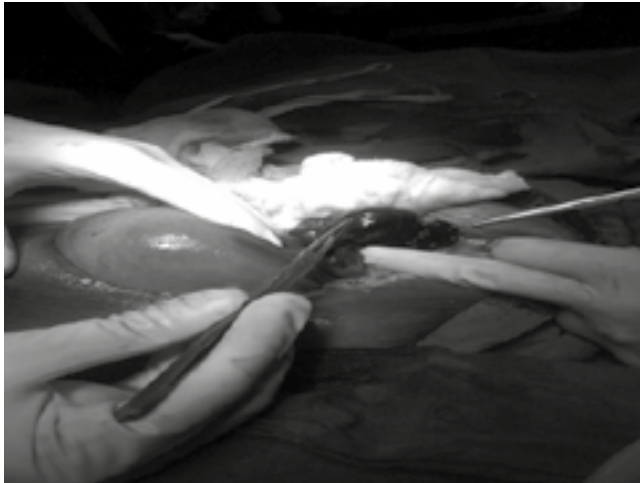
Ovarian Vein Thrombosis (OVT) is an uncommon clinical presentation encountered in medical practice occurring with a frequency of 1/600 to 1/2000 pregnancies mainly during the postpartum period.<sup>1,2</sup> Rarely, it is also associated with pelvic inflammatory disease, gynecological surgery and malignancy.<sup>2</sup> In this report, we would like to describe a case with a rare cause of this obscure condition, that is left sided OVT secondary to Pelvic inflammatory disease that resulted in gangrene of the left ovary.

## CASE

A 38 year old, previously healthy woman presented in the emergency department of Mayo Hospital Lahore Pakistan with a 3 day history of lower abdominal pain, low grade fever, vomiting and foul smelling vaginal discharge. She had no previous history of hypertension, deep venous thrombosis, dyspnea or any hematological disorder but did undergo Dilation and Curettage 3 days back for the removal of an Intrauterine Contraceptive Device which was placed 4 years ago. She gave no history of alcohol, tobacco or drug abuse and there was no predisposition for thrombosis in her family. Physical examination revealed an

anemic and acutely ill woman with a pulse rate of 122/min, blood pressure of 110/70 mmHg and a respiratory rate of 22/min. Abdominal examination revealed a distended, tender lower abdomen with guarding and absent bowel sounds. Pervaginal examination divulged yellow foul smelling discharge. Laboratory evaluation showed aHb of 10.5 g/dl, TLC  $10.4 \times 10^3$ /dland Platelet count of  $75 \times 10^3$ /dl. Other blood panels including renal and hepatic profile came back normal. An emergency abdominopelvic ultrasound demonstrated mild fluid in the hepatorenal pouch and a bulky uterus. A provisional diagnosis of Uterine perforation was made and exploratory laparotomy was planned by a midline incision after adequate resuscitation. CT scan abdomen was not undertaken due to the patient's deteriorating condition and a decision to shift the patient to the operating suite was made with haste. During surgery, 1 liter of hemorrhagic fluid was observed in the peritoneal cavity and the left ovary was found to be gangrenous alongwith thrombosis of the left ovarian vein just below its junction with the left renal vein. A left oophorectomy with ligation and transection of the left ovarian vein was performed and peritoneal lavage carried out. The patient was treated with antibiotics and unfractionated heparin in the post-

operative period and was discharged on the 5<sup>th</sup> day after surgery in good health. Anticoagulation was discontinued at discharge. She remained well up to the 4<sup>th</sup> week after surgery on close clinical follow up.



## DISCUSSION

The frequency for women to suffer from a thromboembolic event increases five times during pregnancy<sup>3</sup> and hence, Ovarian Vein Thrombosis is usually described in relation to a postpartum patient with an incidence of 1:600 to 1:2000 deliveries.<sup>4</sup> It has scarcely been reported in a non-pregnant patient.<sup>5</sup> We have reported here a patient who was not pregnant and had an Intra Uterine Contraceptive Device which was removed only three days before presentation and manifested as a complicated form of OVT leading to gangrene of the involved side.

70-90% of the reported cases have implicated the right ovarian vein<sup>6,7</sup> while our patient had involvement of the left one, which is rarely reported in literature. The right sided predominance has been attributed to the retrograde flow of venous blood down the left ovarian vein and up the right ovarian vein.<sup>8,9</sup> Also, the right vein has a longer course that may result in compression due to dextrorotation of the uterus during pregnancy. 80% of the patients present with a history of fever and 55% present with pain in the right iliac fossa<sup>10</sup> alongwith leukocytosis. Given the non-specific symptomatology of this condition, a high index of suspicion is required to differentiate it

from conditions like acute appendicitis, intestinal volvulus, abscess, pyelonephritis, retroperitoneal lymphadenopathy, adnexal torsion, endometritis and septic pelvic thrombophlebitis. Therefore prompt imaging with the modalities of CT scan, Magnetic Resonance Imaging (MRI) and Doppler Ultrasound should be undertaken which have varying sensitivities at 100%, 92% and 52%, respectively.<sup>11</sup>

A deferment in establishing a diagnosis and initiating necessary treatment can lead to potentially alarming complications including extension of thrombus into the inferior vena cava and renal veins, pulmonary embolism, ovarian infarction and gangrene, multi organ failure, ureteric obstruction and sepsis.<sup>1,12,13</sup> Our patient presented with a complicated form of left ovarian thrombosis in the form of ovarian infarction and gangrene.

As reported in literature, anticoagulation and broad spectrum antibiotics are used in non-complicated cases of OVT but there is still no agreement on the type, dose or duration of treatment.<sup>14</sup> Approach to treatment of extensive degree of thrombus, complications or failure to respond to standard medical therapy would necessitate a more invasive care strategy with surgery and endovascular procedures taking the lead like placement of IVC Filters, hysterectomy and thrombectomy or ligation of IVC.<sup>2,10,14</sup>

## CONCLUSION

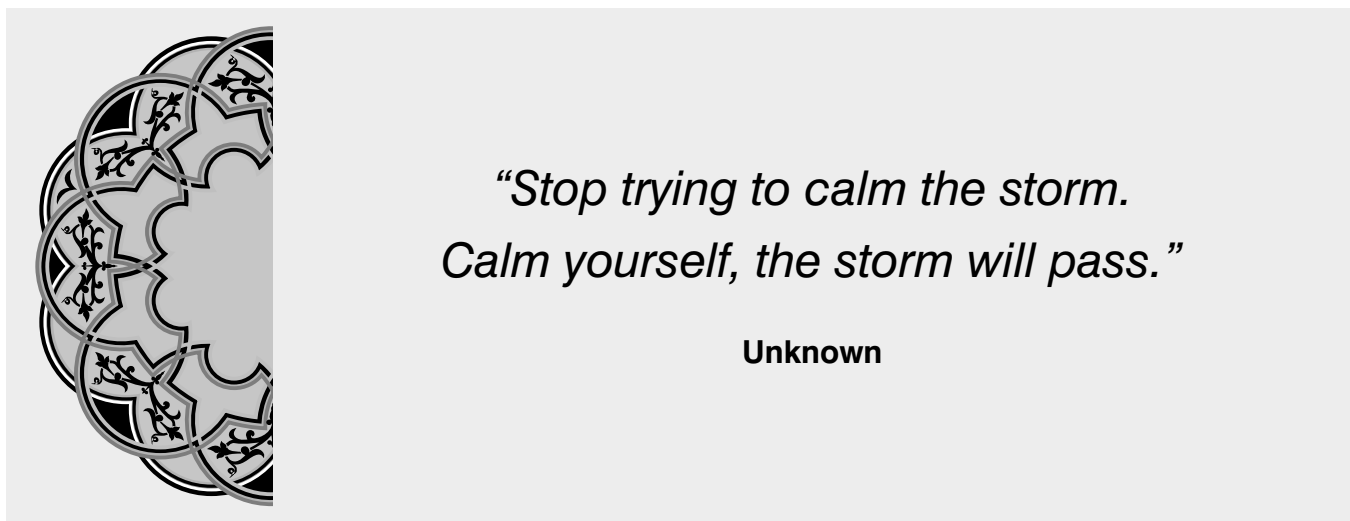
OVT poses a diagnostic dilemma in patients presenting with lower abdominal pain and fever and hence, a lower threshold for its inclusion should be borne in mind while attending to these patients so as to be able to realize this rare entity early in the course of progression and prevent complications that might be life threatening.

Copyright© 15 May, 2017.

## REFERENECES

1. Dunninghoo, D.R., Gallaspy, J.W., Wise, R.B. and Otterson, W.N. (1991) **Postpartum ovarian vein thrombophlebitis: a review.** *ObstetGynecolSurv* 46: 415-427.

2. Ortin, X., Ugarriza, A., Espax, R.M., Boixadera, J., Llorente, A., Escoda, L. et al. **(2005) Postpartum ovarian vein thrombosis.** ThrombHaemost 93: 1004–1005.
3. **Prevention of venous thrombosis and pulmonary embolism.** NIH consensus development, Journal of the American Medical Association, vol. 256, no. 6, p. 744, 1986.
4. Salomon O, Apter S, Shaham D, et al. **Risk factors associated with postpartum ovarian vein thrombosis.** ThrombHaemost 1999;82(3):1015-9.
5. Perquin DA, Warmerdam PE, Yedema CA, Puylaert JB. **Ovarian vein thrombosis.** Ned TijdschrGeneesk 1997; 141(48):2350-3.
6. Prieto-Nieto MI, Perez-Robledo JP, Rodriguez-Montes JA, Garci-San-cho-Martin L: **Acute appendicitis-like symptoms as initial presentation of ovarian vein thrombosis.** Ann VascSurg 2004, 18:481-483.
7. Baran GW, Frisch KM: **Duplex Doppler evaluation of puerperal ovarian vein thrombosis.** Am J Roentgenol 1987, 149:321-322.
8. Munsick RA, Gillanders LA. **A review of the syndrome of puerperal ovarian vein thrombophlebitis.** ObstetGynecolSurv. 1981; 36(2):57-66.
9. Kominiarek MA, Hibbard JU. **Postpartum ovarian vein thrombosis: an update.** ObstetGynecolSurv. 2006; 61(5):337-342.
10. Prieto-Nieto, M.I., Perez-Robledo, J.P., Rodriguez-Montes, J.A. and Garci-Sancho-Martin, L. **(2004) Acute appendicitis-like symptoms as initial presentation of ovarian vein thrombosis.** Ann VascSurg 18: 481–483.
11. Sinha D, Yasmin H, Samra JS: **Postpartum inferior vena cava and ovarian vein thrombosis – a case report and literature review.** J ObstetGynaecol 2005, 25:312-313.
12. Gourlay M, Gutierrez C, Chong A, et al. **Group A streptococcal sepsis and ovarian vein thrombosis after uncomplicated vaginal delivery.** Am Board FamPract 2001; 14(5):375-80.
13. Ghilardi G, Giorgetti PL, Bortolani EM. **Pulmonary embolism secondary to puerperal ovarian vein thrombophlebitis.** Panminerva Med 1991; 33(3):152-6.
14. Al-Toma A, Heggelman BG, Kramer MH: **Postpartum ovarian vein thrombosis: report of a case and review of literature.** Neth J Med 2003, 61:334-336.



**AUTHORSHIP AND CONTRIBUTION DECLARATION**

Sr. #	Author-s Full Name	Contribution to the paper	Author=s Signature
1	Muhammad Umar Younis	Author, Surgeon, Proof read	