



PLASTIBELL CIRCUMCISION; SEVEN YEARS' EXPERIENCE

1. Associate Professor of Surgery
Women Medical College
Abbottabad
2. Associate Professor Orthopedic
Surgery
Women Medical College
Abbottabad
3. Assistant Prof. Medicine

Correspondence Address:
Dr. Syed Ali Akbar
Associated Professor of Surgery
Women Medical College, Abbottabad
draliakbar@hotmail.com

Article received on:

28/03/2015

Accepted for publication:

27/07/2015

Received after proof reading:

12/10/2015

INTRODUCTION

Male circumcision is perhaps one of the oldest surgical procedures known to man. Although exact date and place of commencement of circumcision is not known, but its practice has been traced back up to 15000 years in certain regions of the world.¹

The word circumcision is derived from Latin (circumcido) which means to cut around. It is widely practiced around the world, particularly Muslim and Jews do it as a religion obligation. Technically male circumcision is a procedure in which foreskin is excised from the glans penis.^{2,3,4}

Not very long ago most of the circumcisions were done by barbers in villages and small towns, not only as part of a tradition but also done due to lack of trained medical staff. Even now many people in hospital practice the old method of blind application of bone cutter to foreskin thereby endangering the glans.

Circumcision is now a day's done either by open dissection method or by device method. In open surgery foreskin should be removed by dissecting it away from the glans under vision, edges should

Dr. Syed Ali Akbar¹, Dr. Syed Qasim Mehmood², Dr. Muhammad Safdar Khan³

ABSTRACT... Design: Prospective Study. **Setting:** Different hospitals as a day care surgery. **Period:** March 2005 up to March 2012. **Patients and Methods:** Plastibell circumcision in infants and children's up to the age of 7 years was conducted using Plastibell device in different hospitals as a day care surgery. **Results:** In Plastibell method, local edema was minor complication then delayed separation of the ring, infection, mild bleeding after plastibell separation, respectively and no major complication was noted. **Conclusion:** Plastibell device circumcision prevents the most serious complications like bleeding, infection etc. It is fast and ensures excellent cosmesis and it takes short operating time.

Key words: Plastibell circumcision, Plastibell device, Plastibell method

Article Citation: Akbar SA, Mehmood SQ, Khan MS. Plastibell circumcision; seven year's experience. Professional Med J 2015;22(10):1222-1225. DOI: 10.17957/TPMJ/15.2871

be approximated and closed. In device method the device is placed under the foreskin and then it is removed. In both methods some form of local, general or topical anaesthesia should be given so as to reduce the pain.⁵

Besides religions and cultural demands circumcision is sometimes done on the basis of proven benefits in reducing the risk of urinary tract infections, carcinoma penis, carcinoma cervix, sexually transmitted diseases and HIV infection.^{6,7,8} It is also performed as a treatment option for phimosis and balanoposthitis. However it is relatively contraindicated in congenital abnormality such as hypospadias and bleeding disorders.

MATERIALS AND METHODS

This prospective study was conducted on 100 infants and children from the age 3 months to 7 years of age who were brought by their parents for circumcision in an outpatient clinic, between March 2005 up to March 2012. Children with congenital problems post-operative complicated cases and cases with bleeding disorders were excluded from this study. After proper history examination and investigations like blood CP, HCV, HBC, bleeding and clotting time.

Informed consent was obtained from parents of eligible infants based on entry criteria.

All Infants were operated with Plastibell method. Infants were not fed for 1-2 hours prior to the procedure. After placing an infant on operation table the skin was prepared with povidone iodine (10%) solution. A dorsal nerve block was administered using 0.2 mL/kg of 2% lidocaine, with a 27-gauge needle.

Regardless of the technique, four minutes were allowed to elapse for all infants before beginning of circumcision procedures. In Plastibell technique, a plastic protective bell was placed over the glands and under the foreskin. A suture was placed around the entire foreskin, which would eventually fall off, after necrosis within several days. The parents of subjects were informed to return if the time of bell separation exceeded more than 10 days.

No dressing was applied in Plastibell method, analgesic like paracetamol or brufen, systemic and local antibiotics were given for 5 to 7days.

All children were followed up until the wound was healed, along with observing them for any associated complications like infection, bleeding or hematoma, excess mucosa, bell disposition and delayed falling.

RESULTS

Considering the age and weight of the children, more than 90% had a normal weight.

In Plastibell method, local edema was major complication in 10 cases that is (10%) of the total operated cases that was relieve spontaneously in majority of case except few cases in which brufen was used as anti-inflammatory agent.

Delay separation of the plastibell ring was the 2nd most common complication in 8 cases that is (8%) of the total operated cases and this was due to 40 children’s as their age was 6 to 7years and skin of the foreskin was thick.

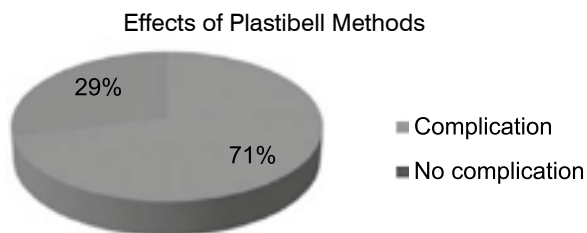


Figure-1. Effect of plastibell Methods

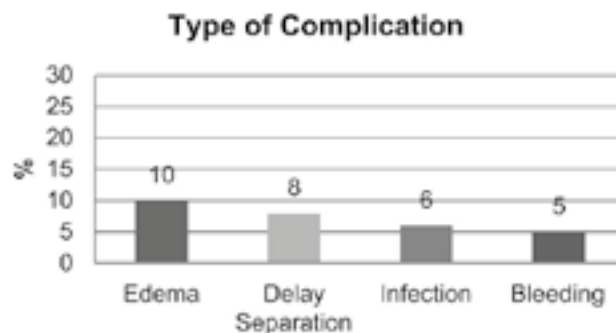


Figure-2. Type of Complication

Infection was 3rd common complication in 6 cases that is (6%) of the total operated cases and that was controlled with systemic and local antibiotic. Mild bleeding was noted in 5 cases after plastibell ring separation that was (5%) of the total operated cases and that was controlled with dressing and systemic antibiotic. In view of above there were 71% cases with no complications 29% of cases with minor complications were noted.

DISCUSSION

Circumcision one of the safe procedure, if the procedure is performed by the well experienced practitioner with the use of proper size of plastibell.^{9,10} The rate of Complications will be high when this procedure will be performed in poorly sterile condition, with poorly experience practitioner and some time when the child age will be more.¹¹ Common complications are bleeding, infection, damage to the glance penis urethra etc.^{12,13,14} Other rare possible complications include skin bridges, urethral fistulas and meatal stenosis etc. The chance for these complications will be less if we adopt proper technique, and most often these complications are treatable without requiring a hospital visit.

There are many techniques for circumcision but in our country most of the medical staff performs the conventional dissection, and plastibell commonly perform by surgeons and urologist in good stander hospital.

A large number of studies proposed that circumcision with using plastibell is easy, safe and quick method with low complications rate.^{15,16} When complications will be occurring they will be of low clinical importance and of easily treatable. These complications including hemorrhage, local infection, sepsis, metal ulceration, and poor cosmetic results are rare. In our study infection was noted in 6 % cases, this percentage is high comparative to the other studies, it was because of the poor hygiene and in some of the patient antibiotics were not give with proper does and duration. Post operative bleeding was noted in 5% cases mild during separation of the ring as some of the rings were not separated spontaneously and they were separated by childrens.8% cases there was delay separation of the ring as there were more than 30 children's with age more than 6 years, this was due to the more thickness of the prepuce skin and there was no case with other associated problem like cosmetic, or hematoma damage to the urethra, edema of the glance penis, retention of urine. For the better results it is necessary that there should be good skill surgeon with correct size of the plastibell accurate ligation of the suture around the plastibell.¹⁷

CONCLUSION

Circumcision using a plastibell device is a safe, quick and easy technique with low complications, that when occur are of low clinical importance and of easy resolution. For the better result it is necessary to operate in aseptic environment, there should be good skill surgeon, with correct size of the plastibell, accurate ligation of the suture with proper antibiotic and analgesic.

Copyright© 27 July, 2015.

REFERENCES

1. TotaroA, VolpeA, **circumcisionhistory, religion and law**, Urologia 2011 Jan-Mar, 78(1); 1-9.
2. Rudolph C, Rudolph A, Lister G, First L, GershonA. **Rudolph's Pediatrics, 22nd Edition**.18 March 2011. p. 188.ISBN 978-0-07-149723-7
3. Sawyer S. **Pediatric Physical Examination & Health Assessment**. November 2011. Jones & Bartlett Publishers. pp. 555–556. ISBN 978-1-4496-7600-1.
4. American Academy of Pediatrics Task Force on Circumcision (2012). “**Technical Report**”. Pediatrics 130 (3): e756–e785. doi:10. 1542/peds. 2012-1990. ISSN 0031-4005. PMID 22926175.
5. Hay W, Levin M. **Current Diagnosis and Treatment Pediatrics 21/E. 25 June 2012**. McGraw Hill Professional. pp. 18–19. ISBN 978-0-07-177971-5.
6. Schoer A. **male circumcision from an infectiological point of view Hautarz**;2015 Jan;66(1);30
7. Zhao Fj1, Lips, **luNQ long term benefits of male circumcision to the reduction of urinary tract infections and genitourinary cancer in china**. Zhonghua Nan ke Xue.2014 Nov.20 (11)969-77.
8. Rennie S¹, Perry B, Corneli A, **C Perceptions of voluntary medical male circumcision among circumcising and non-circumcising communities in Malawi**. Glob Public Health. 2015 May-Jul; 10(5-6):679-91. doi: 10.1080/17441692.2015.1004737. Epub 2015 Jan 29.
9. EA Kidger, N Haider, and A Qazi **Acquired phimosis after plastibell circumcision: a preventable consequence**. Ann R Coll Surg Engl. 2012 Sep; 94(6): e186–e188.
10. Jorge DeMaria, MD, FRCSC,*† Alym Abdulla, MD,* Julia Pemberton, MSc, PhD(c),† Ayman Raees,MD,* and Luis H. Braga, MD, FRCSC*† **Are physicians performing neonatal circumcisions well-trained?** Can Urol Assoc J. 2013 Jul-Aug; 7(7-8): 260–264.
11. Weiss HA, Larke N, Halperin D, Schenker I (2010). “**Complications of circumcision in male neonates, infants and children: a systematic review**”. BMC Urol 10: 2. doi:10.1186/1471-2490-10-2. PMC 2835667. PMID 20158883.
12. Mohammad Aslam, Abdul Majid, Naeem Mumtaz. **Circumcisional injuries A Neglected Negligence**. JPML 2010 Vol 94 No.02;95-100.
13. Muhammad Sajjad, Muhammad Shahab Athar, Naeem Ahmad. **Complications of circumcision with plastybel; are they age related?**. Pak.J.Suerg.2010; 26(1); 41-45.
14. Khalid Mahmood, Zahid Mahmood, Shahbaz Ahmad. **Circumcision Tredin Pakistan**. JUMDC Vol.6,1 january –March 2015.
15. Moosa FA¹, Khan FW, Rao MH. **Comparison of com-**

- plications of circumcision by 'Plastibell device technique' in male neonates and infants.** J Pak Med Assoc. 2010 Aug; 60(8):664-7.
17. Bastos Netto JM¹, Gonçalves de Araújo J Jr, Noronha MF, Passos BR, Lopes HE, Bessa Jd Jr, Figueiredo AA. **A prospective evaluation of plastibell® circumcision in older children.** Int Braz J Urol. 2013 Jul-Aug;39(4):558-64. doi: 10.1590/S1677-5538.IBJU.2013.04.14.
18. Michael I Nnamonu. **Circumcision: Experience at a Private Hospital in Jos, Nigeria.** Niger J Surg. 2013 Jan-Jun; 19(1): 1–3.



“Best way to not get your heart broken, is pretend you don't have one.”

Charlie Sheen



AUTHORSHIP AND CONTRIBUTION DECLARATION

Sr. #	Author-s Full Name	Contribution to the paper	Author=s Signature
1	Dr. Syed Ali Akbar	Operations & collection of cases	
2	Dr. Syed Qasim Mehmood	Research	
3	Muhammad Safdar khan	Research	