

CAESALPINIA DECAPETALA

Hepatoprotective activity of ethanol extract

Dr. Muhammad Kashif Baig, Dr. Iram Irshad, Dr. Faiza Naseer.

ABSTRACT.....Members of genus *Caesalpinia* are found world widely in tropical and temperate areas. *Caesalpinia* species have various pharmacological actions that include antidiabetic, antiulcer, anticancer, anti-inflammatory, antimicrobial and antirheumatic. **Objectives:** To assess the Hepatoprotective activity of ethanol extract of *Caesalpinia decapetala*. **Duration of study:** September 2012 to November 2012. **Setting:** Pharmacology and Pathology departments of Independent medical college and animal House of university of agriculture, Faisalabad. Study design: Experimental study. **Materials and Methods:** Hepatoprotective activity was determined by measuring the liver marker enzymes like Bilirubin, AST, ALT and ALK levels and then hepatic biopsy to see any structural changes. Phytochemical analysis of plant extract indicates that it contains polyphenols and flavonoids that possess antioxidant potential and hence possess Hepatoprotective activity. **Results:** Liver enzyme levels were significantly raised in rabbits receiving paracetamol and the enzyme levels were significantly reduced in rabbits who were receiving *Caesalpinia Decapetala* and paracetamol comparable to silymarin and Paracetamol. Results observation was done in concentration and dose dependent manner. Histopathological studies indicated centrilobular and focal necrosis and ballooning in liver of rabbits treated with paracetamol. It showed only mild steatosis with sinusoidal dilatation and binucleate cells in groups receiving *Caesalpinia decapetala*. **Conclusions:** It is concluded that *Caesalpinia decapetala* possesses significant Hepatoprotective activity.

Key words: *Caesalpinia decapetala*, Hepatoprotective activity, Antioxidant activity.

Article Citation

Baig MK, Irshad I, Naseer F. *Caesalpinia Decapetala*; Hepatoprotective activity of ethanol extract. Professional Med J 2013;20(3): 078-084.

INTRODUCTION

Members of genus *Caesalpinia* are found world widely in tropical and temperate areas¹. *Caesalpinia* species have various pharmacological actions that may include antidiabetic, antiulcer, anticancer, anti-inflammatory, antimicrobial and antirheumatic². A thorny climber or shrub, *Caesalpinia decapetala* is about 25 m in height having bright yellow flowers. In Indian traditional medicines the decoction of plant is used to cure jaundice, leaves are used to treat burns, biliousness and stomach disorders³. It is also used as laxative, tonic, carminative and antipyretic⁴. Leaves and root of *Caesalpinia decapetala* act as a purgative and emmenagogue⁵.

Caesalpinia decapetala (family: *Caesalpinaceae*) commonly called as Kanderi or urian is found on Margallah Hills national park in Pakistan⁶. It has been used as an immunomodulatory and anti-inflammatory agent in traditional Vietnamese medicine⁷. Its methanolic extract has been proved to possess

antioxidant potential⁸.

Phytochemical analysis indicated the isolation of seven compounds such as lupeol acetate (I)lupeol, (II)oleanic acid, (III)pentacosanoic acid 2,3-dihydroxypropyl ester, (IV)1-(26-hydroxyhexacosanoyl)-glycerol, (V)stigmasterol, (VI)beta-sitosterol, (VI)from *Caesalpinia decapetala*⁹. A previous investigation of the roots of *C. decapetala* have isolated caesalpinin, betulinic acid, 3-deoxysappanchalcone, sappanchalcone, catechin, methyl gallate, and 3-hydroxy-1-(4-hydroxy-3-methoxyphenyl)-1 propanone¹⁰. Cassane diterpenoid, caesaldecane, spathulenol, 4, 5-epoxy-8⁹ caryophyllene, squalene, lupeol, trans-resveratrol, quercetin, astragalol, and stigmasterol¹¹ from the leaves of *C. decapetala*¹².

As reactive oxygen species are involved in the pathophysiology of various diseases such as inflammation, autoimmune problems, viral infections,

digestive tract ailments, neurodegenerative disorders and gastric ulcer¹³. Drugs that possess antioxidant properties have role in reducing tissue injury¹⁴. Many indigenous drugs are known to possess significant free radical scavenging properties^{15,16,17}. This caesalpinia decapetala also possess antioxidant potential that points towards its role as Hepatoprotective agent.

EXPERIMENTAL ANIMALS

Study was conducted on rabbits. Male rabbits weighing 1.2-1.5 kg were obtained from local laboratories of faisalabad Pakistan, were used. The animals were housed in animal house of Department of pharmacology agriculture university Faisalabad. Animals were kept under controlled conditions of Temperature ($25 \pm 1^\circ\text{C}$) and humidity ($50 \pm 5^\circ\text{C}$). They were given standard diet and water add libitum. Animals were acclimitized to environment for one week prior to experimentation¹⁸.

CHEMICALS

Ethanol (Analytical grade), Distill Water, Paracetamol, Silymarin, Pentothal sodium.

INSTRUMENTS USED

Rotary Evaporator, filter paper, Muslin Cloth, Diagnostic Kits.

EXTRACTION OF PLANT MATERIAL

Whole plant was washed, dried and grinding was done. 3000 gm of plant material was soaked in 9 L of ethanol for approximately 15-20 days. Frequent shaking and filtration was done. The residue left was again extracted under same conditions. The semisolid residue of both extracts were combined and evaporated to dryness at 78°C using rotary evaporator¹⁹.

PARACETAMOL INDUCED HEPATOTOXICITY AND EXTRACT TREATMENT

Thirty healthy rabbits were used in the study. Rabbits

will be divided in 6 groups; each will be having 5 rabbits. The dose administration was continued for 7 days¹⁸.

Group-I will receive distill water daily for seven days. Group-II will receive Paracetamol at the oral dose of 2000mg/kg daily for seven days. Group-III will receive oral Silymarin 100mg/kg daily for seven days. Group-IV will receive ethanol extract of Caesalpinia decapetala at the oral dose of 150mg /kg daily for seven days. Group -V will receive ethanol extract of Caesalpinia decapetala at the oral dose of 300mg/kg daily for seven days. Group-VI will receive ethanol extract of Caesalpinia decapetala at the oral dose of 500mg /kg daily for seven days. Paracetamol at toxic oral dose of 2000 mg/kg was given to Group-III to group-VI on seventh day, one hour after extract administration.

ASSESSMENT OF LIVER FUNCTIONS

Biochemical Estimation

Merck diagnostic kits and UV-VIS Spectrophotometer were used to measure serum glutamate oxaloacetate transaminase (SGOT), serum glutamate pyruvate transaminase (SGPT), serum alkaline phosphatase (ALP) and Bilirubin (B) levels under the supervision of pathologist.

HISTOPATHOLOGICAL STUDY

Liver tissues were dissected and washing was done by using normal saline and were fixed with 10% neutral-buffered formalin for 48 hour. The specimens were grossed by pathologist and representative sections were taken and dehydrated with graded ethanol (50-100%). These were further embedded in paraffin wax. 5-6 mm thick sections were prepared on microtome. Hematoxylin and eosin dye are used for microscopic evaluation by the pathologist.

Following grades were used for scoring liver sections²⁰:

0= Normal Liver.

1= small septa of connective tissue without effecting the structure of hepatic lobules.

2= Large septa of connective tissues having penetration into the parenchyma and can develop nodules.

3= Development of nodules and loss of hepatic lobules in liver structure.

4= Formation and deposition of connective tissue with lobules and formation of scars.

STATISTICAL ANALYSIS

One way ANOVAs was applied to the data and the results were presented as Mean \pm Standard error of means (S.E.M).

RESULTS

Groups	SGOT/AST (14-113 IU/L)	SGPT/AST (12-67 IU/L)	ALK (17-192 IU/L)	Bilirubin (0.2-0.7 mg/dl)	Liver damage grade
Control 5ml/kg Normal saline	66.83 \pm 8.39	70 \pm 4.64	117.33 \pm 5.33	0.75 \pm 0.05	0
Paracetamol control 2000mg/kg + Distill H2O	123 \pm 7.76	191.66 \pm 22.39	223.33 \pm 7.70	3.4 \pm 0.16	+3
Silymarin Control 100mg/kg + Paracetamol 2000mg/kg	74.66 \pm 8.11	71.33 \pm 8.03	133.5 \pm 9.93	0.7 \pm 0.05	+1
Caesalpinia Decapetala Extract (150mg/kg) + Paracetamol 2000mg/kg	98.16 \pm 6.73	97.33 \pm 8.74	145 \pm 24.15	1.88 \pm 0.16	+1
Caesalpinia Decapetala Extract (300mg/kg) + Paracetamol 2000mg/kg	90 \pm 5.82	86.5 \pm 4.93	141.66 \pm 17.63	1.45 \pm 0.15	+1
Caesalpinia Decapetala Extract (500mg/kg) + Paracetamol 2000mg/kg	78.16 \pm 7.16	78.5 \pm 4.57	139.5 \pm 11.88	1.2 \pm 0.12	+1

Effect of ethanolic extract of caesalpinia decapetala on liver marker enzymes

Table shows that ALT, AST and ALK and bilirubin levels were significantly raised in animals receiving paracetamol and the enzyme levels were significantly reduced in rabbit groups who were receiving silymarin + Paracetamol and Caesalpinia Decapetala + paracetamol. While by increasing the dose of extract, there was a significant fall in enzyme level ($P < 0.05$). Histopathological studies indicated centrilobular and

focal necrosis and Ballooning in liver of rabbits treated with Paracetamol. It showed only mild steatosis with sinusoidal dilatation and binucleate cells in groups receiving extract at dose of 150 mg/kg and 300 mg/kg. While binucleate cells and slight fatty changes were observed in liver treated with 500mg/kg of extract. The liver treated with silymarin appeared to be same as normal.

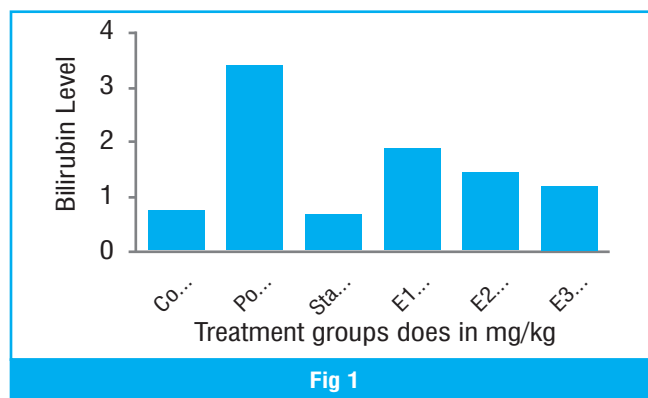


Fig 1

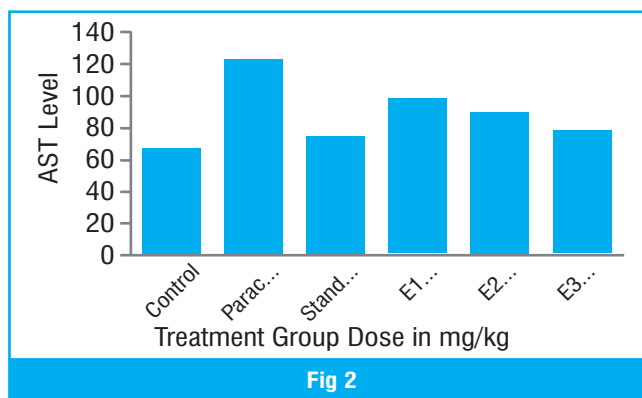
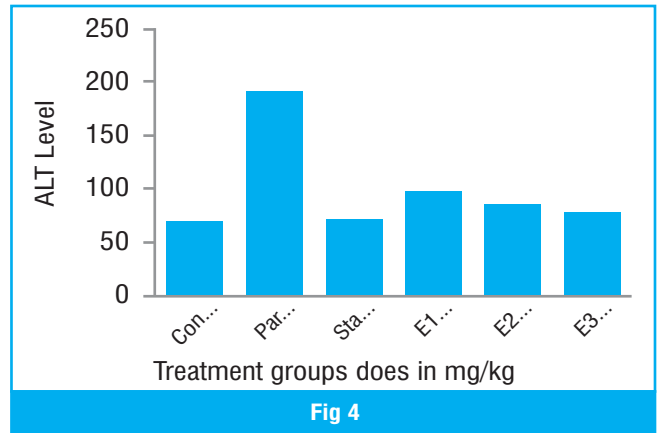
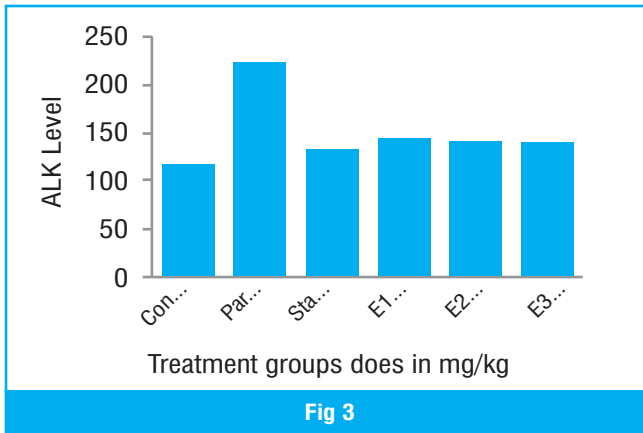


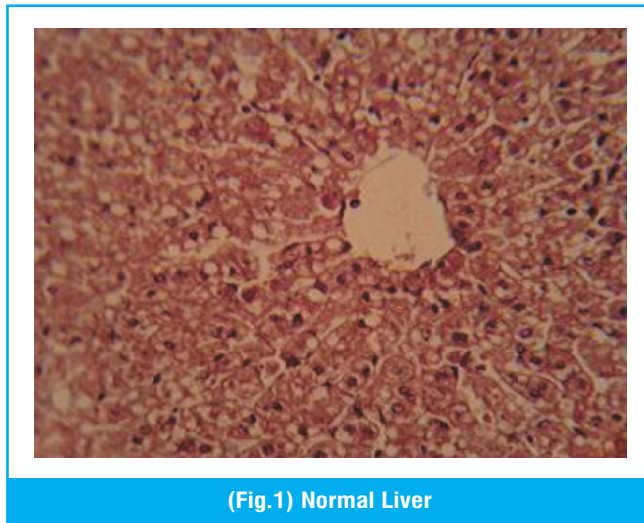
Fig 2

Effect of Ethanolic Extracts of Caesalpinia decapetala on Bilirubin (Fig 1) and AST Levels (Fig 2)

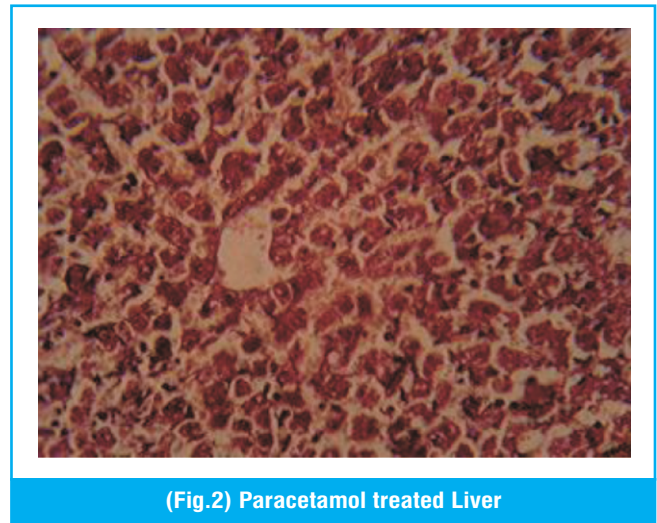


Effect of ethanolic extracts of caesalpinia decapetala on ALK (Fig 3) and ALT levels (Fig 4)

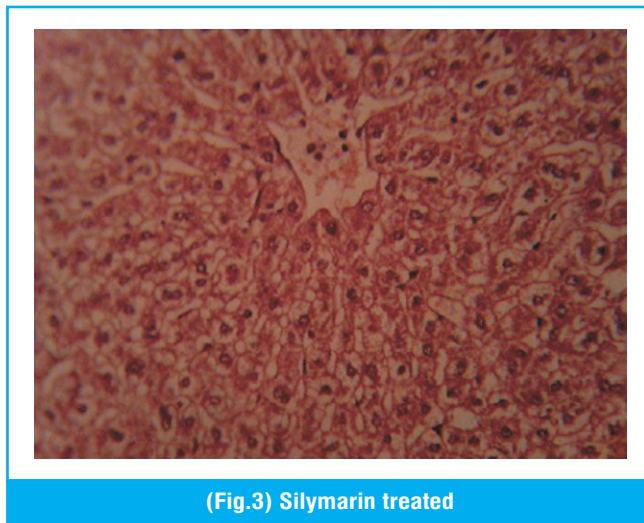
HISTOPATHOLOGICAL STUDY



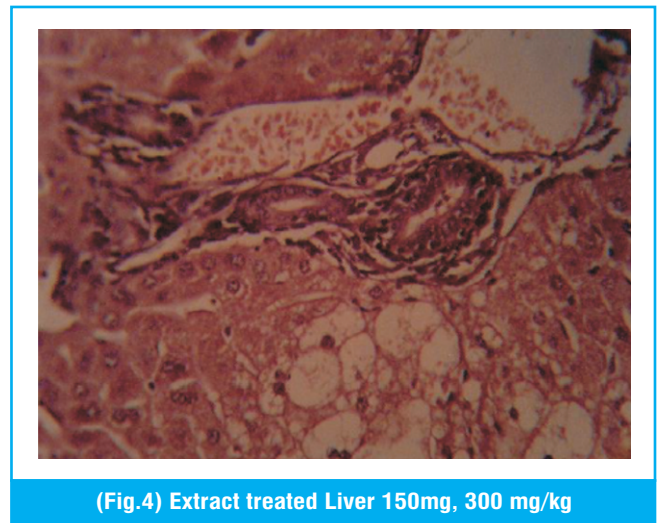
(Fig.1) Normal Liver



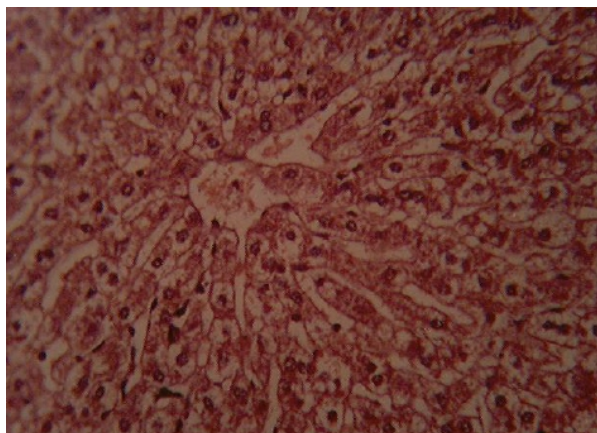
(Fig.2) Paracetamol treated Liver



(Fig.3) Silymarin treated



(Fig.4) Extract treated Liver 150mg, 300 mg/kg



(Fig.5) Extract treated Liver at the dose of 500 mg/kg

DISCUSSION

Liver plays role in many metabolic processes and is exposed to many toxic chemicals which can damage liver. Paracetamol induced liver injury involves direct mitochondrial function impairment that ultimately lead to Liver cell damage²¹. After metabolism, Paracetamol is converted to N-acetyl Pbenzoquinineimine, it will lead to development of oxidation stress that will cause glycogen and glutathione depletion by irreversible conjugation with sulfhydryl groups of glutathione²² and liver cell necrosis²³. As a result of this damage there is increase in liver enzymes; ALT, AST, ALP and bilirubin and hence measurement of these elevated levels can be used to measure histostructural integrity of hepatocytes^{24,25,26}. Hydroxyl radicals, hydrogen peroxides, single oxygen, nitric oxide, lipid oxide and superoxide anions are highly reactive species produced inside the body by various external and internal factors^{27,28,29}. These radicals can lead to the many diseases like cancer, hepatic problems, inflammation and many other abnormalities³⁰. Free radicals make covalent bonds with macromolecules of membranes of many organelles and induce lipid peroxidation and lipid peroxides are generated that will lead to membrane damage³¹. Degree of jaundice is reflected by increased level of bilirubin, Transaminases and alkaline phosphatases^{32,33}. Whenever there will be liver damage with

hepatocellular lesions and parenchymal cells necrosis, these enzymes will be released into blood stream from the damaged tissues³⁴.

In this study, liver marker enzymes levels were found to be increased in hepatotoxic animals and significant reduction was observed in rabbits receiving ethanolic extract of *Caesalpinia decapetala* as compared to that of toxicant rabbits. This Hepatoprotective effect was more pronounced with extract dose of 500mg/kg. A possible mechanism may be antioxidant effect or inhibition of cytochrome P-450³⁵. Histopathological examination of the liver sections of rabbits treated with paracetamol showed necrosis and vacuolization while the liver sections of rabbits treated with silymarin and extracts along with paracetamol toxic dose showed protective effect against paracetamol toxicant and is evident by absence of necrosis.

CONCLUSIONS

Hepatoprotective activity of ethanolic extract of *Caesalpinia decapetala* extract (150, 300, 500 mg/kg doses) was studied. There was significant reduction in serum enzyme levels like AST, ALT, ALP and bilirubin which are comparable to that of silymarin. This confirms the protective effect of ethanolic extract of *caesalpinia decapetala* against paracetamol induced liver damage. Histopathological examination of liver sections of all the treated groups also supported the evidence. Thus it is concluded that the ethanolic extract of *Caesalpinia decapetala* possess significant dose dependent Hepatoprotective activity. This study opens gateway to develop advance research on hepatoprotective drugs.

Copyright© 03 Mar, 2013.

REFERENCES

1. Zheng,H.,Wu,Y.,Ding, J.,Binion,D., Fu, W., Reardon,R., Invasive Plants of Asian Origin Established in the US and Their Natural Enemies. 2004.
2. João, L., Baldim, Z. , Bianca, A., Carvalho, D., Martineli, S. P., Santos, D. H. M., João H.G., Lago, Patricia, S. ,

- Cláudio,Viegas Jr., and Marisi,G.S., **The Genus *Caesalpinia* L. (Caesalpinaceae): Phytochemical and Pharmacological Characteristics.** *Molecules*, 2012. 17(7), 7887-7902.
3. Bhadoriya, U., Sharma, P., Solanki, S. S., **In Vitro Free Radical Scavenging Activity of Gallic Acid Isolated From *Caesalpinia Decapetala* Wood**, 2012.
 4. Guha, B. D.N., Sensarma P., Pal D.C., **A *Lexicon of Medicinal Plants in India.*** Naya Prokash Publisher, Calcutta, 1999.1:336.
 5. Kiem,V.P., Minh,V. C., Huong, T. H., Lee, J. J., and Kim, H. Y., ***Caesaldecan, a Cassane Diterpenoid from the Leaves of *Caesalpinia decapetala.**** *Chem. Pharm. Bull*, 2005. 53(4) 428—430.
 6. Jabeen, A., Khan, A. M., Ahmad, M., Zafar, M., and Ahmad, F., ***Indigenous uses of economically important flora of Margallah Hills National Park, Islamabad, Pakistan.*** *African Journal of Biotechnology*, 2009. 8 (5), pp. 763-784
 7. Chi V. V., ***Vietnamese Medical Plant Dictionary.*** Ha Noi Medicine Pub., Ha Noi, 1997.
 8. Pawar,CR.,andSurana, S.J., ***Antioxidant Properties of the Methanol Extract of the Wood and Pericarp of *Caesalpinia decapetala.**** *J Young Pharm*, 2010. 2(1):45-49
 9. Li, M., Zhang, C., Chong, L., ***Studies on chemical constituents of *Caesalpinia decapetala* (Roth) Alston.*** *Zhong Yao Cai.*, 2002. 25(11):794-5.
 10. Ogawa, K., Aoki, I., Sashida, Y., *Phytochemistry*, 31, 2897—2898 (1992).
 11. Barrero, A. F., Molina,J., Oltra, J.E., Altarejos, J., Barragan, A., Lara, A., Segura, M., *Tetrahedron*,1995. 51, 3813—3822.
 12. Kiem,V.P., Minh,V. C., Huong, T. H., Lee, J. J., and Kim, H. Y., ***Caesaldecan, a Cassane Diterpenoid from the Leaves of *Caesalpinia decapetala.**** *Chem. Pharm. Bull*, 2005. 53(4) 428—430.
 13. Anna, F., Dae-Ok, K., Sang-Jin, C., Sung,I. K., Ock, K. Chun., ***Comparison of ABTS/DPPH assays to measure antioxidant capacity in popular antioxidant-rich US foods,*** *Journal of Food Composition and Analysis*, 2011.): 1043–1048.
 14. Khan, A. R., Khan, R. M., Sumaira, S., and Mushtaq, A.,<http://journal.chemistrycentral.com/content/6/1/12> /- ins1 ***Evaluation of phenolic contents and antioxidant activity of various solvent extracts of *Sonchus asper* (L.)***, *Hill. Chemistry Central Journal*, 2012. 6:12.
 15. Alpinar, K., Ozyurek, M., Kolak, U., Guclu, K., Aras, C., Altun, M., Celik, SE., Berker, KI., Bektasoglu B., Apak R: ***Antioxidant capacities of some food plants wildly grown in ayvalik of Turkey***, *Food Sci Tech Res*, 2009. 15: 59-64.
 16. Kadry, H., Basha, I. A., and Temraz, A., ***Antioxidant activity of aerial parts of *Tribulus alatus* in rats***, *Pak. J. Pharm. Sci*, 2010. 23 (1): 59-62.
 17. Nasir, R., Komal, R., Muhammad, Z., Tahsin, G., Iftikhar, H. B., Mazhar, A. G., Adeela A., ***Antioxidant activity of various extracts and organic fractions of *Ziziphus jujube****, *International Journal of Phytomedicine*, 2011. 3 (3): 147.
 18. Yasmin, S., Kashmiri, A. M., Anwar, K., ***Screening of aerial parts of *Abutilon bidentatum* for hepatoprotective activity in rabbits.*** *Journal of Medicinal Plants Research*, 2011. 5(3):349-353.
 19. Ahmad, M., And Eram, S., ***Hepatoprotective Studies On *Haloxylon Salicornicum:* A Plant From Cholistan Desert.*** *Pak. J. Pharm. Sci.*, 2011. 24(3):377-382.
 20. Ranawat, L., Bhatt, J., Patel, J., ***Hepatoprotective activity of ethanolic extracts of bark of *Zanthoxylum armatum*DC in CCl4induced hepatic damage in rats.*** *Journal of Ethnopharmacology*, 2010.127(3): 777–780.
 21. Nazareth, WM., Sethi, JK., and Mclean (1991) ***AE : Effect of Paracetamol on Mitochondrial Membrane Function in Rat Liver Slices.*** *Biochem. Pharmacol*, 1991. 42: 931-936.
 22. Mayuren, C., Reddy, VV., Priya, SVP., Devi, VA., ***Protective effect of Livactine against CCl4 and paracetamol induced hepatotoxicity in adult Wistar rats.*** *North Am J Med Sci*, 2010. 2: 491-495.

23. Hong, RW., Rounds, JD., Helton, WS., Robinson, MK., and Wilmore, DW., **Glutathione Preserves Liver Glutathione After Lethal Hepatic Injury.** Ann. Surg ,1992. 215:114-119.
24. Oyagbemi, AA., and Odetola, AA., **Hepatoprotective Effects of Ethanolic Extract of Onidoscolus Aconitifolius on Paracetamol Induced Hepatic Damage in Rats.** Pak. J. Biol. Sciences,2010.13:164-169
25. Shukla, A. S., Jadon, M., Bhadauria, and Sharma, A., **Prevention of acute CCl4 induced hepatic and renal toxicity in rats by PHF: apropiety herbal formulation.** Int. J. Pharmacol, 2007.1: 71–80.
26. Lynch, T., and Price, A., **The effect of cytochrome P450 metabolism on drug response, inter- actions, and adverse effects.** Am. Fam. Physician, 2007. 76: 391–396.
27. Beris, H., **Drugs Antioxidant effects, a basis of drug selection.** 1991;569.
28. Yerra, R., Senthil, GP., Gupta, M., & Mazumder, Uk., **Studies on in vitro antioxidant activities of methanol extract of Mucuna pruriens (Fabaceae) seeds.** Eur Bull Drug Res , 2005.13: 31.
29. Murray, RK, Granner, DK, Mayes, PA., & Rodwell, V. W., in Harper's biochemistry (New York, McGraw-Hill) 2000.
30. Malila, N., Virtamo, J., Virtanen, M., Pietinen, P., Albanes, D., and Teppo, L., **Dietary and serum alpha-tocopherol, beta-carotene and retinol and risk for colorectal cancer in male smokers.** Eur J Clin Nut, 2002. 56:615.
31. Mujeep, M., Aeri, V., Bagri, P., et al. **Hepatoprotective activity of methanolic extract of Tylophora indica leaves.** IJ Green Pharmacy,2009. 125-127.
32. Saraswat, B., Visen, P. K., Patnaik, G. K., et al. **Anticholestic effect of picroliv, active hepatoprotective principle of Picrorhiza kurroa against carbon tetrachloride induced cholestatis.** Indian J Exp Biol,1993. 31:316-8.
33. Sallie, R., Tredger, J. M., William, R., **Drugs and the liver. Part I. Testing liver function.** Biopharm Drug Disp,1991.12:251-259.
34. Chaudhari, B. P., Chaware, V.J., Joshi, Y. R., et al. **Hepatoprotective activity of Hydroalcoholic extract of Momordica charantia Linn. leaves against Carbon tetrachloride induced Hepatopathy in Rats.** I J ChemTech Res,2009. (2):355-358.
35. Recknagel, R.O., Glende, E.A., Dolak, J. A., et al. **Mechanisms of carbon tetrachloride toxicity.** Pharmacol Ther,1989. 43:139-154.

AUTHOR(S):

1. DR. MUHAMMAD KASHIF BAIG
2. DR. IRAM IRSHAD
3. DR. FAIZA NASEER

Correspondence Address:

Dr. Muhammad Kashif Baig
baigs23@hotmail.com

Article received on: 17/12/2012
Accepted for Publication: 03/03/2013
Received after proof reading: 15/03/2013