



CASE REPORT

A unique case of laproscopic port site tuberculosis.

Muhammad Tahir Ghani¹, Afsar Ali², Nain Sukh³

Article Citation: Ghani MT, Ali A, Sukh N. A unique case of laproscopic port site tuberculosis. Professional Med J 2023; 30(11):1506-1509. <https://doi.org/10.29309/TPMJ/2023.30.11.7778>

ABSTRACT... We report a case of 27 years old lady who presented after 04 weeks of laproscopic cholecystectomy, with purulent discharge from 03 port sites most likely due to improper sterilization of re-usable laproscopic instruments. Patient was initially managed conservatively by repeated incision and drainage and multiple antibiotics including second line drugs against atypical mycobacterium were prescribed but infection did not settle. Her routine bacterial cultures and acid fast bacillus (AFB) stains were negative. After 07 months patient started developing abscesses in surrounding primary port sites and it was finally decided to excise the discharging sinus tracts and sent for histopathology. Histopathology confirmed tuberculosis as it showed epithelioid granulomas. Patient was started with standard first line anti tuberculous treatment (ATT) to eradicate the disease and she became alright after 06 months of ATT.

Key words: Atypical Mycobacterium, Antituberculous Treatment, Epithelioid Granulomas, Laproscopic Cholecystectomy.

INTRODUCTION

Laproscopic port site infections are not uncommon occurrence but are usually mild and easily treatable complication following laproscopic surgeries.¹ In poor resource, under developed countries where all laproscopic instruments are re used after chemical sterilization, port site infection by non-tuberculous mycobacterium is reported.^{2,3,4} Such non tuberculous mycobacterial port site infections present with discharging sinuses and are usually treated by second line anti tuberculous therapy with or without surgical excision of sinus tracts.⁴

We present a case of laproscopic port site tuberculosis resistant to various second line anti tuberculous drugs and treated by surgical excision of sinus tracts and standard first line anti tuberculous therapy after histopathological confirmation of tuberculosis.

Case Summary

A 27 year old female underwent uneventful

standard four port laproscopic cholecystectomy due to cholelithiasis. Ten days after surgery patient presented for stich removal when minimal discharge from umbilical wound was noticed. Skin stiches were removed and patient was advised to have daily dressings and tab Augumentin 625 mg three times a day for 5 days prescribed. 03 weeks later patient presented with painful nodular swellings in epigastric, right hypochondrium and right lumbar ports while umbilical wound did not heal as well. Patient had no fever and white cell count was normal. Patient was diagnosed to have subcutaneous abscesses and incision and drainage done of all three port sites under local anesthesia. Frank pus was drained and sent for culture and sensitivity which later showed no growth. Patient was advised to have daily dressings with saline till wounds were healed. Patient was followed up regularly for next 04 weeks and all four ports showed signs of healing by secondary intention and closed in four weeks time. Patient again presented after 2 weeks with pus discharge from epigastric, right

1. FCPS (Surgery), Consultant and HOD Surgery, City Hospital The Mall Road Wahcantt.
2. MCPS, Pulmonologist Pulmonology, City Hospital The Mall Road Wahcantt.
3. FCPS (Surgery), Senior Registrar Surgery, Hi-tech Medical College, Taxila.

Correspondence Address:

Dr. Muhammad Tahir Ghani
Department of Surgery
City Hospital The Mall Road Wahcantt.
doctortahir226@gmail.com

Article received on: 03/07/2023
Accepted for publication: 06/09/2023

hypochondrium and right lumbar ports while umbilical port was healed. Suspecting atypical mycobacterial infection tab clarithromycin, inj. amikacin prescribed in weight adjusted doses for next 08 weeks. Daily dressings were advised and routine bacterial cultures, atypical mycobacterium cultures and acid fast bacillus (AFB) stains sent. Medical advice from infectious disease and TB specialist taken. Antibiotics and daily dressings continued but wounds only partially healed and continued to discharge minimally. Routine cultures and AFB stains were negative but we could not get cultures for atypical mycobacteria due to lack of facility. Daily dressings and antibiotics continued for 08 weeks afterwards but patient continued to discharge minimally from 3 port sites and no relief was observed. Antibiotics were changed as well and other second line ATT drugs including ciprofloxacin, moxifloxacin, levofloxacin and linezolid were prescribed but all proved unsuccessful in settling the infection. Patient lost to follow up after wards and 07 months after surgery presented with tender nodular swelling approximately 2 cm away from right hypochondrium port, and off and on minimal discharge from epigastric and right lumbar ports. Her ultrasound showed a fluid filled tract extending from primary right hypochondrium port site. After failure of conservative treatment for 07 months it was decided to explore and excise the tracts as it had started spreading in subcutaneous planes around primary port sites. Under general anesthesia all three tracts were excised deeply till rectus sheath and sent for histopathology and wounds were closed primarily. Histopathology reports confirmed tuberculous and patient was started on standard first line ATT. Wounds started showing signs of healing and stiches removed after 2 weeks. ATT continued 06 months and patient got alright.

DISCUSSION

Laparoscopic port site infection by atypical mycobacterium is very rarely reported and is difficult to treat. Patient presents with chronic pus discharge from port site which gradually becomes thin serous or clear fluid and healing is never complete and permanent.^{3,4} If left untreated multiple sinuses develop in surrounding skin and

soft tissues. Any patient presenting with chronic pus discharge from laparoscopic port sites with negative routine bacterial cultures should rise suspicion of infection by atypical mycobacterium. Acid Fast Bacilli (AFB) stains and AFB culture on Lowenstein-Jensen (LJ) medium should be sought. Niyas VKM⁴ in his case report isolated Mycobacterium senegalense as the culprit organism. Yadav RP⁵ in his study found Mycobacterium chelone in cultures of patients with chronic laparoscopic port site infections. Commonly used drugs are clarithromycin, amikacin, levofloxacin, tobramycin, ciprofloxacin and rifampicin for 06 to 08 weeks.^{3,4,5} We found in our case report that the patient was resistant to many second line drugs including clarithromycin, amikacin and levofloxacin and rather responded to standard first line antituberculous drugs. Unfortunately cultures for mycobacterium are not widely available in underdeveloped countries as happened in our case, or may be negative for any growth. We had to opt for surgical excision of sinus tracks after failed conservative treatment as the sinuses started spreading in surrounding subcutaneous tissue (Figure-1).

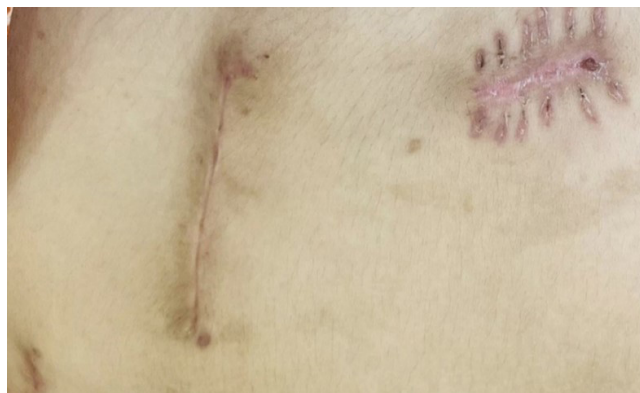

Figure-1

The histopathology of sinus tracks confirmed tuberculous as it showed epithelioid granulomas as shown in Figure-2.

Rehman IU⁶ in his case report also diagnosed port site tuberculosis by histopathology of sinus tract. If cultures for mycobacterium are not available histopathology may be a good alternate for diagnosis.

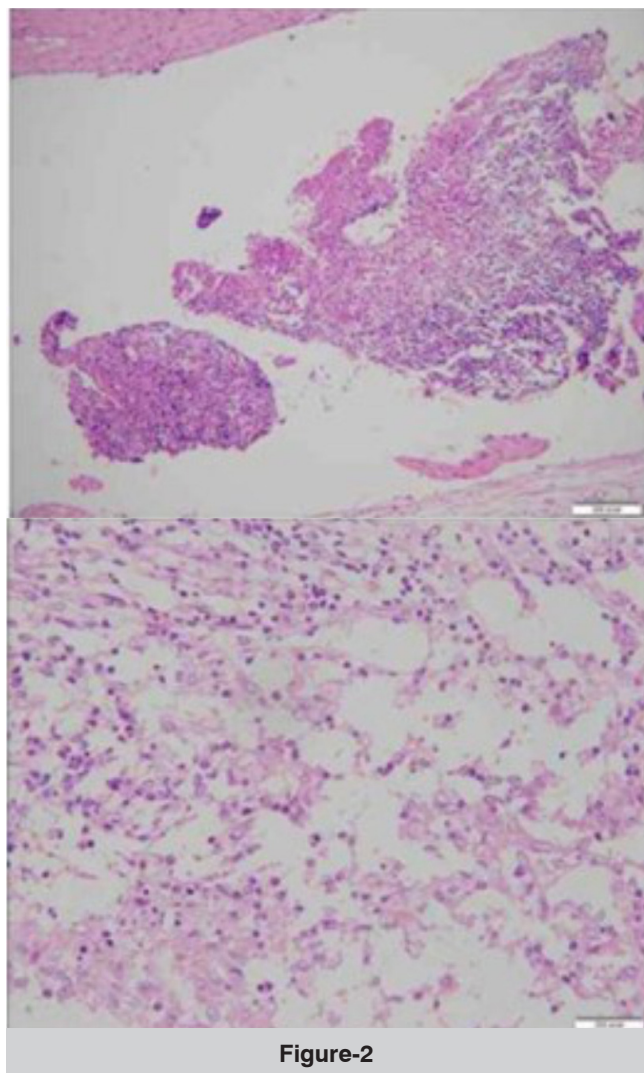


Figure-2

Laparoscopic instruments are chemically sterilized and various disinfectants like glutaraldehyde used in various concentrations and are highly active against microorganisms when properly used.⁷ In poor resource countries all laparoscopic instruments including ports and hand instruments are re used as disposable instruments are expensive. Therefore it is important that OT staff is well trained to properly disinfect the instruments. Robertson D⁸ in his study in India found that operation theater staff in many hospitals in peripheries of India is not well trained of properly disinfecting laparoscopic instruments. We have the same scenario in Pakistan and it is important to conduct training programs for OT staff to teach them to use the disinfectant in proper concentration, for adequate time and



strictly follow the guidelines. By reporting this case we recommend strict asepsis of laparoscopic instruments, high index of suspicion for port site tuberculosis when patient present with chronic port site infection, pus cultures for atypical mycobacterium and to consider first line anti tuberculous treatment as well if histopathology confirms tuberculosis.

Copyright© 06 Sep, 2023.

REFERENCES

- Gad KH, Elhefny AMM, Gerges WB, Sebaie. **Assessment of port site complication in laparoscopic abdominal surgery.** QJM-INTJMED 2020; 3(1): doi:10.1093/qjmed/hcaa050.019
- Jokar M, Larti N, Zarei M, Melali H, Zabihirad J, Maraki F et al. **Comparative study of the incidence of port site infection in disposable ports and reprocessed disposable ports in laparoscopic cholecystectomy.** Surg Laparosc Endosc Percutan Tech. 2022; 32(6):650-54. doi: 10.1097/SLE.0000000000001104.
- Samaranayake WAMP, Kesson AM, Karpelowsky JS, Outhred AC, Marais BJ. **Port-site infection due to nontuberculous mycobacteria following laparoscopic surgery.** Int J Mycobacteriol. 2020; 9(3): 231-38. doi: 10.4103/ijmy.ijmy_32_20.
- Niyas VKM, Keri VC, Singh BK, Kumar P. **Persistent laparoscopic port-site discharging sinus: A Rare Case of Mycobacterium senegalense Infection.** Int J Mycobacteriol. 2020; 9(1):100-02. doi: 10.4103/ijmy.ijmy_189_19.
- Yadav RP, Baskota B, Ranjitkar RR, Dahal S. **Surgical site infections due to non-tuberculous mycobacteria.** JNMA J Nepal Med Assoc. 2018; 56(211): 696-00. <https://www.ncbi.nlm.nih.gov/pmc/articles/PMC8997279/>
- Rehman IU, Farooqui F, Waseem S, Lee KY, Mamoon N, Riaz U et al. **Port site tuberculosis a rare post operation entity: A case report.** Ann Med Surg. 2022; 78: 103703. doi: 10.1016/j.amsu.2022.103703.
- Hune SR, Foushee AMD, Ervin MC, Anderson SJ, Ervin MD, Mallory AM. **An analysis of the effectiveness of high-level disinfection for surgical instruments used by department of defense austere surgical teams.** Mil. Med. 2021; 186: 122-28. doi: 10.1093/milmed/usaa440.
- Robertson D, Gnanaraj J, Wauben L, Huijs J, Samuel VM, Dankelman J et al. **Assessment of laparoscopic instrument reprocessing in rural India: A mixed methods study.** Antimicrob. Resist. Infect. Control. 2021; 10(1): 109. doi: 10.1186/s13756-021-00976-x

AUTHORSHIP AND CONTRIBUTION DECLARATION

No.	Author(s) Full Name	Contribution to the paper	Author(s) Signature
1	Muhammad Tahir Ghani	Treating surgeon, Manuscript writing.	
2	Afsar Ali	Treating physician, Manuscript review.	
3	Nain Sukh	Editing of manuscript, final approval.	