



ORIGINAL ARTICLE

Impact of fermented lactobacillus acidophilus and antibiotic topically during the phase of re-epithelization in wound repair of rats.

Hina Khan¹, Nadia Naeem², Sara Sughra³, Sonia Khan⁴, Shahid Hussain Soomro⁵, Abdul Sattar Abro⁶

Article Citation: Khan H, Naeem N, Sughra S, Khan S, Soomro SH, Abro AS. Impact of fermented lactobacilli acidophilus and antibiotics topically during the phase of re-epithelization in wound repair of rats. Professional Med J 2023; 30(09):1168-1173. <https://doi.org/10.29309/TPMJ/2023.30.09.7402>

ABSTRACT... Objective: To compare the topical effects of lactobacillus acidophilus strain and topical antibiotics during the phase of re-epithelization in wound repair. **Study Design:** Experimental study. **Setting:** Al-Tibri Medical College, Isra University Karachi. **Period:** June to November 2022. **Material & Methods:** This study took place in in which 45 Wistar rats were acquired and divided into three groups, Group A the control group in which normal saline was applied, Group B in which topical Lactobacillus acidophilus was applied, and Group C in which topical neomycin was applied on the 3rd, 7th, and 14th day of the study. A subcutaneous incision was given on all the rats of equal proportion, and on the 3rd, 7th, and 14th day of sampling a histological section was acquired. A micrometer was used to measure the thickness of the dermis and epidermis. Data was analyzed using SPSS, with the p-value set at <0.05. **Results:** Significant difference was seen in the mean thickness of epidermis when Lactobacillus acidophilus groups was compared with both Group A and C on the 3rd, 7th, and 14th day of the study. Significant difference was also seen in the mean thickness of the dermis when Lactobacillus acidophilus was compared with both Group A and C on the 3rd, 7th, and 14th day of the study. **Conclusion:** Lactobacillus acidophilus plays a potent role in repairing dermal tissue as it increased the thickness of dermis and epidermis.

Key words: Healing, Lactobacillus Acidophilus, Wound.

INTRODUCTION

Out of the many organs that are found in the human body, the Skin is represented to be the largest organ found and plays a vital role in different processes such as protection against harmful chemicals and pathogens, hydration, formation of vitamin D, excretion of waste products, and thermal regulation.¹ Therefore, it is prudent that the skin is protected as skin damage, if severe can lead to life-threatening consequences. The wound healing and repair process is based of a complex interaction of many cells, growth factors, and cytokines to close of the lesion. The process can be divided into four precisely and well-coordinated processes which include, hemostasis, inflammation, proliferation, and lastly remodeling. For successful wound healing to take place, all four of these phases must occur in a particular sequence and a particular time frame.²

If any one of these phases are affected in one way or another, wound healing can then become compromised. The factors which effect and delay wound healing are desiccation, infections, necrosis, pressure, trauma, edema. Diabetes, and corticosteroid therapy to name a few.³⁻⁵ There are various attempts being conducted to accelerated the well-orchestrated process of wound healing. Many experimental as well as clinical remedies are being carried out to promote the process of wound healing.⁶ Antibiotics, a pillar in modern medicine treatment are frequently being utilized in the management of chronic wounds.⁷ Topical antibiotics are used for different purposes in dermatology, these include the treatment of acne, preventing and treating wound infections, dermatitis, and more.⁸ It is also to be noted that strains of different probiotic bacteria also have great response to damage to skin, which

1. MBBS, M.Phil, Ph.D Scholar, Professor Anatomy, Al-Tibri Medical College Isra University Karachi Campus.

2. MBBS, M.Phil Scholar, Lecturer Pharmacology, Jinnah Sindh Medical University.

3. MBBS, M.Phil, Assistant Professor Anatomy, Sir Syed Medical College, Karachi.

4. MBBS, M.Phil (Pharmacology, Assistant Professor Pharmacology, Al-Tibri Medical College Isra University Karachi Campus.

5. MBBS, FCPS (Surgery), Professor Anatomy, Chandka Medical College, Shaheed Mohtarma Benazir Bhutto Medical University Larkana.

6. MBBS, FCPS, Assistant Professor Surgery, Chandka Medical College Shaheed Mohtarma Benazir Bhutto Medical University Larkana.

Correspondence Address:

Dr. Hina Khan
Department of Anatomy,
Al-Tibri Medical College Isra University
Karachi Campus.
drhinasalman@gmail.com

Article received on: 03/01/2023

Accepted for publication: 22/03/2023

include skin wounds, which include *Lactobacillus acidophilus*, with studies also suggesting that many topical applications of species such as *Lactobacillus* including *acidophilus* are effective in treating drug resistant wound pathogens.⁹ As wound healing especially of the dermal tissue is a phenomenon that is encountered at a regular basis in the clinical practice, an experimental study was conducted to determine the Topical effects of *Lactobacilli* and topical Neomycin in repairing dermal tissue.

MATERIAL & METHODS

This experimental study was conducted at the anatomy department of Al-Tibri Medical College, Isra University Karachi Campus after the ethical approval of the institutional review board (ATMC/IERC/02-2022/38). The total span of the study was for 6 months.

In total 45 healthy Male Wistar albino rats were acquired from the institution's animal house using randomized sampling technique. In the study, the rats were divided into three different groups based on the intervention performed in each group. The rats were divided into three groups, Group A (Control Group) in which Topical application using normal saline solution once a day for 14 days (Group A subdivided into three subgroups according to day of sampling, Day 3, 7 and 14. Total 5 rats in each subgroup), Group B in which Topical application of *Lactobacillus acidophilus* 10¹¹ CFU/ml once a day for the 14 days. (Group B subdivided into three subgroups according to day of sampling, Day 3, 7 and 14. Total 5 rats in each subgroup), Group C in which Topical application of Neomycin once a day for 14 days. (Group C subdivided into three subgroups according to day of sampling, Day 3, 7 and 14. Total 5 rats in each subgroup). The strain of *Lactobacillus acidophilus* was acquired through isolated strain using fermented yogurt. The microorganism was isolated and confirmed of its presence by a microbiologist. The dorsal surface of the rats was shaved and giving a subcutaneous incision of 2x2 cm². All rats were kept in different cages, on the day of sampling the subcutaneous tissue was taking for histomorphology evaluation. After taking a sample from the dermal tissue, the tissue

was prepared for staining, H&E stain was used for microscopy. Micrometer was used to measure the thickness of dermis and epidermis x400. For statistical analysis Mean thickness of dermis and epidermis in μm . To compare the mean between the groups at different days of sampling one way ANOVA was used and the level of significance was considered at $P < 0.05$. To assess the wound repair the photomicrograph was used.

RESULTS

Figure-1 shows the Mean thickness of Epidermis among three different groups on different days of sampling. Compare the Mean values of Group B with mean thickness of epidermis on day 3 with Group A, the level of significance was ≤ 0.001 . The P value shows the significant regeneration of epidermis at day 3 in Group B. Compare the Mean thickness of epidermis on day 3 between the Group B and C. The P value was 0.002, that shows the significant regeneration of epidermis in Group B.

Compare the Mean values of Group B with mean thickness of epidermis on day 7 with Group A, the level of significance was ≤ 0.001 . The P value shows the significant regeneration of epidermis at day 7 in Group B. Compare the Mean thickness of epidermis on day 7 between the Group B and C. The P value was 0.001, that shows the significant regeneration of epidermis in Group B.

Compare the Mean values of Group B with mean thickness of epidermis on day 14 with Group A, the level of significance was ≤ 0.001 . The P value shows the significant regeneration of epidermis at day 14 in Group B. Compare the Mean thickness of epidermis on day 14 between the Group B and C. The P value was 0.001, that shows the significant regeneration of epidermis in Group B.

Figure-2 shows the Mean thickness of dermis among three different groups on different days of sampling. Compare the Mean values of Group B with mean thickness of dermis on day 3 with Group A, the level of significance was ≤ 0.001 . The P value shows the significant regeneration of dermis at day 3 in Group B. Compare the Mean thickness of dermis on day 3 between the Group

B and C. The P value was ≤ 0.001 , that shows the significant regeneration of dermis in Group B.

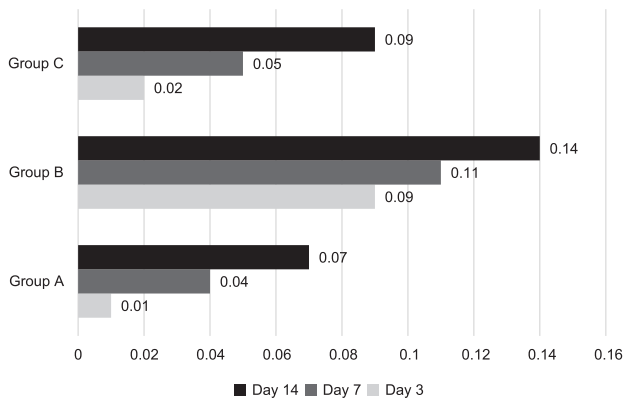


Figure-1. Mean thickness of epidermis µm x400

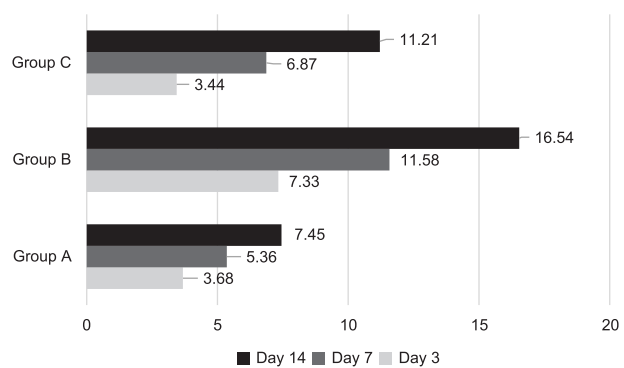


Figure-2. Shows mean thickness of dermis µm x400

Compare the Mean values of Group B with mean thickness of dermis on day 7 with Group A, the level of significance was ≤ 0.001 . The P value

shows the significant regeneration of dermis at day 7 in Group B. Compare the Mean thickness of dermis on day 7 between the Group B and C. The P value was 0.001, that shows the significant regeneration of dermis in Group B.

Compare the Mean values of Group B with mean thickness of dermis on day 14 with Group A, the level of significance was ≤ 0.001 . The P value shows the significant regeneration of dermis at day 14 in Group B. Compare the Mean thickness of dermis on day 14 between the Group B and C. The P value was ≤ 0.001 , that shows the significant regeneration of dermis in Group B.

Figure-3 shows the microscopic images of thickness of epidermis among different therapeutic groups. (x400).

Figure-4 shows the microscopic images of thickness of dermis among different therapeutic groups. (x400).

DISCUSSION

Wound repair and regeneration are a complex process. Although major hurdles still exist in this process, advancements during the past generations have aided significantly in managing this problem.¹⁰

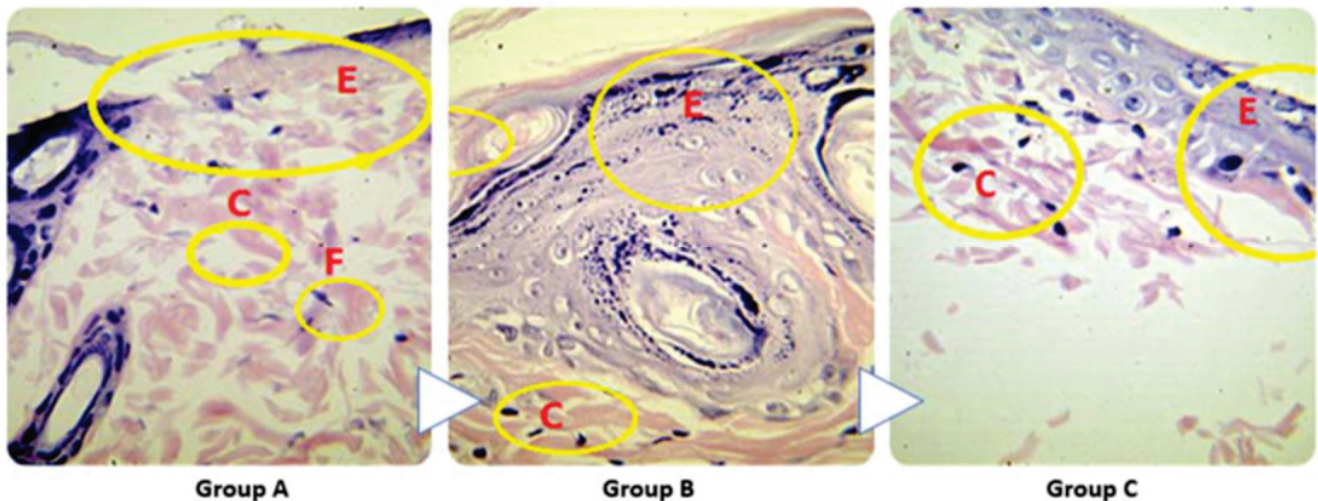


Figure-3. Shows the microscopic images of thickness of Epidermis among different Groups. On day 7 the marked thickness of epidermis as shown in Group B as compared to A & C.

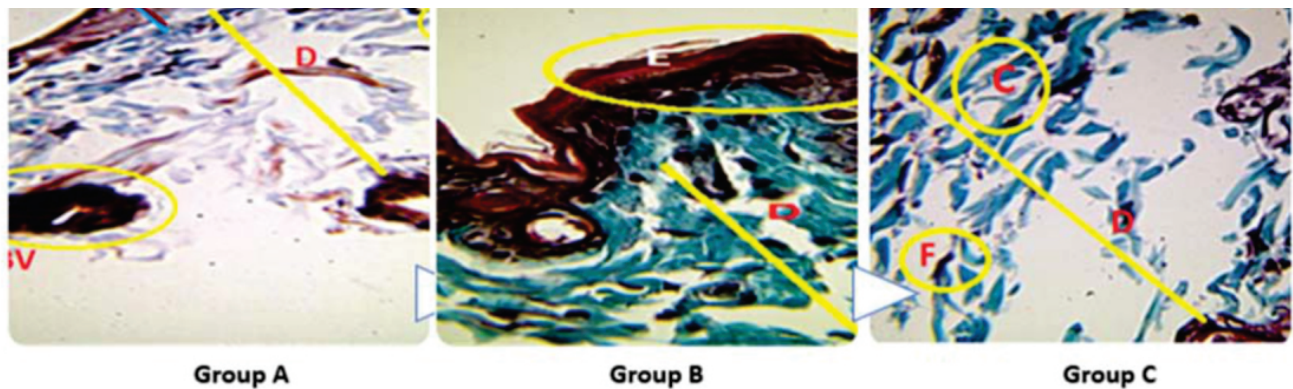


Figure-4. Shows the microscopic images of thickness of Dermis among different Groups. On day 7 the marked thickness of Dermis μm x400 as shown in Group B results in rapid re-epithelization as compared to A&C. (Trichrome stain)

As mentioned earlier the healing of wound takes places through a specific and tightly regulated process, however, if there is a dysregulation in the wound healing phenomena it can result in dermal scarring.¹¹ Therefore, therapeutic advancements which are advanced and cost-effective need to be implemented throughout the field of medicine for long term sustainability of the health care system.¹² This study was designed with this purpose to determine the topical effects of *Lactobacillus acidophilus* and Neomycin in the repair process of dermal tissue. When comparing the thickness of epidermis, Group B the group in which topical *Lactobacillus acidophilus* was applied saw significant regeneration on the 3rd, 7th, and 14th day of application. This is in line with another study in which *Lactobacillus acidophilus* was studied to evaluate its effects on 2nd degree burns in Wistar rat. That study also showed significant difference of wound healing on the 3rd and 7th day as compared to the control group. Furthermore, the same study also showed that the strain of *Lactobacillus acidophilus* provided favorable effects on the various aspects that are enshrined in the wound healing process, which includes reducing the inflammatory response and promoting the onset of granulation tissue formation, and lastly speeding up re-epithelization.¹³ Histological sections obtained in our study also showed that the *Lactobacillus* groups should marked epithelization as compared to other groups on both the 7th day. When the mean dermal thickness of all the groups were compared, significant difference can be seen when the *Lactobacillus acidophilus* group was

compared with both group A and C, on the 3rd, 7th, and 14th day. A similar study to ours has also shown that *Lactobacillus acidophilus* has a potent anti-inflammatory effect during the process of wound healing and thus it speeds up the epithelization and dermal formation.¹⁴ The lactobacilli group also showed the thickest dermal tissue of all the groups based on histological sections. The *Lactobacillus acidophilus* is a proven probiotic which has multiple uses in clinical medicine including wound healing.¹⁵⁻²⁰ Although neomycin has also shown favorable results, the strain of *Lactobacillus acidophilus* has shown even better results than the topical antibacterial agent and must be regarded as a good option in enhancing a favorable wound response.

The study did not get onto compare other strains of *Lactobacillus*. Therefore, in future other strains of *Lactobacillus* can also be compared to compare their potency to one another which will give us a better comparison regarding the different strains used. Furthermore, other agents that promote wound healing should also be compared in future studies. The study also was unable to further examine other histological features which can be done in the future as well to achieve a better wide of the physiological process of wound healing.

CONCLUSION






Topical *Lactobacillus acidophilus* strain plays a potent role in the regeneration and repair of both dermal and epidermal tissue.

Copyright© 22 March, 2023.

REFERENCES

1. Tottoli EM, Dorati R, Genta I, Chiesa E, Pisani S, Conti B. **Skin wound healing process and new emerging technologies for skin wound care and regeneration.** *Pharmaceutics*. 2020 Aug 5; 12(8):735.
2. Guo SA, DiPietro LA. **Factors affecting wound healing.** *Journal of dental research*. 2010 Mar; 89(3):219-29.
3. Hess CT. **Checklist for factors affecting wound healing.** *Advances in skin & wound care*. 2011 Apr 1; 24(4):192.
4. Okonkwo UA, DiPietro LA. **Diabetes and wound angiogenesis.** *International journal of molecular sciences*. 2017 Jul 3; 18(7):1419.
5. Wang AS, Armstrong EJ, Armstrong AW. **Corticosteroids and wound healing: clinical considerations in the perioperative period.** *The American journal of surgery*. 2013 Sep 1; 206(3):410-7.
6. Kasuya A, Tokura Y. **Attempts to accelerate wound healing.** *Journal of dermatological science*. 2014 Dec 1; 76(3):169-72.
7. Howell-Jones RS, Wilson MJ, Hill KE, Howard AJ, Price PE, Thomas DW. **A review of the microbiology, antibiotic usage and resistance in chronic skin wounds.** *Journal of antimicrobial chemotherapy*. 2005 Feb 1; 55(2):143-9.
8. Drucker CR. **Update on topical antibiotics in dermatology.** *Dermatologic therapy*. 2012 Jan; 25(1):6-11.
9. Stanbro J, Park JM, Bond M, Stockelman MG, Simons MP, Watters C. **Topical delivery of Lactobacillus culture supernatant increases survival and wound resolution in traumatic Acinetobacter baumannii infections.** *Probiotics and antimicrobial proteins*. 2020 Sep; 12(3):809-18.
10. Wu SC, Marston W, Armstrong DG. **Wound care: the role of advanced wound-healing technologies.** *Journal of the American Podiatric Medical Association*. 2010 Sep 1; 100(5):385-94.
11. Van Dongen JA, Harmsen MC, Van der Lei B, Stevens HP. **Augmentation of dermal wound healing by adipose tissue-derived stromal cells (ASC).** *Bioengineering*. 2018 Oct 26; 5(4):91.
12. Oliveira A, Simões S, Ascenso A, Reis CP. **Therapeutic advances in wound healing.** *Journal of Dermatological Treatment*. 2022 Jan 2; 33(1):2-2.
13. Barzegari AA, Hashemzadei M, Majdani R, Alihemmati AR. **Effects of topical treatment of second-degree burn wounds with Lactobacillus acidophilus on the wound healing process in male rats.** *Pharmaceutical and Biomedical Research*. 2017 Sep 10; 3(3):23-30.
14. Gudadappanavar AM, Hombal PR, Timashetti SS, Javali SB. **Influence of Lactobacillus acidophilus and Lactobacillus plantarum on wound healing in male Wistar rats-an experimental study.** *International Journal of Applied and Basic Medical Research*. 2017 Oct; 7(4):233.
15. Khan H, Masood SH, Ali SM, Shehzad K, Sughra S, Korai SM, Soomro SH. **Topical probiotics and steroids can accelerate the process of angiogenesis in wound repair: A comparative study in rats.** *The Professional Medical Journal*. 2022 Oct 31; 29(11):1630-6.
16. Sethi A, Tao J. **Topical probiotics: Scope and Challenges.** In *Probiotic Research in Therapeutics 2022* (pp. 111-130). Springer, Singapore.
17. Airlangga G. **Utilization of Lactobacillus Acidophilus FNcc-0051 Microencapsulation: Potential benefit of giving combination of sodium alginate and gelatin to attributes and role of probiotic against staphylococcus aureus.** *Scopus IJPHRD Citation Score*. 2019 Sep; 10(9):308.
18. Andrade PD, Maria e Silva J, Carregaro V, Sacramento LA, Roberti LR, Aragon DC, Carmona F, Roxo-Junior P. **Efficacy of probiotics in children and adolescents with atopic dermatitis: A randomized, double-blind, placebo-controlled study.** *Frontiers in Nutrition*. 2022 Jan 26; 8:1360.
19. Piqué N, Berlanga M, Miñana-Galbis D. **Health benefits of heat-killed (Tyndallized) probiotics: An overview.** *International journal of molecular sciences*. 2019 May 23; 20(10):2534.
20. Oluwatosin SO, Tai SL, Fagan-Endres MA. **Sucrose, maltodextrin and inulin efficacy as cryoprotectant, preservative and prebiotic-towards a freeze dried Lactobacillus plantarum topical probiotic.** *Biotechnology Reports*. 2022 Mar 1; 33:e00696.

AUTHORSHIP AND CONTRIBUTION DECLARATION

No.	Author(s) Full Name	Contribution to the paper	Author(s) Signature
1	Hina Khan	Conceptualization, Study conduction, Data analysis.	
2	Nadia Naeem	Data collection.	
3	Sara Sughra	Manuscript writing.	
4	Sonia Khan	Manuscript writing.	
5	Shahid Hussain Soomro	Data collection and Clinical review.	
6	Abdul Sattar Abro	Data collection and Analysis.	