



CASE REPORT

Angiomatoid fibrous histiocytoma; Retroperitoneal rare manifestation.

Naila Jabbar¹, Farooq Ahmad Rana², Hasham Akram³, Zaka Ullah⁴

Article Citation: Jabbar N, Rana FA, Akram H, Zaka Ullah. Angiomatoid fibrous histiocytoma; Retroperitoneal rare manifestation. Professional Med J 2023; 30(03):421-423. <https://doi.org/10.29309/TPMJ/2023.30.03.7330>

ABSTRACT... Angiomatoid fibrous histiocytoma (AFH) is a sporadic, soft tissue cancer with malignant potential that happens most frequently in children and young adults. We represent an infrequent case of young male with retroperitoneal AFH. Only a rare case reports have been defined that classically occur in the extremes of the deep dermis and subcutaneous tissue, followed by head and neck, as well as the trunk. We emphasize that AFH may occur in retroperitoneal tumors. Surgical resection is mainstay management because it decreases the local symptoms.

Key words: Angiomatoid Fibrous Histiocytoma, Retro Peritoneum.

INTRODUCTION

Angiomatoid fibrous histiocytoma is an uncommon, low-grade malignant soft tissue tumor of uncertain histogenesis. It most commonly occurs in the deep dermis or sub cutis of the extremities in children and young adults.¹ It was named “Angiomatoid fibrous histiocytoma” in 1979 by Enzinger. Only rarely does this tumor occur outside somatic soft tissues, including the brain, mediastinum, lung, bone, retroperitoneal and omentum.^{2,3}

Real level of differentiation is still unknown. The term tumor is used instead of malignant because of AFH behavior (slow growth and rare metastasis), its good prognosis and benign appearance and wide local excision being sufficient management.⁴

Here, a case reported of Angiomatoid fibrous histiocytoma presented in retro peritoneum. The diagnosis of AFH was based on pathological review along with immune/histochemistry.

CASE REPORT

Our patient presented to us in outpatient department with complain of pain in left side of upper abdomen for last 3 months. He was a

teenager of 18 years with normal built and height. He was in usual state of health 3 months back, then he experienced recurrent episodes of pain in left upper abdomen. It was sudden in onset and progressively increase in intensity day by day. He has no associated fever, nausea, vomiting, bleeding episodes, night sweats, weight loss, melena or hematemesis etc. there was no history of other recent systemic illness. He visited emergency of different hospitals for pain management. No proper follow up done.

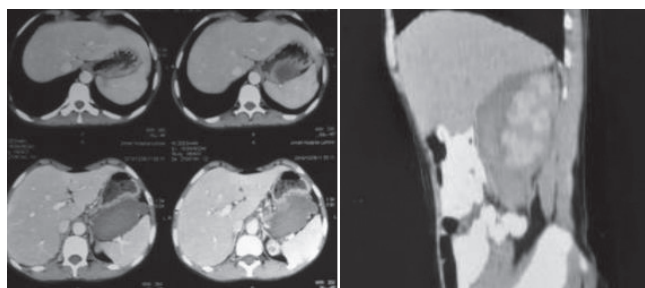
On clinical examination, Abdomen was of normal contour. there was no mass palpable in whole abdomen. Examination of abdomen, respiratory system, nervous system was unremarkable. No palpable lymphadenopathy. Baseline investigations are normal including CRP. Chest X-ray was normal. Bleeding profile is within normal limit. ESR was 72 mm/1st HR. Amylase, lipase, Beta hCG, LDH, Alpha Fetoprotein and other markers were normal. Abdominal sonography showed mixed echogenicity lesion measuring 13.3 x 4.7cm in epigastrium anterosuperior to pancreas. Gastroscopy and Colonoscopy were unremarkable.

1. MBBS, Postgraduate Resident General Surgery, Jinnah Hospital, Lahore.
2. MBBS, FCPS, MRCS, FRCS, Professor General & Laparoscopic Surgery, Jinnah Hospital, Lahore.
3. MBBS, FCPS, MRCS, FRCS, General Surgeon, Surgical Unit-1, UK.
4. MBBS, Postgraduate Resident General Surgery, Jinnah Hospital, Lahore.

Correspondence Address:
Dr. Naila Jabbar
General surgeon, Surgical Unit 1, UK
dr.nailajabbar@gmail.com

Article received on: 21/10/2022
Accepted for publication: 28/12/2022

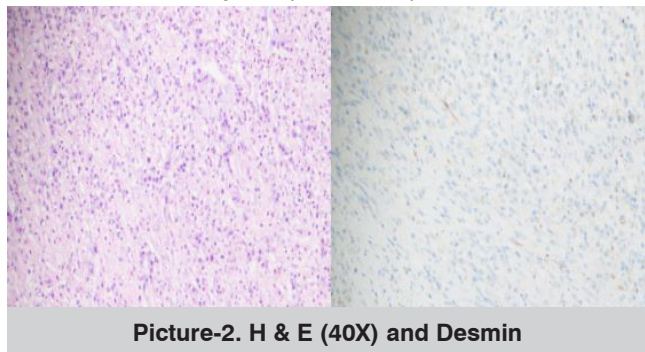
CT scan defined a well-defined retroperitoneal area of 10.1 x 9.5 x 5.0 cm in the left hypochondrium (Picture-1).



Picture-1. CT scan showing mass

Endoscopic Ultrasonography shows a well capsulated dumbbell shaped avascular 12.3x 5 cm mass with internal necrosis in retroperitoneal area in gastric bed. PET scan was negative.

In biopsy tissue cores showed lymphohistiocytic infiltrate and spindle cell proliferation. All stains (ZN, GMS, SOX10, Desmin, DOG1, CD117 and ALK) were negative. Only CD 48 was positive in scattered histiocytes (Picture-2).



Picture-2. H & E (40X) and Desmin

Per operatively, a nodular mass of 7.3x3.5x3.5cm was retrieved from left retro peritoneum without any extensions with stomach bed and pancreas. A benign looking mass. Cut surfaces revealed hemorrhagic clot like appearance with yellowish rim at periphery. On biopsy, Diagnosis was Angiomatoid fibrous histiocytoma. But lesion was present at inked margins.

On follow up, patient was stable and symptom free with healthy wound. Oncology consultation done. Post operatively, on investigations there was no evidence of residual disease and metastasis. Patient is kept under follow up. After every 6 months, follow up CT scan is being done

which is unremarkable so far.

DISCUSSION

AFH is a very rare mesenchymal neoplasm of uncertain differentiation, initially described as malignant AFH. It most commonly occur in Young adults and children involving deep dermis and subcutaneous tissue of limbs, followed by head and neck, trunk and bone.² It frequently present as unproblematic and slow growing tumor but most common symptoms of AFH are fever, weight loss, anemia, Castleman disease like lymphadenopathy and polyclonal gammopathy.⁵

Conferring to one pathological review, AFH typically reveals four features: a pseudo angiomatous pattern, fibro histiocytic cell proliferation, a fibrous pseudo-capsule and plasma lymphocytic infiltrate.⁶ Radiograph and CT scan usually shows heterogeneous mass with enhancing parts or cystic component, in case of sarcoma. MRI mostly shows (a) foci of artefacts representing hemosiderin deposits, (b) an enhancing fibrous pseudo capsule showing hypo intensity T1 and T2 imaging and (c) multiple internal cystic areas.⁷

It is repeatedly misdiagnosed primarily. A minor number of AFH cases recur locally and rare number of cases metastasize. The best remedy for AFH is surgery along with a wide local excision. Complete treatment such as radiation and chemical therapy can be used when wide excision of boundaries are not possible.⁸




A lot of studies are done to determine the malignant potential of AFH. A meta-Analysis of multiple AFH studies describe that huge number of patients 73.2% have good prognosis and they remain disease free. 23.2% patients develop recurrence and rate of metastasis within 2 years is 8.7%. Clinical behavior of tumor cannot be predicted grounded on clinical and histological parameters.^{9,10} Due to its low malignant rate and unpredicted behavior, we have kept our patient under strict follow up.

Copyright© 28 Dec, 2022.

REFERENCES

- Enzinger FM. **Angiomatoid malignant fibrous histiocytoma. A distinct fibrohistiocytic tumor of children and young adults simulating a vascular neoplasm.** Cancer. 1979; 44(6):2147-57.
- Asakura S, Tezuka N, Inoue S, Kihara N, Fujino S. **Angiomatoid fibrous histiocytoma in mediastinum.** Ann Thorac Surg. 2001; 72(1):283-5.
- Mangham DC, Williams A, Lalam RK, Brundler M-A, Leahy MG, Cool WP. **Angiomatoid fibrous histiocytoma of bone: A calcifying sclerosing variant mimicking osteosarcoma.** Am J Surg Pathol. 2010; 34(2):279-85.
- Matushansky I, Charytonowicz E, Mills J, Siddiqi S, Hricik T, Cordon-Cardo C. **MFH classification: differentiating undifferentiated pleomorphic sarcoma in the 21st century.** Expert Rev Anticancer Ther. 2009; 9(8):1135-44.
- García JJ, Folpe AL. **The impact of advances in molecular genetic pathology on the classification, diagnosis and treatment of selected soft tissue tumors of the head and neck.** Head Neck Pathol. 2010; 4(1):70-6.
- Grossman LD, Arber DA. **Angiomatoid fibrous histiocytoma.** Ann Plast Surg. 1996; 36(6):649-51.
- Petrey WB, LeGallo RD, Fox MG, Gaskin CM. **Imaging characteristics of angiomatoid fibrous histiocytoma of bone.** Skeletal Radiol. 2011; 40(2):233-7.
- Davis AM, O'Sullivan B, Turcotte R, Bell R, Catton C, Chabot P, et al. **Late radiation morbidity following randomization to preoperative versus postoperative radiotherapy in extremity soft tissue sarcoma.** Radiother Oncol. 2005; 75(1):48-53.
- Bauer A, Jackson B, Marner E, Gilbertson-Dahdal D. **Angiomatoid fibrous histiocytoma: A case report and review of the literature.** J Radiol Case Rep. 2012; 6(11):8.
- DeVita Jr VT, Lawrence T, Rosenberg SA. **Cancer: Principles & practice of oncology: Annual advances in oncology.** Lippincott Williams & Wilkins; 2012.

AUTHORSHIP AND CONTRIBUTION DECLARATION

No.	Author(s) Full Name	Contribution to the paper	Author(s) Signature
1	Naila Jabbar	All authors have equal contributions.	
2	Farooq Ahmad Rana		
3	Hasham Akram		
4	Zaka Ullah		