



ORIGINAL ARTICLE

## Role of angiography procedure for assessment of the type of patent ductus arteriosus in children under 18 years.

Shanzay Saeed<sup>1</sup>, Danial Hanan Sheikh<sup>2</sup>, Rimsha Badar<sup>3</sup>, Humaira Rauf<sup>4</sup>, Syed Zain-ul-Abidin<sup>5</sup>

**Article Citation:** Saeed S, Sheikh SDH, Badar R, Rauf H, Zain-ul-Abidin S. Role of angiography procedure for assessment of the type of patent ductus arteriosus in children under 18 years. Professional Med J 2023; 30(03):309-313. <https://doi.org/10.29309/TPMJ/2023.30.03.7242>

**ABSTRACT... Objective:** To determine the role of angiography for the assessment of the type of patent ductus arteriosus in children under 18 years. **Study Design:** Observational Retrospective study. **Setting:** Children's Hospital Lahore. **Period:** October 2021 to February 2022. **Material & Methods:** The sample size calculated was 245 but, at the end of the period of four months only 120 patients fulfilled the criteria and were included in this study convenient sampling technique was used to collect the data. Patients with patent ductus arteriosus were included in this study. Patients with other congenital heart diseases were excluded. Essential measurements included Types of Patent Ductus Arteriosus (PDA), (PDA) Size, Ampulla Size, Aortic and Pulmonary systolic and diastolic pressures. **Results:** In this study 120 patients with PDA were included. Out of 120, 38 (31.7%) patients were male and 82 (68.3%) patients were female. The age range of the patients was 8 months to 18 years (mean;  $5.44 \pm 3.972$  years). The weight range of the patients was 5.3 to 41 Kg (mean;  $16.05 \pm 8.38$  Kg). The mean PDA size was  $4.01 \pm 1.80$ . The mean Ampulla size was  $9.92 \pm 3.13$ . The types of PDA detected by angiography were Type A 59(49%), Type B 15(12.5%), Type C 20(16.7%), Type D 20(16.7%), Type E 5(4%), Type F 1(0.8%). The mean Aortic systolic pressure was  $105.5 \pm 18.99$  and diastolic pressure was  $57.2 \pm 14.4$ . The mean Pulmonary Artery systolic pressure was  $47.4 \pm 23.3$  and diastolic pressure was  $27.7 \pm 14.2$ . **Conclusion:** Angiography was found more accurate for the assessment of all the anatomical types of PDA especially TYPE B, C, D and F. More precise measurements of the ampulla and PDA sizes were obtained using angiography. We may conclude that Angiography is a much better modality than other modalities for the assessment of the types of PDA.

**Key words:** Ampulla Size, Angiography, Congenital Heart Disease, Patent Ductus Arteriosus, PDA Size.

### INTRODUCTION

Ductus arteriosus in the fetus is a normal opening or vascular structure which connects the proximal left pulmonary artery with the proximal part of the descending aorta just distal to the left subclavian artery.<sup>1</sup> The fetal blood circulation is usually more complicated than the blood flow after the birth of the baby. During fetal life the lungs are non-functional and this ductus arteriosus provides a pathway to blood to bypass the lungs. Normally the functional closure of ductus arteriosus takes place within 12-24 hr after birth but, if it fails to do so it is called patent ductus arteriosus a congenital heart disease.<sup>2</sup>

The reported incidence of patent ductus arteriosus

is around 1 in 2000 births.<sup>3,4,5</sup> This is about 5% to 10% of all congenital heart diseases.<sup>2,3,6</sup> The causes of PDA include Genetic syndrome e.g. Down's syndrome, Maternal rubella infection, Diabetes during pregnancy, etc. Rapid breathing when baby is feeding, sweating, and poor weight gain the are most common symptoms.

The morphology of the PDA can be defined by the changes that take place during fetal life in the shapes of the pulmonary artery and aorta. PDA was classified by Krichenko in 1989, on the basis of its angiographic appearance termed as Krichenko Classification.<sup>7</sup> It has five types Type A-E. Type A (Conical), Type B (Window), Type C (Tubular), Type D (Complex) and Type

1. B.Sc (Hons) Medical Imaging Technology, FMH College of Medicine and Dentistry, Children's Hospital Lahore.  
2. B.Sc (Hons) MIT, MS-MIT, HCPC (UK), Certified in Obs/ Gyne USG, Assistant Professor HOD/MIT FMHCMD, Lahore.  
3. B.Sc (Hons) MIT, Certified in Obs/ Gyne Ultrasound, Demonstrator MIT, FMHCMD, Lahore.  
4. B.Sc (Hons) MIT, M.Phil MIT, Certified in Obs/Gyne USG (PAK), Assistant Professor HOD/MIT Chief Coordinator AHS.  
5. B.Sc (Hons), MIT, Ms MIT, Senior Technologist Children's Hospital.

**Correspondence Address:**

Shanzay Saeed  
FMH College of Medicine and Dentistry,  
Children's Hospital Lahore.  
shanzaysaeed18@gmail.com

**Article received on:** 22/08/2022  
**Accepted for publication:** 18/11/2022

E (Elongated). Type F (Fetal Type) of PDA is not classified by Krichenko classification.<sup>8</sup> Type F has a hockey stick like appearance.<sup>9</sup>

Treatments available for PDA include medical management, transcatheter closure by occluder devices and surgical therapy.<sup>10,11,12,13</sup> Many imaging modalities are used for the diagnosis of PDA like chest X-ray, echocardiography and cardiac catheterization, computed tomography, CT angiography, three dimensional rotational angiography and magnetic resonance imaging.<sup>14,15</sup> Angiography is being used for the diagnosis as well as assessment of the Types of PDA and for the evaluation of ampulla and PDA sizes.<sup>16,17</sup>

This research will help in the appropriate selection of suitable devices for duct occlusion on the basis of Krichenko angiographic classification of PDA prior to the duct closure.<sup>18</sup> The angiographic findings of this study will lead to the timely and accurate treatment of PDA patients by transcatheter closure at the same place and at the same time.

The objective of this study was to determine the role of angiography procedure for assessment of the type of patent ductus arteriosus in children under 18 years.

The aim of the study was to evaluate the accuracy of angiography for the assessment of the types of PDA. This study will help physician to assess the Types of PDA with better modality. This will help in the treatment of patients.

## **MATERIAL & METHODS**

This observational retrospective study was conducted at Children's Hospital Lahore. The duration of this study was four months from October 2021 to February 2022.

### **Inclusion Criteria**

Included Patent Ductus Arteriosus (PDA) patients.

### **Exclusion Criteria**

Excluded patients with other congenital heart diseases e.g (VSD, ASD, TOF etc.).

## **METHODOLOGY**

Angiography was performed using Siemens Biplane and Philips Hybrid Angiography machines.

Angiography is an ionizing imaging modality used to obtain detailed images of the heart and blood vessels. The angiography procedure is performed in catheterization lab or Cath Lab. A paediatric or adult catheterization procedure is longer than an adult coronary catheterization procedure.<sup>19</sup> It takes around 2 to 3 hours. The patient is sedated before the procedure by giving sedative medications orally or intravenously. Seldinger technique is used to establish arterial or venous access.<sup>18,20</sup> The access site is numbed by injecting a local anaesthetic called lidocaine subcutaneously. After gaining arterial access 50IU/Kg Heparin is administered.<sup>20</sup> The femoral access site is used to position catheter in the descending aorta just below the expected location of PDA. Hemodynamic measurements are obtained during the procedure. A Physiologic recorder is used to display the Aortic systolic and diastolic pressure (PAP) waveforms as well as the Pulmonary artery systolic and diastolic pressure (SAP) waveforms. Once the catheter is properly positioned at the region of interest an iodinated low osmolar non-ionic contrast media e.g Ultravist is injected into the patient. The dose of contrast media is about 1-2ml/Kg. The lateral projection is used to obtain initial angiogram. Krichenko classification is used to determine the anatomical type of PDA. After viewing the shape of PDA adequately the software of the Cath Lab machine is used to measure PDA and Ampulla sizes in millimetre. Right anterior oblique RAO 35 to 40 using cranial angulation of 30 can be used for further evaluation in some patients.<sup>11</sup>

## **RESULTS**

In this study (120) patients were taken as a sample size out of which 38 (31.7%) were male and 82 (68.3%) were female who fulfilled the criteria, with patent ductus arteriosus PDA were included in this study. The mean age of the patients ranged from 8 months to 18 years with a mean of  $5.44 \pm 3.972$ . The mean weight of the patients ranged from 5.3 to 41 Kg with a mean of  $16.05 \pm 8.38$ . The mean PDA size was  $4.01 \pm$

1.80. The mean Ampulla size was  $9.92 \pm 3.13$ . The mean Aortic systolic pressure was  $105.5 \pm 18.99$  and diastolic pressure was  $57.2 \pm 14.4$ . The mean Pulmonary Artery systolic pressure was  $47.4 \pm 23.3$  and diastolic pressure was  $27.7 \pm 14.2$ . The demographic characteristics are shown in Figure-1 and Table-I and angiographic measurements are given in Table-II below.

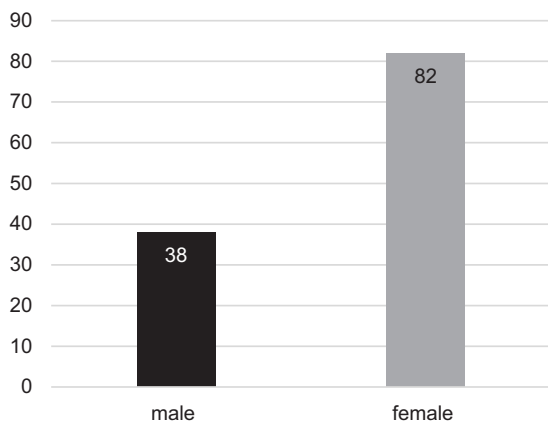


Figure-1. Bar chart showing gender of patient (n=120)

Demographic Parameters	Mean $\pm$ SD
Age (years)	$5.44 \pm 3.972$
Weight (Kg)	$16.05 \pm 8.38$

Table-I. Demographic characteristics (n=120)

Angiographic Measurements	Mean $\pm$ SD
PDA Size	$4.01 \pm 1.80$
Ampulla Size	$9.92 \pm 3.13$

Table-II. Angiographic measurements (n=120)

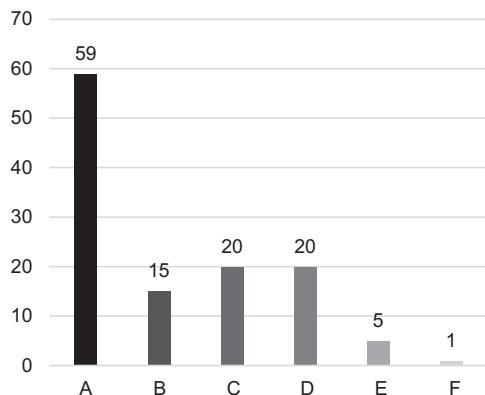


Figure-2. Bar chart showing types of PDA (n=120)

Out of 120 patients who were selected for the assessment of the type of PDA using angiography

59 were TYPE A (49%), 15 were TYPE B (12.5%), 20 were TYPE C (16.7%), 20 were TYPE D (16.7%), 5 were Type E (4%), 1 was Type F (0.8%). The details of the Types of PDA are given in Figure-2 below.

Krichenko angiographic classification of the Types of PDA shown in Figure-3 below.

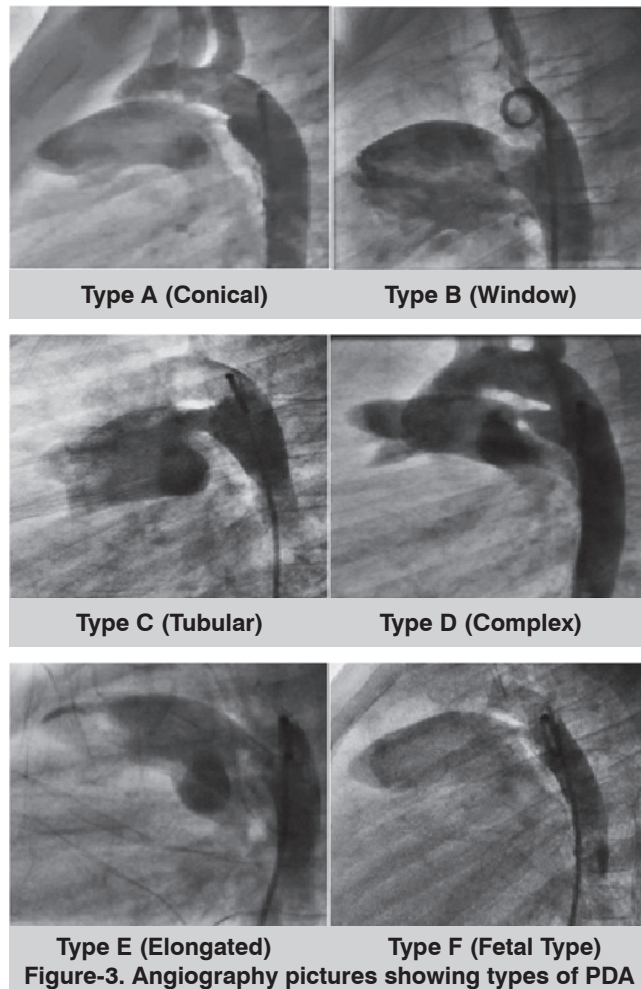


Figure-3. Angiography pictures showing types of PDA

**DISCUSSION**

According to this study, (120) patients were taken as a sample size out of which 38 (31.7%) were male and 82 (68.3%) were female who fulfilled the criteria, with patent ductus arteriosus PDA. All the patients underwent angiography procedure for the assessment of the types of PDA.

In this study Type A of PDA was found in a large number of patients whereas, TYPE F was least among the all. Out of 120 patients who were included in this study 59 were TYPE A (49%), 15

were TYPE B (12.5%), 20 were TYPE C (16.7%), 20 were TYPE D (16.7%), 5 were Type E (4%), 1 was Type F (0.8%). The mean PDA size measured was  $4.01 \pm 1.80$  and the mean Ampulla size measured was  $9.92 \pm 3.13$ .

Alaa Roushdy et al.<sup>11</sup>, concluded that out of 42 patients Type A was the most common Type of PDA and Type B was least common Type of PDA. The anatomical types of PDA assessed by angiography were Type A 20(47.6%), Type B 1(2.3%), Type C 2(4.7%), Type D 2(4.7%), Type E 17(40.4%). The pulmonary end measured by angiography had a mean of  $1.8 \pm 0.5$ mm. The aortic end measured by angiography had a mean of  $7.4 \pm 1.4$ mm.

Raghda Ghonimy Elsheikh et al.<sup>12</sup>, concluded that out of 25 patients Type A was the most common Type of PDA whereas, no patient had Type D of PDA using angiography. The anatomical types of PDA assessed by angiography were Type A 14(56%), Type B 1(4%), Type C 2(8%), Type D 0(0.00%), Type E 8(32%). The pulmonary end of the duct measured by angiography had a mean of  $2.64 \pm 0.87$ mm. The aortic end measured by angiography had a mean of  $5.98 \pm 1.92$ mm. The length of the PDA had a mean of  $7.79 \pm 2.31$ mm.

Now, if we compare this study results with the international studies angiography was found more accurate for the assessment of all the anatomical types of PDA especially TYPE B, C, D and F. This study helped in the assessment of Type F (fetal type) of PDA as well which wasn't found before even not in the above- mentioned studies. It was found that Type A of PDA was found in a large number of patients and the percentage of Type B, Type C and Type D assessed were comparatively lesser than TYPE A and TYPE F was least among the all. Moreover, more precise measurements of the ampulla and PDA sizes were obtained using angiography. Therefore, we may consider angiography as a much better modality for accurate diagnosis and assessment of the Types of PDA.

Limitations of this study include the following:

- The sample size was small.

- This was a single center study; a multi-center study should be conducted.

## CONCLUSION

Angiography was found more accurate for the assessment of all the anatomical types of PDA especially TYPE B, C, D and F. As well as more precise measurements of the ampulla and PDA sizes were obtained using angiography. We may conclude that Angiography is a much better modality than other modalities for the assessment of the types of PDA.





Copyright© 18 Nov, 2022.

## REFERENCES

1. Schneider DJ, Moore JW. **Patent ductus arteriosus**. *Circulation*. 2006 Oct 24; 114(17):1873-82. DOI: 10.1161/CIRCULATIONAHA.105.592063
2. Elsheikh RG, Darweish AZ, Elsetiha M, Kamel H. **Comparative study between real time three dimensional echocardiogram and angiography in evaluation of patent ductus arteriosus, single center experience**. *Journal of the Saudi Heart Association*. 2014; 26:204-11.
3. Kim LK. **What is the prevalence of patent ductus arteriosus (PDA)?** [Internet]. Nov 20, 2018. Available from: <https://www.medscape.com/answers/891096-69142/what-is-the-prevalence-of-patent-ductus-arteriosus-pda>.
4. Fanaroff AA. **Birth prevalence of congenital heart disease worldwide: A systematic review and meta-analysis**. *Yearb Neonatal Perinat Med*. 2012 Jan; 2012:101-3.
5. Wu W, He J, Shao X. **Incidence and mortality trend of congenital heart disease at the global, regional, and national level,1990–2017**. 1990; Available from: <http://dx.doi.org/10.1097/MD.0000000000020593>
6. Mullins CE. **Cardiac catheterization in congenital heart disease: Pediatric and adult**. *Cardiac Catheterization in Congenital Heart Disease: Pediatric and Adult*. 2007. p. 1-932.
7. Krichenko A, Benson LN, Burrows P, Moes CAF, McLaughlin P, Freedom RM. **Angiographic classification of the isolated, persistently patent ductus arteriosus and implications for percutaneous catheter occlusion**. *Am J Cardiol*. 1989; 63:877-80.

8. Philip R, Rush Waller B, Agrawal V, Wright D, Arevalo A, Zurakowski D, et al. **Morphologic characterization of the patent ductus arteriosus in the premature infant and the choice of transcatheter occlusion device.** Catheter Cardiovasc Interv. 2016; 87(2):310-7.
9. Paudel G, Johnson JN, Philip R, Taylor N, Fahnhorst S, Briceno-Medina M, et al. **Echocardiographic versus angiographic measurement of the patent ductus arteriosus in extremely low birth weight infants and the utility of echo guidance for transcatheter closure.** J Am Soc Echocardiogr [Internet]. 2021; 34(10):1086-94. Available from: <https://doi.org/10.1016/j.echo.2021.06.005>
10. Mayo Clinic Staff. **Patent ductus arteriosus (PDA) - Symptoms and causes - Mayo Clinic [Internet]. Mayo Foundation for Medical Education and Research.** 2021. Available from: <https://www.mayoclinic.org/diseases-conditions/patent-ductus-arteriosus/symptoms-causes/syc-20376145>
11. Roushdy A, El Fiky A, El Din DE. **Visualization of patent ductus arteriosus using real-time three-dimensional echocardiogram: Comparative study with 2D echocardiogram and angiography.** Journal of the Saudi Heart Association. 2012; 24:177-86.
12. Elsheikh RG, Darweish AZ, Elsetiha M, Kamel H. **Comparative study between real time three dimensional echocardiogram and angiography in evaluation of patent ductus arteriosus, single center experience.** Journal of the Saudi Heart Association. 2014; 26:204-11.
13. Zahn EM, Peck D, Phillips A, Nevin P, Basaker K, Simmons C, et al. **Transcatheter closure of patent ductus arteriosus in extremely premature newborns: Early results and midterm follow-up.** JACC Cardiovasc Interv. 2016 Dec; 9(23):2429-37.
14. Jadhav SP, Aggarwal V, Masand PM, Diaz E, Zhang W, Qureshi AM. **Correlation of ductus arteriosus length and morphology between computed tomographic angiography and catheter angiography and their relation to ductal stent length.** Pediatr Radiol. 2020; 50(6):800-9.
15. Kang SL, Armstrong A, Krings G, Benson L. **Three-dimensional rotational angiography in congenital heart disease: Present status and evolving future.** Congenit Heart Dis. 2019; 14(6):1046-57.
16. Puranik R, Muthurangu V, Celermajer DS, Taylor AM. **Congenital heart disease and multi-modality imaging.** Hear Lung Circ. 2010; 19(3):133-44.
17. Philip R, Towbin J, Taylor N, Joshi V, Johnson JN, Naik R, et al. **Feasibility and safety of percutaneous cardiac interventions for congenital and acquired heart defects in infants  $\leq 1000$  g.** 2021; Available from: <https://doi.org/10.3390/children8090826>
18. Chen W, Yan X, Huang Y, Sun X, Zhong L, Li J, et al. **Transthoracic echocardiography as an alternative major guidance to angiography during transcatheter closure of patent ductus arteriosus: Technical feasibility and clinical relevance.** Pediatr Cardiol. 2015; 36(1):14-9.
19. Moustafa GA, Kolokythas A, Charitakis K, Avgerinos D V. **Diagnostic cardiac catheterization in the pediatric population.** Curr Cardiol Rev. 2016; 12(2):155-62.
20. Feltes TF, Bacha E, Beekman RH, Cheatham JP, Feinstein JA, Gomes AS, et al. **Indications for cardiac catheterization and intervention in pediatric cardiac disease: A scientific statement from the American Heart Association.** Circulation. 2011; 123(22):2607-52.

### AUTHORSHIP AND CONTRIBUTION DECLARATION

No.	Author(s) Full Name	Contribution to the paper	Author(s) Signature
1	Shanzay Saeed	Research contribution, Design of the work, Drafting the article.	
2	Danial Hanan Sheikh	Conception of the work, Methodology design, Final approval, Clinical supervisor.	
3	Rimsha Badar	Data Analysis, Data interpretation.	
4	Humaira Rauf	Approval of the version published.	
5	Syed Zain-ul-Abidin	Data collection and Provider Clinical assessment.	