



PATENT DUCTUS ARTERIOSUS; TRANSCATHETER CLOSURE OF PATENT DUCTUS ARTERIOSUS USING AMPLATZER DUCT OCCLUDER: INITIAL EXPERIENCE AT FAISALABAD INSTITUTE OF CARDIOLOGY

1. FCPS (Paeds Med), FCPS (Paeds Card)

Assistant Professor of Paediatric Cardiology
Faisalabad Institute of Cardiology,
Faisalabad.

2. MBBS

Post Graduate Registrar
Faisalabad Institute of Cardiology,
Faisalabad.

3. FRCPCH, FRCP (Ed), MRCP (UK),
DCH

Professor of Paediatric Cardiology &
Dean Children's Hospital &
Institute of Child Health Lahore.

4. FCPS (Paediatric Medicine)

Senior Registrar Paediatric
Cardiology
Children Hospital, Faisalabad.

Abdul Razzaq Mughal¹, Ali Farahe², Masood Sadiq³, Rubina Tousif⁴

ABSTRACT... Background: Device closure of Patent ductus arteriosus (PDA) using Amplatzer Duct Occluder (ADO) is a well-known modality to treat PDA with limited complications **Objectives:** To assess the efficacy, safety and immediate complications of percutaneous device closure of PDA using Amplatzer Duct Occluder. **Study Design:** Descriptive case series. **Place and Duration of Study:** Paediatric Cardiology Department of Faisalabad Institute of Cardiology, Faisalabad from May, 2012 to July, 2017. **Methods:** All consecutive patients undergoing cardiac catheterization for device closure were included. Detailed Echocardiography was done by dedicated pediatric cardiologist before the procedure. Successfulness of procedure and problems were recorded. **Results:** Out of 74 patients two had unsuitable anatomy for device occlusion so were excluded while 72 patients underwent successful device closure. Complete occlusion was achieved in all cases (100%) without any residual leak. There was not a single case of device embolization, LPA obstruction or Coarctation of aorta while upper end of device protruded in descending aorta in 12 patients (8.45%) with no obstruction in descending aorta. Three patients lost lower limb arterial pulse (4.17%) and one patient had weak pulse (1.39%) but pulses revived after injection heparin and streptokinase. **Conclusion:** Device closure of PDA using Amplatzer Duct Occluder is a safe and effective therapeutic modality with minimal complications

Correspondence Address:

Dr Abdul Razzaq Mughal,
House number 10, FIC residential
Colony,
Faisalabad Institute of Cardiology
Faisalabad
a.razzaq.cs@gmail.com

Key words: Patent ductus arteriosus, Amplatzer duct occluder, Device embolization, Arterial pulse.

Article received on:

04/04/2018

Accepted for publication:

20/10/2018

Received after proof reading:

06/11/2018

Article Citation: Mughal AR, Farahe A, Sadiq M, Tousif R. Patent ductus arteriosus; transcatheter closure of patent ductus arteriosus using amplatzer duct occluder: initial experience at Faisalabad Institute of Cardiology. Professional Med J 2018; 25(11):1615-1621. DOI:10.29309/TPMJ/18.5138

INTRODUCTION

Patent ductus arteriosus (PDA) is a common form of structural congenital heart defect (CHD). The incidence of Patent ductus arteriosus (PDA) is 6-11% of all congenital heart defects.¹⁻² Usually beyond 3rd month of life, PDA does not close naturally. Any patient with signs of left ventricular volume overload due to a ductus needs closure of the duct, with device or a coil being the standard of care these days. Echocardiography has limitation to accurately image the ductus. Cardiac catheterization and angiogram is the gold standard for the accurate diagnosis of PDA and delineating the exact anatomy of ductus which if feasible can be closed during the same setting. Transcatheter closure of PDA with device is a safe, effective and established modality of treatment worldwide.³⁻⁵

Percutaneous technique for PDA closure was first described by Porstmann et al.⁶ The early devices utilized for closure were double disc umbrella devices (Rashkind PDA Occluder, CR BARD, Billerica, MA, USA)⁷⁻⁸, the Botaloccluder, the buttoned device (Custom Medical Devices, Amarillo, Texas, USA)⁹ and a coil filled bag (Gianturco-Grifka Vascular Occlusion Device, Cook Inc., Bloomington IN, USA).¹⁰ Nowadays Coils and the Amplatzer Duct Occluder (ADO) are used most frequently for PDA closure. Moderate to large sized PDA can be safely occluded using the ADO in patients weighing 3.5kg or more, with excellent occlusion rates and minimal complications.¹¹

The aim of this study is to assess the efficacy of Transcatheter Closure of the Patent Ductus Arteriosus Using the Amplatzer Duct Occluder

at tertiary cardiac institute with special focus on success rate and complications.

METHODOLOGY

It was a descriptive retrospective case series study conducted at Paediatric Cardiology Department of Faisalabad Institute of Cardiology (FIC) Faisalabad. Seventy four consecutive patients of isolated PDA who underwent cardiac catheterization in an attempt to close the PDA by trans-catheter approach using ADO device (AGA Medical Corporation, Golden Valley, MN) from May 2012 to July 2017 were enrolled in the study. Approval of hospital's ethics committee was obtained and there was no conflict of interest. The patients of PDA having associated multiple structural cardiac anomalies, those needing Coil occlusion or having irreversible pulmonary hypertension were excluded from study. The data of all patients including physical examination, X-ray chest and trans-thoracic echocardiography findings including color flow mapping was retrieved from dedicated hospital data base and evaluated.

The demographic profile including name, age, gender and weight of the patients were noted. The procedural notes as well as the angiograms were revaluated and all the procedural parameters like venous and arterial approach; site, size (including narrowest point and ampullae) and type of the defect according to krichenko classification (A, B, C, D, E), pulmonary hypertension and its grade (i.e. mild, moderate and severe), sizes of delivery system and ADO devices used, amount of nonionic dye, procedural time and flouro time were noted. Post procedural parameters such as percentage of patients having complete occlusion of duct, foaming through the device or residual leak from upper or lower end of device and pull back pressures across ascending and descending aorta, was noted. Presence of complications e.g. arrhythmia, device embolization or malposition and vitality of femoral pulsation was also noted. The 2nd Post procedural day Echocardiography was evaluated for residual leak, Left pulmonary artery obstruction, protrusion of retention skirt of device in descending aorta and Coarctation of aorta.

Procedure Protocol

After taking informed written consent, the patients were taken to the catheterization laboratory. The procedure was performed under local anesthesia by using 2% lignocaine subcutaneously or conscious sedation using injection midazolam 0.05-0.1mg per kg or injection ketamine 0.2-0.8mg per kg along with subcutaneous injection lignocaine when and where needed. In all cases both femoral vein and artery were accessed percutaneously. Intravenous Injection heparin was given after taking femoral artery line in a dose of 70units per kg. Aortogram done in full lateral position (90°) and if needed in RAO position (30°) by using a pigtail catheter. An end-hole catheter (Multipurpose catheter) through femoral venous sheath was passed through the PDA from the pulmonary artery side into the descending aorta and exchanged for a delivery sheath, over an exchange length super stiff guide wire. An Appropriate-sized Amplatzer duct Occluder device (the pulmonary end diameter to be around 2 mm larger than the narrowest diameter of the duct) was advanced through the delivery sheath into the descending aorta. The retention skirt was deployed in the descending aorta and then whole assembly including the sheath and the retention disk were pulled back into the ampulla of the duct. The rest of the device including waist and pulmonary end were released subsequently in the duct and in pulmonary artery respectively by tracking back the delivery sheath while keeping delivery cable in a fixed position. Check aortogram was done to confirm the position of device to look for any residual leak. Finally the device was released after ascertaining the correct position. Post procedure aortogram was also done to look for final position of the device. The success of the procedure was defined as patient leaving the catheterization laboratory with a device in situ across duct with no residual shunt except foaming through the device in the post device release final aortogram. The patients were shifted in the ICU for post Post-procedural care including palpation of lower limb pulses especially dorsal pedis and posterior tibial artery, any prolonged bleeding from puncture site, intravenous fluids, vital signs, general examination and echocardiography. Single intravenous dose of Ceftriaxone (50 - 75

mg/kg) was given.

**RESULTS
DEMOGRAPHICS**

A total of 74 patients underwent cardiac catheterization to close the duct. Two patients were excluded from the study due to non-suitable anatomy of the PDA after initial aortogram. Out of 72 device attempted patients 75% were female (n=54) while 25% were male (n=18). The mean age was 11.93 years ranging from 9 months to 46 Years and mean weight was 30.65 kg ranging from 7kg to 78 kg.

PROCEDURAL PARAMETERS

On Echo 54.17% patients were having large PDA (n=39), 38.89 % were of moderate size PDA (n=28) and 6.94% were having small size PDA (n=5). The procedure was carried out under local anesthesia in 84.72 % patients (n=61) while 15.28% (n=11) cases were done in conscious sedation. After initial aortogram, out of 72 cases of PDA, 32 were of moderate size (44.44 %) and 32 were of large size (44.44%) while 8 patients were having small size PDA (11.11%). Per catheter Pulmonary artery (PA) pressure was recorded which showed severe PH in 1 patient (1.39%), moderate PH in 12.50% patients (n=9) and mild PH in 20.83 patients (n=15) while majority had no PH (n=47, 65.28%). Most of the PDA on descending aortogram proved to be Type A (n=70, 97.22%) while only 2.78% cases were of Type B PDA (n=2). Majority of patients had narrowest point measured between 3 to 6 mm (n=56) while a few had narrowest point measurement between 7 to 9 mm (n=14mm) and only two patients had PDA size of 2mm or less than 2mm. In majority of patients the ampulla ranged between 9mm to 20mm (n=61mm) while a few had either less than 9 mm (n=5) or more than 20mm (n=6). PDA size after putting delivery system proved to be small in 11.11% (n=8) cases, moderate in 44.44% cases (n=32) while large size in 44.44 % (n=32) cases. As regard delivery system used, 6 Fr delivery stem was used in 5 cases (6.94%), 7Fr delivery system used in 34 cases (47.22%), in 8 cases 9Fr delivery system was used (11.11%) while in 25 cases 8 Fr delivery system was used (34.72%) as described in Figure 1. As far as devices are concerned ,

8x6 device was used in 23 patients, 10x8 device was second most often used device(n=19) and 12x10 was third most often used device (n=14) as described in Table-I.

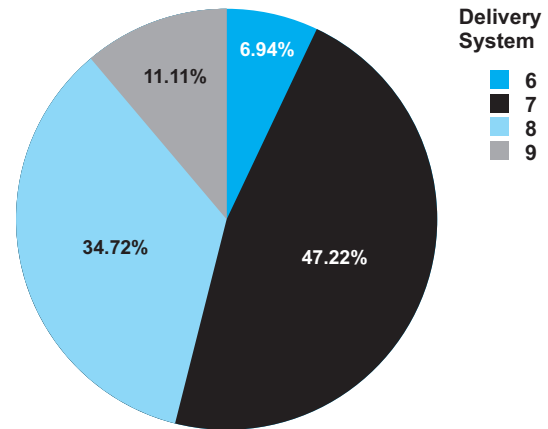


Fig-1. Different sizes of delivery system used with percentages

Serial #	Device size	Number of cases	Percentage (%) of total cases
1	5/4	2	2.78
2	6/4	6	8.33
3	8/6	23	31.94
4	10/8	19	26.39
5	12/10	14	19.44
6	14/12	5	6.94
7	16/14	3	4.17

Table-I. Different device sizes with percent

POST PROCEDURE CHARACTERISTICS AND COMPLICATION

The total procedure time in majority of cases (n=54) was less than 40minutes while rest of cases completed in more than 40minutes (n=18) with mean procedure time from needle prick for vessel access to final angiogram after releasing device was 34.38minutes. Mean fluoroscopy time was 6 min ranging from 4 min lowest and 10 min maximum with majority of cases completed between 5 to 8 min fluoroscopy times. Most of the cases (45) were completed with less than 96 ml of dye while rests were completed with more than 96 ml of contrast. Only two patients (2.78%) developed transient self-limiting SVT while trying to enter Right ventricle (RV) and main pulmonary artery (MPA) from right atrium (RA)(FIG-2). Post release device stability was 100% and no device

embolized (FIG-3). Although upper end of retention skirt protruded in descending aorta in 12 patients (8.45%) but there was no pull back gradient across the protrusion of the disc in descending aorta before or after release of device (FIG-3). Final aortogram after release of device showed no residual leak / shunt from above or below the waist of device (n=72) while foaming through the device in 75% of cases(FIG-3). After removal of arterial sheath lower limb arterial pulses were present in most of the cases 94.44% (n=68) while pulses were weak in one patient (1.39%) and absent in 3 cases (4.17%) (FIG-3). Out of these 4 cases 2 patients responded to heparin bolus/infusion while rest of the two patients responded within one hour to streptokinase infusion used after failure of heparin infusion for 6 hours. On next day of procedure all the patients had palpable lower limb pulses. No patient had prolonged bleeding or hematoma from puncture site after removal of femoral vessel sheaths. Before discharge echocardiography showed not a single case of residual leak (FIG-2), LPA obstruction, Coarctation of aorta or pericardial effusion (FIG-3).

DISCUSSION

Device closure of PDA in the study center started in 2012. Since then, this procedure has been the preferred mode of treatment in the patients with isolated PDA at FIC. This study was designed to analyze the safety, efficacy, and immediate results of percutaneous closure of PDA. Seventy four consecutive patients were taken to catheterization laboratory with an intention to treat from May 2012 to July 2017. In 2 patients the procedure was abandoned after initial aortogram due to non-favorable anatomy. First patient was an 18 years boy having long tubular duct and the other one was a 5 year old child having tiny tortuous PDA needing coil occlusion and so device occlusion was not attempted. Considering the number of attempted device closure cases, the success rate was 100 % (72/72) while one may argue about the two cases out of 74 cases where device not attempted as a technical failure so the overall success rate was 97.3% (72/74) without any significant adverse events.

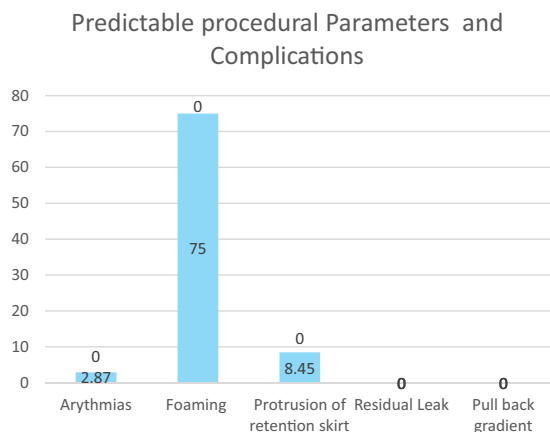


Fig-2. Predictable procedural Parameters and Complications (Percentages)

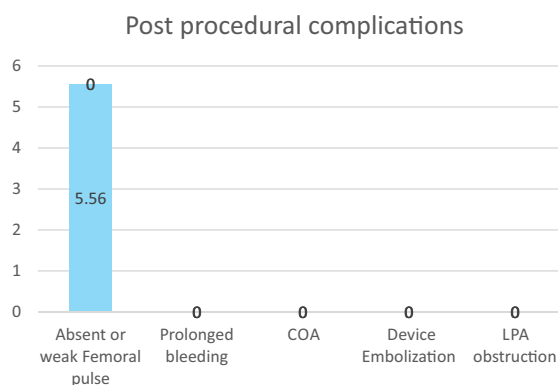


Fig-3. Post Procedural Complications (Percentages)

The results of the study are in accordance to Mehboob et al¹² who reported success rate of 98%, Howaida G et al¹³ and Brunetti et al³ where procedural success rate was 97-99% and 99.44% respectively. Possible reason for high success rate is that we were very selective in patient's selection and the technique is more than 20 years old now since its advent.

PDA is more common in female population and in our study 75% patients were female. Atiq M¹⁴ reported female to male ratio in catheter based interventions for PDA as 2:1. As regard the age of the patients, it ranged from 9 months to 46 years with mean age 11.93 years. The reason for high mean age is that FIC is an adult cardiology set up with limited facility of cardiac care for infants. Surgical ligation of duct in adolescent and grown up patients is always a challenge due to friability and or calcifications, atherosclerosis and

aneurysm formation.¹⁵ There were 32 patients above 12 years of age and the all had successful device deployment without any immediate complication. The results are comparable to Sadiq M et al¹⁶ where 91% success rate was achieved in adults and also similar results shown in Hong TE et al¹⁷ where device was successfully deployed in 36 adult patients with PDA out of 37 attempted patients. The mean weight of patients in our study was 30.65Kg ranging from 7 kg to 76Kg.

Common reported complications of Transcatheter closure of PDA are residual shunt, left pulmonary artery (LPA) obstruction, protrusion of the device into the descending aorta, and embolization of the device.^{14,18,19} Mostafa et al²⁰ in his study reported post device release descending aortogram showing residual shunt including foaming through the wire mesh of the device in 171 patients (70.4%), small residual shunt in 32 patients (13%) and moderate residual shunt in 3 patient (1.2%) patients. In our study there was no residual leak / shunt from above or below the waist of device while foaming through the wire mesh of the device in 75% of cases which is a normal phenomenon in post release check aortogram.

Post device deployment LPA stenosis is a rare complication and according to different studies its rate varies between 0-12%.^{14,21,22} There was not a single case of LPA or descending aortic obstruction in our study which is comparable to Ahsan M. Beg et al²³ who also reported zero case of LPA obstruction out of 61 patients. Device embolization is a complication that occurs after its release and the embolized device can be retrieved by snaring in the catheterization laboratory or in surgical theatre. None of patient had device embolization/dislodgment in our study which is comparable to study conducted by Faranak B et al²⁴ where no device embolized in attempted 33 patients while Mehboob S et al¹² reported 1.2% cases having device dislodgment. Arterial access in children is associated with a high rate of different complications including arterial disruption, or acute occlusion which may be limb-threatening as reported by Balaguru D.²⁵ In a study

conducted by Kulkarni S²⁶ reported Incidence of arterial occlusion was higher in patients weighing less than 10 kg (16%) as compared with patients weighing more than 10 kg (5.5%) {P = 0.031}. In our study only 3 patients lost lower limb arterial pulse (4.17%) and one patient had a weak pulse (1.39%) which settled with bolus of injection heparin and injection streptokinase within 8 hours of arterial sheath removal. Post device closure incidence of loss of arterial pulse in our study is far less than available data from other centers of this region.^{12,23} Two patients had transient short run of SVT which was self-limiting while attempting to take catheter from Right atrium to Right Ventricle to pulmonary artery. There was not a single case of prolonged bleeding or hematoma formation. Echocardiography was done in every patient next morning which showed not a single case of residual leak across occluded duct, any LPA obstruction, Coarctation of aorta or pericardial effusion. All the patients were discharged within 24 hours of procedure

CONCLUSION

Based on results of our study data we can conclude that Device closure of PDA using Amplatzer duct occluder is a preferable mode of treatment in moderate to large size PDA which can be carried out with high efficacy and safety with extremely low incidence of complications.

Copyright© 20 Oct, 2018.




REFERENCES

1. Rao P, Wagman A, Chen S. **Coil occlusion of patent ductus arteriosus associated with right aortic arch.** Catheterization and Cardiovascular Interventions. 2001;52(1):79-82.
2. Krichenko A, Benson L, Burrows P, Mões C, McLaughlin P, Freedom R. **Angiographic classification of the isolated, persistently patent ductus arteriosus and implications for percutaneous catheter occlusion.** The American Journal of Cardiology. 1989;63(12):877-880.
3. Brunetti MA, Ringel R, Owada C, Coulson J, Jennings JM, Hoyer MH, et al. **Percutaneous closure of patent ductus arteriosus: A multiinstitutional registry comparing multiple devices.** Catheterization and Cardiovascular Interventions. 2010;76(5):696-702.
4. Amanullah MM, Siddiqui MT, Khan MZ, Atiq MA.

- Surgical Rescue of Embolized Amplatzer Devices.** *Journal of Cardiac Surgery.* 2011Nov;26(3):254–8.
5. Shen XQ, Zhou SH, Fang ZF, Hu XQ, Qi SS, Chen GR, et al. **Transcatheter closure for patent ductus arteriosus in children.** *Zhong Nan Da Xue Xue Bao Yi Xue Ban* 2006; 31:782-5.
 6. Porstmann W, Wierry L, Warnke H. **Closure of PDA without thoracotomy.** *Ger Med Mon* 1967; 12: 259–61.
 7. Hosking MC, Benson LN, Musewe N, Dyck JD, Freedom RM. **Transcatheter occlusion of the persistently patent ductus arteriosus. Forty-month follow-up and prevalence of residual shunting.** *Circulation.* 1991Jan;84(6):2313–7.
 8. Latson LA, Hofschire PJ, Kugler JD, Cheatham JP, Gumbiner CH, Danford DA. **Transcatheter closure of patent ductus arteriosus in pediatric patients.** *The Journal of Pediatrics.* 1989;115(4):549–53..
 9. Rao PS, Ende DJ, Wilson AD, et al. **Follow-up results of transcatheter occlusion of atrial septal defects with buttoned device.** *Can J Cardiol* 1995; 11:695.
 10. Grifka R, Vincent J, Nihill M, Ing F, Mullins C. **Transcatheter Patent Ductus Arteriosus Closure in an Infant Using the Gianturco-Grifka Vascular Occlusion Device.** *The American Journal of Cardiology.* 1996;78(6):721-723.
 11. Boehm W, Emmel M, Sreeram N. The Amplatzer duct occluder for PDA closure: indications, technique of implantation and clinical outcome. *Images in Paediatric Cardiology.* 2007;9(2):16-26.
 12. Sultan M, Ullah M, Sadiq N, Akhtar K, Akbar H. **Transcatheter Device Closure of Patent Ductus Arteriosus.** *J Coll Physicians Surg Pak* 2014; 24: 710-13.
 13. El-Said H, Bratincsak A, Foerster S, Murphy J, Vincent J, Holzer R et al. **Safety of Percutaneous Patent Ductus Arteriosus Closure: An Unselected Multicenter Population Experience.** *Journal of the American Heart Association.* 2013;2(6):e000424-e000424.
 14. Atiq M, Aslam N, Kazmi KA. **Transcatheter closure of small-to large patent ductus arteriosus with different devices: queries and challenges.** *J Invasive Cardiol.* 2007;19:295–8.
 15. Fisher RG, Moodie DS, Sterba R, et al. **Patent ductus arteriosus in adults—long-term follow-up: Nonsurgical versus surgical treatment.** *J Am Coll Cardiol* 1986;8:280–284.
 16. Al-Hamash S, Khalid Z, Wahab H, Nasser I. **Transcatheter closure of patent ductus arteriosus using ADO device: Retrospective study of 149 patients.** *Heart Views.* 2012;13(1):1.
 17. Hong TE, Hellenbrand WE, Hijazi ZM, Amplatzer Investigators. **Transcatheter closure of patent ductus arteriosus in adults using the Amplatzer duct occluder: initial results and follow-up.** *Indian Heart J.* 2002 Jul-Aug;54(4) 384-389. PMID: 12462665.
 18. Ewert P. **Challenges encountered during closure of patent ductus arteriosus.** *Pediatr Cardiol.* 2005;26:224–9.
 19. Rutledge J. **Transcatheter closure of the patent ductus arteriosus.** *Expert Review of Cardiovascular Therapy.* 2003;1(3):411-419.
 20. Behjati-Ardakani M, Behjati-Ardakani MA, Hadadzadeh M, Moshtaghion SH, Sarebanhassanabadi M. **Experience with percutaneous closure of ductus arteriosus using the Amplatzer duct occluder in 243 consecutive patients and long-term results—A single centre study.** *Nigerian Medical Journal : Journal of the Nigeria Medical Association.* 2014;55(5):394-398.
 21. Wang JK, Wu MH, Hwang JJ, Chiang FT, Lin MT, Lue HC. **Transcatheter closure of moderate to large patent ductus arteriosus with Amplatzer duct occluder.** *Catheter Cardiovasc Interv* 2007; 69:572-8.
 22. Fernández Ruiz A, del Cerro Marín MJ, Rubio Vidal D, Castro Gussoni MC, Moreno Granados F. **Transcatheter closure of patent ductus arteriosus using the Amplatzer duct occluder: Initial results and mid-term follow-up.** *Rev Esp Cardiol.* 2002; 55:1057–62.
 23. Beg AM, Younas M, Chaudary AT. **Early Results of Transcatheter Closure of Patent Ductus Arteriosus: Retrospective Study of 61 Patients.** *A King Edward Med Uni.* 2013;19(1).
 24. Behnaz F, Chegini A, Rafieyian S, Rasouli M. **Complications of Transcatheter Closure in Patent Ductus Arteriosus Patients,** *Int Cardio Res J.* 2017 ;11(4):e11300.
 25. Balaguru D1, Dilawar M, Ruff P, Radtke WA. **Early and late results of thrombolytic therapy using tissue-type plasminogen activator to restore arterial pulse after cardiac catheterization in infants and small children.** *Am J Cardiol.* 2003 Apr 1;91(7):908-10.
 26. Kulkarni S, Naidu R. **Vascular ultrasound imaging to study immediate postcatheterization vascular complications in children.** *Catheter Cardiovasc Interv.* 2006 Sep;68(3):450-5.

“
*Be sure to taste your words
 before you spit them out.*
 – Unknown –”

AUTHORSHIP AND CONTRIBUTION DECLARATION

Sr. #	Author-s Full Name	Contribution to the paper	Author=s Signature
1	Abdul Razzaq Mughal	Principal investigator, did all cases of device closure of PDA collected data and wrote the article.	
2	Ali Farahe	Helped in data analysis and writing of results.	
3	Masood Sadiq	Supervised first 20 cases of device closure of PDA at FIC.	
4	Rubina Tousif	Helped in collection of data.	