



ORIGINAL ARTICLE

Effectiveness of empirical angioembolization for non-variceal Upper GI Bleed in comparison to conservative management.

Abdul Raouf¹, Ammar Afzal², Amna Rehan³, Abid Ali⁴, Anaab Gul⁵, Joshua Bhatti⁶, Muhammad Azeemuddin⁷

Article Citation: Raouf A, Afzal A, Rehan A, Ali A, Gula A, Bhatti J, Azeemuddin M. Effectiveness of empirical angioembolization for non-variceal Upper GI Bleed in comparison to conservative management. Professional Med J 2022; 29(8):1191-1197.
<https://doi.org/10.29309/TPMJ/2022.29.08.7189>

ABSTRACT... Objective: To share experience and present our data of past 15 years on endoscopy guided empiric embolization of GDA and compare it with the results of conservative management. **Study Design:** Retrospective study **Setting:** Agha Khan University Hospital Karachi. **Period:** January 2001 till October 2017. **Material & Methods:** 70 patients were selected who presented with upper GI bleed followed by conventional angiography. The data was collected on clinical presentation, patient demographics, embolization procedures, and postembolization outcomes. **Results:** A total of 101 patients were included in the study. 79 were male and 22 were female. The median age at presentation was 54 years (range 15-96 years). All the patients presented with upper gastrointestinal bleeding. All the patients underwent fluoroscopy guided angiography. In 30 patients the angiography was able to locate the bleeding source. In 44 patients the bleeding source could not be identified however empiric embolization was performed. In 27 patients the angiography was negative and embolization was not performed. The overall clinical success in the empirically embolized group is 77.2 %. 27 patients were conservatively managed after negative angiography. The overall clinical success in the empirically embolized group is 77.2 %. However in the patients who were conservatively managed the clinical success was only 48.1 %. **Conclusion:** This study concluded that it safe and effective to empirically embolize the GDA in patients refractory to initial endoscopic treatment for non variceal upper GI bleed.

Key words: Conservative Management, Endoscopy-directed Empiric Embolization, Upper Gastrointestinal Tract Bleed.

INTRODUCTION

Gastrointestinal bleeding is a life threatening condition. Most common presenting complaints include hematemesis, melena and hematochezia.¹ Gastrointestinal bleed can be subdivided into Upper gastrointestinal bleed or Lower gastrointestinal bleed based on the site of bleeding with in the gastrointestinal track. The reported incidence of upper GI bleeding is 100 cases per 100,000 persons per year. The upper GI tract bleed is about 4 times as common as bleed from lower GI tract and is therefore a major cause of morbidity and mortality. Mortality rates from upper GI bleeding range from 6 to 10%.²

Management of upper GI tract bleed remains a challenge. It requires a multidisciplinary

team including a gastroenterologist skilled in endoscopy, intensive care specialist, upper GI surgeon, and interventional radiologist.³

Upper GI endoscopy is first line of management of upper GI bleed. If endoscopy is not able to identify or control the GI bleed second line of management is angiography and transarterial embolization. For the acute non-variceal upper gastrointestinal (GI) bleeding gastric and duodenal ulcers remain a challenging presentation with significant morbidity and mortality rates. Using selective catheter angiography for the detection of GI bleeding, bleeding rates as low as 0.5 mL/min can be detected.⁴ However, intermittent nature of bleeding in some patients can result in a false-negative angiographic study.⁵

1. MBBS, FCPS, FRCR, Senior Registrar Radiology, Allied Hospital, Faisalabad.
2. MBBS, FCPS, Consultant Radiologist, Shifa international Hospital, Faisalabad.
3. MBBS, FCPS, Assistant Professor Radiology, Allied Hospital, Faisalabad.
4. MBBS, FCPS, Assistant Professor Radiology, Bahawalpur Victoria Hospital.
5. MBBS, FCPS, Women Medical Officer Radiology, Allied Hospital, Faisalabad.
6. MBBS, FCPS, Medical Officer Radiology, Allied Hospital, Faisalabad.
7. MBBS, MCPS, FCPS, Professor Radiology, Aga Khan University, Karachi.

Correspondence Address:
Dr. Amna Rehan
Assistant Professor Radiology
Allied Hospital, Faisalabad.
amna.rehan11@yahoo.com

Article received on: 29/04/2022
Accepted for publication: 01/07/2022

Empiric or blind embolization remains controversial. As massive bleeding is often intermittent, a policy to embolize on the basis of endoscopic findings has been adopted in situations where no angiographic extravasation is demonstrated.⁶ Considering the findings from the literature and our own experience, we believe that blind embolization is appropriate. In our institute this approach is systematically used in order to minimize recurrent bleeding. Several previous studies identified that in the absence of contrast extravasation empiric embolization based on endoscopic findings is helpful to achieve bleeding control irrespective of the fact that whether the angiogram identified bleeding site. Current literature shows enough evidence in favor of endoscopy-directed empiric embolization for angiographically negative upper GI bleeding.

We want to share our experience and present our data of past 15 years on endoscopy guided empiric embolization of GDA and compare it with the results of conservative management.

MATERIAL & METHODS

It was a retrospective study performed at a single tertiary care hospital. We reviewed the medical records of all the patients who presented with upper GI bleed and underwent conventional angiography in our department. We included all patients from January 2001 till October 2017. Upper gastrointestinal bleed was defined as when the hemorrhagic source was proximal to ligament of teritz.⁷ Estimation of the bleeding site prior to the angiography was made either by clinical presentation or the endoscopy findings. All those patients who had variceal bleed were excluded.

70 patients were selected who presented with upper GI bleed followed by conventional angiography. The data was collected on clinical presentation, patient demographics, embolization procedures, and postembolization outcomes.

Technique of endovascular procedure

Right femoral artery approach was selected in majority of the cases. After placing 4 Fr femoral access sheath 4 Fr endovascular catheter was used for cannulation of coeliac and mesenteric

arteries. Angiography was performed in multiple projections to look for the source of bleeding. When the source was identified super-selective catheterization was performed with microcatheter if needed. Embolization was performed as selectively as possible using metallic endovascular coils and polyvinyl alcohol particles (PVA). These embolizing materials were used either singly or in combination. The size of the coils used ranged from 2mm to 6 mm. The size of the PVA particles used ranged from 355– 500 μm to 500–710 μm . (Fig.)

The angiography was labelled as positive for GI bleed when there was active contrast extravasation or when there was one or combination of indirect signs of abnormal bleeding vessel. These indirect signs included aneurysm/pseudoaneurysm, or vascular cutoff in the suspicious area.⁸

Empirical embolization was performed in those patients who did not show the above mentioned signs of active bleeding however there was still suspicion that the source of bleeding might be somewhere from coeliac or mesenteric artery branches. This suspicion was based on clinical, endoscopic or angiography findings (i.e.; vessel irregularity or increased vascularity in the suspicious area).

Conservative management was defined as medical management without endoscopic or vascular intervention. When the angiography was negative for GI bleed the decision for conservative management was taken by the primary team assuming the amount of bleeding was slight and the circulatory condition stable

Follow Up:

Follow-up information was gathered for all patients. This information was collected by reviewing the electronic medical records of patients.

Successful angio-embolization was defined as complete angiographic blockage of target vessels.⁹ Re-bleeding was defined as repeat episode of bleed or hemoglobin drop within 30 days, or failure of effectiveness of conservative management.

Statistical Analysis

For analysis of non-parametric data Fisher's test was used. All the findings with a p value of < 0.05 were considered significant.

RESULTS

Patient Demographics

A total of 101 patients were included in the study from January 2003 till 2017. 79 were male and 22 were female. The median age at presentation was 54 years (range 15-96 years). All the patients presented with upper gastrointestinal bleeding. The main symptoms were hematemesis, hypotension, and anemia requiring blood transfusions. 37 (36.6%) patients were hemodynamically unstable immediately before the catheter angiography, defined as defined as systolic blood pressure < 100 mm Hg, tachycardia >100 beats/min, Low Hb requiring blood transfusion at least 2 units of red blood cells during 24 hours.¹⁰

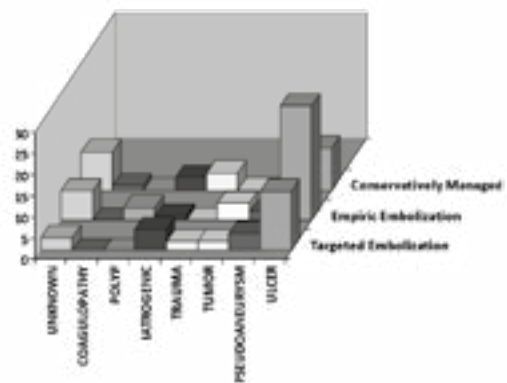
Pre-angiography Workup

80 (79.2%) patients underwent upper GI endoscopy for evaluation of the haemorrhagic site. In 42 patients the site of bleeding was identified however in 38 patients the endoscopy was indeterminate. In 35 patients the CT angiography (CTA) was performed to locate the bleeding site. Only in 12 patients the CTA was able to pick up the bleeding focus however in 23 patients the CTA was negative.

The major cause of bleeding was duodenal ulcer 51 (50.5 %). Other causes included pseudoaneurysm of the gastroduodenal artery (GDA) or its branches 6 (5.9 %), tumor 6 (5.9 %), iatrogenic 9 (8.9 %), trauma 6 (5.9 %) and polyp 3 (2.9 %). In rest of the patients 19 (18.8 %) the cause of bleeding could not be ascertained either by CTA or endoscopy.

Angiography

All the patients underwent fluoroscopy guided angiography. In 30 patients the angiography was able to locate the bleeding source. In 44 patients the bleeding source could not be identified however empiric embolization was performed. In 27 patients the angiography was negative and embolization was not performed after discussion with the primary team and was based on clinical condition of the patient, coagulopathy, episodes and amount of bleeding and consideration of the risks of empiric embolization.



Graph

| | Targeted Embolization (n = 30) | Empiric Embolization (n = 44) | Conservatively Managed (n = 27) | Total (n = 101) |
|-------------------------------|--------------------------------|-------------------------------|---------------------------------|-----------------|
| Gender (M:F) | 24:6 | 33:11 | 22:5 | 79:22 |
| Age (in years) Median (range) | 55.5 (18 - 96) | 53 (20 - 90) | 54 (15 - 79) | 54 (15-96) |
| Endoscopy | 23 (76.6 %) | 38 (86.3 %) | 19 (70.3 %) | 80 (79.2 %) |
| CT Angiography Positive | 8 (26.6 %) | 2 (4.5 %) | 2 (7.4 %) | 12 (11.8 %) |
| Coagulopathy | 1 (3.3 %) | 5 (11.3 %) | 2 (7.4 %) | 8 (7.9 %) |
| Hemodynamic Instability | 16 (53.3 %) | 15 (34 %) | 6 (22.2 %) | 37 (36.6 %) |
| Mortality | 5 (16.6 %) | 6 (13.6 %) | 2 (7.4 %) | 13 (12.8 %) |
| Reintervention | 6 (20 %) | 3 (6.8 %) | 6 (22.2 %) | 15 (14.8 %) |

Table-I. Demographics and clinical characteristics summary

| | Targeted Embolization (n = 30) | Empiric Embolization (n = 44) | Conservatively Managed (n = 27) | Total (n = 101) |
|----------------|--------------------------------|-------------------------------|---------------------------------|-----------------|
| Ulcer | 14 (46.7 %) | 27 (61.3 %) | 10 (37 %) | 51 (50.5 %) |
| Pseudoaneurysm | 4 (13.3 %) | 2 (4.5 %) | 0 | 6 (5.9 %) |
| Tumor | 2 (6.6 %) | 4 (9 %) | 0 | 6 (5.9 %) |
| Trauma | 2 (6.6 %) | 0 | 4 (14.8 %) | 6 (5.9 %) |
| Iatrogenic | 5 (16.6 %) | 1 (2.2 %) | 3 (11.1 %) | 9 (8.9 %) |
| Polyp | 0 | 3 (6.8 %) | 0 | 3 (2.9 %) |
| Coagulopathy | 0 | 0 | 1 (3.7 %) | 1 (0.9 %) |
| Unknown | 3 (10 %) | 7 (15.9 %) | 9 (33.3 %) | 19 (18.8 %) |

Table-II. Causes of Upper GI haemorrhage

| | Rebleed | Reintervention | Mortality | Clinical Success |
|---------------------------------|-------------|----------------|------------|------------------|
| Targeted Embolization (n = 30) | 8 (26.6 %) | 6 (20 %) | 5 (16.6 %) | 19 (63.3 %) |
| Empiric Embolization (n = 44) | 8 (18.1 %) | 3 (6.8 %) | 6 (13.6 %) | 34 (77.2 %) |
| Conservatively Managed (n = 27) | 13 (48.1 %) | 6 (22.2 %) | 2 (7.4 %) | 13 (48.1 %) |

Table-III. Clinical outcome in different groups.

Targeted Embolization Group

In 30 patients the site of bleeding was identified on angiography and underwent targeted embolization. The bleeding source was identified as active extravasation (n=12), pseudoaneurysm (n=9), abrupt arterial blockage (n=9). Technical success was achieved in all the patients 100 %. 8 patients (26.6 %) had one or episode of re-bleeding within 30 days of initial embolization. 6 (20%) patients underwent re-intervention either relook endoscopy or re-angiography. Out of all the patients in this group 5 (16.6 %) expired, 2 due to recurrent episode of bleed and 3 from other comorbidities. Clinical success achieved in 19 patients (63.3 %).

Empiric Embolization Group

44 patients underwent empirical embolization after the angiography was negative. In this group 34 patients had undergone upper GI endoscopy of which the 20 showed site of bleeding. Endoscopic treatment was tried in 18 patients with variable temporary success. In 2 patients the endoscopic treatment was not done because of technical reasons. 10 patients underwent CTA and none showed any positive bleeder site. The embolization site was GDA and/or its branches. 37 patients were hemodynamically unstable just before the angiography.

Out of total 44 patients recurrent haemorrhage occurred only in 8 (18.1 %) patients. Re intervention was done in 3 (6.8 %) patients either in the form of re look endoscopy, re-angiography or surgery. In this group 6 patients (13.6 %) died, 2 from the recurrent episodes of bleeding and 4 from other associated comorbidities.

Technical success was achieved in all the patients 100 %. Clinical success was achieved in 34 (77.2 %) patients.

Conservatively Managed Group

27 patients were conservatively managed after negative angiography. 16 of them had prior endoscopy of which 13 were given treatment after identifying the bleeder. In rest of the 3 the bleeding source was not identified.

Recurrent haemorrhage occurred in 13 (48.1 %) patients within 30 days of angiography. Reintervention with Endoscopy, angiography or surgery was done in 6 (22.2 %) patients. 2 patients (7.4%) expired due to recurrent episodes of bleeding. The desired clinical outcome was achieved in 13 (48.1 %) of the cases.

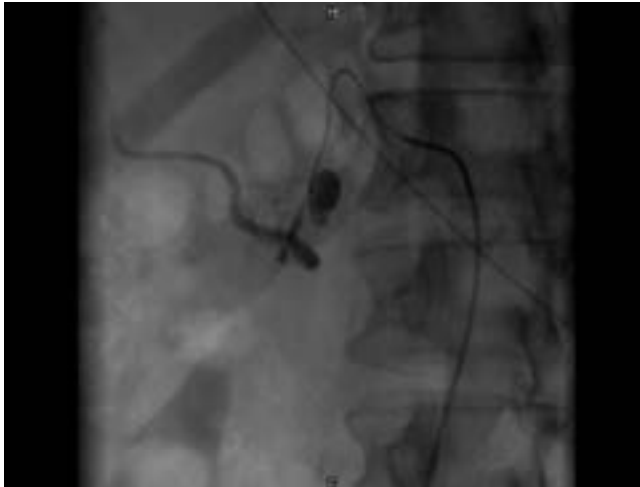

Figure-1a. Angiography image shows GDA pseudoaneurysm.

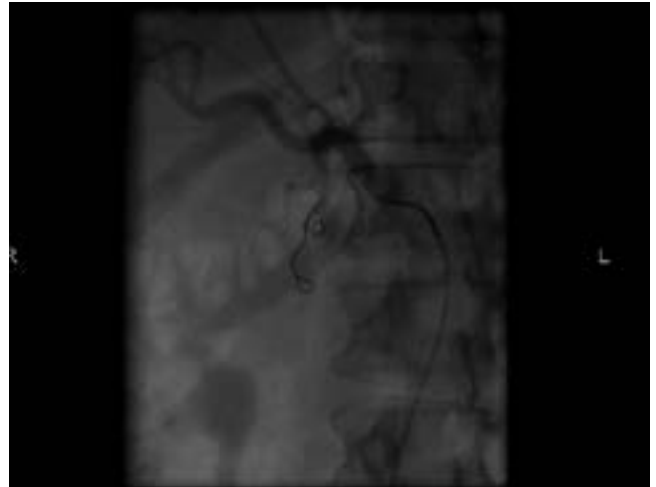


Figure-1b. Post coiling angiographic image with no filling of the pseudoaneurysm

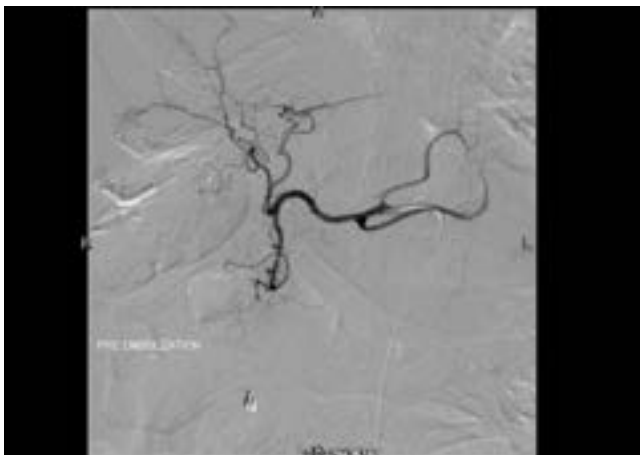

Figure-2a. Digital subtraction angiography image shows no active contrast extravasation

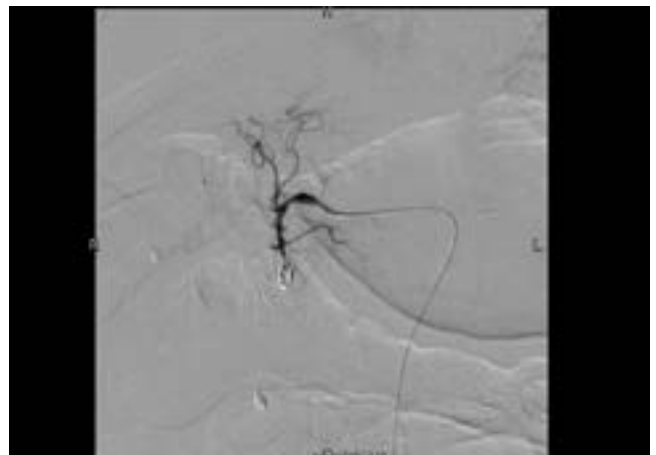


Figure-2b. Empirical coil embolization of the GDA

DISCUSSION

Upper GI bleeding is one of the common cause of morbidity and mortality. It is the one of the commonest cause of emergency faced by the gastroenterologists. Upper GI endoscopy is usually the first line of management in investigation as well as treatment in these patients. But significant number of patients could not be treated either because there is failure to identify the source of bleeding or there is re-bleeding after the treatment. With advent of improved technology and better techniques the endovascular embolization in this subset of patients may play as a next step in the line of management. Conventional angiography not only helps to identify the bleeding focus but also guides angioembolization of the bleeding vessels.

Its role in patients who show active contrast extravasation has been established. However the patients in whom the diagnostic angiography fails to depict the bleeding source, the role of empirical embolization is controversial. Very few studies have been published directly comparing the clinical and technical success between the empirically embolized patients with those who are conservatively managed. And those that have been done have a smaller sample size and are not from the developing world.

In our study we compared the patients who underwent empirical embolization for non variceal upper GI bleed with those who were managed conservatively. The evaluation was done for their clinical outcome in terms of re-bleed.

The overall clinical success in the empirically embolized group is 77.2 % which is comparable to that in the literature which describes clinical success rate of 52–100 %. However in the patients who were conservatively managed the clinical success was only 48.1 %. This shows a statistically significant difference. The technical success was achieved in 100 % of the cases. In some cases there was difficulty in cannulating the coeliac artery however this was overcome by using different catheters.

The rebleeding rate in the empirically embolized group was 18.1 % as compared to that in conservatively managed group 48.1%. The most common cause of the rebleeding mentioned in the literature is inadequate coil packing resulting in continued forward flow in the GDA. The other cause is the retrograde flow through the mesenteric artery arcades via inferior pancreato duodenal arteries. Therefore aim is always to embolize the GDA as distally as possible.⁶ Overall 8 patients suffered rebleeding 3 of them required reintervention either by endoscopy or angioembolization. The reintervention rate (22.2%) in the conservatively managed group was significantly higher in the empirically embolized group. The overall mortality in the empiric group was 13.6% as compared to 7.4 in the conservatively managed group. This difference may be due to the selection of the patient for the conservative management. Mostly those patients are selected for conservative management who are hemodynamically stable.

The major complications documented in literature after angioembolization are duodenal ischemia, stenosis, and pancreatitis with rates from 0.04 to 9 %.¹² In our study there was no clinically evident post treatment complications.

The limitation of our study is the non-randomization of data due to its retrospective nature. Another limitation was that we followed up patients up to 30 days after angioembolization procedure. The events later than 30 days were not taken into account. But as mentioned in the literature the clinical success or failure after embolization are usually evident within 30 days after the

procedure.¹³

Based on the reviewed literature and our own results we think that it safe and effective to empirically embolize the GDA in patients refractory to initial endoscopic treatment for non variceal upper GI bleed. Significant bleeding control was achieved in patients who were empirically embolized as compared to the patients who were conservatively managed. Moreover there was also less re-intervention rate in the empirically embolized group.

Conclusion

This study concluded that it safe and effective to empirically embolize the GDA in patients refractory to initial endoscopic treatment for non variceal upper GI bleed.


Copyright© 01 July, 2022.

REFERENCES

1. Chen ZJ, Freeman ML. **Management of upper gastrointestinal bleeding emergencies: Evidence-based medicine and practical considerations.** World journal of emergency medicine. 2011; 2(1):5.
2. Alema ON, Martin DO, Okello TR. **Endoscopic findings in upper gastrointestinal bleeding patients at Lacor hospital, northern Uganda.** African health sciences. 2012; 12(4):518-21.
3. Barkun AN, Bardou M, Kuipers EJ, Sung J, Hunt RH, Martel M, Sinclair P. **International consensus recommendations on the management of patients with nonvariceal upper gastrointestinal bleeding.** Annals of internal medicine. 2010 Jan 19; 152(2):101-13.
4. Kim BS, Li BT, Engel A, Samra JS, Clarke S, Norton ID, Li AE. **Diagnosis of gastrointestinal bleeding: a practical guide for clinicians.** World journal of gastrointestinal pathophysiology. 2014 Nov 15; 5(4):467.
5. Cherian MP, Mehta P, Kalyanpur TM, Hedgire SS, Narsinghpura KS. **Arterial interventions in gastrointestinal bleeding.** In Seminars in interventional radiology 2009 Sep (Vol. 26, No. 03, pp. 184-196). © Thieme Medical Publishers.

6. Loffroy R, Favelier S, Pottecher P, Estivalet L, Genson PY, Gehin S, Cercueil JP, Krausé D. **Transcatheter arterial embolization for acute nonvariceal upper gastrointestinal bleeding: Indications, techniques and outcomes.** Diagnostic and interventional imaging. 2015 Aug 31; 96(7):731-44.
7. Padia SA, Geisinger MA, Newman JS, Pierce G, Obuchowski NA, Sands MJ. **Effectiveness of coil embolization in angiographically detectable versus non-detectable sources of upper gastrointestinal hemorrhage.** Journal of vascular and interventional radiology. 2009 Apr 30; 20(4):461-6.
8. Shin JH. **Recent update of embolization of upper gastrointestinal tract bleeding.** Korean journal of radiology. 2012 Feb 1; 13(Suppl 1):S31-9.
9. Angle JF, Siddiqi NH, Wallace MJ, Kundu S, Stokes L, Wojak JC, Cardella JF. **Quality improvement guidelines for percutaneous transcatheter embolization: Society of Interventional Radiology Standards of Practice Committee.** Journal of Vascular and Interventional Radiology. 2010 Oct 31; 21(10):1479-86.
10. **San Luis Obispo County EMS Agency ALS Treatment Protocols 2007 [Rev. 11/1/10]**
11. Mirsadraee S, Tirukonda P, Nicholson A, Everett SM, McPherson SJ. **Embolization for non-variceal upper gastrointestinal tract haemorrhage: A systematic review.** Clinical radiology. 2011 Jun 30; 66(6):500-9.
12. Poultsides GA, Kim CJ, Orlando R, Peros G, Hallisey MJ, Vignati PV. **Angiographic embolization for gastroduodenal hemorrhage: Safety, efficacy, and predictors of outcome.** Archives of surgery. 2008 May 1; 143(5):457-61.
13. Dixon S, Chan V, Shrivastava V, Anthony S, Uberoi R, Bratby M. **Is there a role for empiric gastroduodenal artery embolization in the management of patients with active upper GI hemorrhage?.** Cardiovascular and interventional radiology. 2013 Aug 1; 36(4):970-7.

AUTHORSHIP AND CONTRIBUTION DECLARATION

| No. | Author(s) Full Name | Contribution to the paper | Author(s) Signature |
|-----|---------------------|--------------------------------------|---|
| 1 | Abdul Raouf | Literature Writing. |  |
| 2 | Ammar Afzal | Data collection. | |
| 3 | Amna Rehan | Data collection & Literature review. | |
| 4 | Abid Ali | Analysis | |
| 5 | Anaab Gul | Data collection. | |
| 6 | Joshua Bhatti | Data collection. | |
| 7 | Muhammad Azeemuddin | Proof read. | |