



CASE REPORT

Amyand's hernia with perforated acute appendicitis: A rare case report.

Muhammad Zeb¹, Sabir Khan Khattak², Syed Shayan Shah³, Abdul Haseeb⁴, Syed Qasim Ali Shah⁵

Article Citation: Zeb M, Khattak SK, Shah SS, Haseeb A, Shah SQA. Amyand's hernia with perforated acute appendicitis: A rare case report. Professional Med J 2022; 29(9):1444-1447. <https://doi.org/10.29309/TPMJ/2022.29.09.7137>

ABSTRACT... When appendix is found in the inguinal hernia sac whether inflamed or non-inflamed then this type of inguinal hernia is called Amyand's Hernia. It is found mostly on right side in incarcerated inguinal hernia with male gender preponderance. Here we present case of 80-year-old male with incarcerated inguinal hernia and was operated in emergency operation theatre. Intraoperatively type 3 Amyand's hernia was found, operation was converted to midline laparotomy and appendectomy was performed with no mesh placement in inguinal region due pus collection in hernia sac. Amyand's hernia is rare pathology and is found intraoperatively most of the time. It should be kept in mind while operating incarcerated or strangulated inguinal hernia. CT scan may provide clear picture of pathology preoperatively.

Key words: Amyand's Hernia, Acute Appendicitis, Inguinal Hernia.

INTRODUCTION

When an appendix is found in the inguinal hernia sac whether inflamed or non-inflamed then this type of inguinal hernia is called Amyand's Hernia.¹ The incidence of inguinal hernia is 1.2 % in the general population with male gender preponderance and hernia sac contents vary from bowel to ovary to even appendix.² The appendix is found very rare inside the hernia sac of inguinal hernia with the incidence of less than 1% reported by Logan MT in his literature.³ Mortality in cases of AH is quite high with a reported range of 14-30% and the most common factor contributing to it is sepsis caused by the spread of peritoneal inflammation. With better perioperative and postoperative care mortality rates can be reduced.⁴⁻⁵ Due to peculiar clinical signs and symptoms and insufficient radiological features of Amyand's Hernia and often missed in preoperative diagnoses.⁶

We here describe rare case of Amyand's hernia with acute perforated appendicitis and how it was managed intraoperatively.

CASE REPORT

This patient 80 years old came to the emergency department with complaints of pain in right inguinal and scrotal region along with swelling and redness of the right hemi scrotum. According to the patient he was diagnosed with right inguinoscrotal hernia 30 years back, but he didn't opt for surgery during this span of 30 year. According to the patient the swelling was reducible for last 30 year but for the last 5 days it was not reducible. There was also redness and increase in pain for the last 5 days. Pain was progressive in nature and radiates to umbilicus and right iliac fossa. Patient also complaint of on and off history of constipation. There was no previous history of surgery or medical condition. On examination there was swollen, redness and tenderness in the right inguinal and scrotal region. Bowel loop was appreciated in scrotum. It was not reducible and cough impulse was negative. On auscultation bowel sound were normal.

All baseline investigations were normal except WBC was $11 \times 10^9/L$ and raised alkaline phosphatase 459 IU/L. Urine R/E was normal too.

1. MBBS, FCPS-I, TMO 3rd Year General Surgery, HMC, Peshawar.
2. MBBS, FCPS-I, TMO 2nd Year General Surgery, HMC, Peshawar.
3. MBBS, FCPS-I, TMO 1st Year General Surgery, HMC, Peshawar.
4. MBBS, FCPS-I, TMO 1st Year General Surgery, HMC, Peshawar.
5. MBBS, FCPS-I, TMO 1st Year General Surgery, HMC, Peshawar.

Correspondence Address:
Dr. Muhammad Zeb
Department of General Surgery
HMC, Peshawar.
drmzeb@gmail.com

Article received on: 23/05/2022
Accepted for publication: 26/07/2022

Ultrasound showed herniated gut loops in right inguinal canal reaching up to the right hemiscrotum. Herniated gut loops show normal peristaltic movement. Testis appeared normal with normal color doppler flow and are pushed laterally by the hernial contents. Bilateral hydrocele with internal echoes noted. Generalized scrotal wall edema also seen.

Provisional diagnosis of incarcerated inguinoscrotal hernia was made, and patient was put on list for emergency reduction of inguinoscrotal hernia (Figure-1).

Intraoperatively sliding hernia was found containing gut loops extending up to the scrotum. During manipulation at deep inguinal ring pus collections were noted that raised suspicion of some ongoing intraoperative pathology. After draining the pus tip of inflamed appendix was noted at the base of hernia sac. Midline laparotomy incision was given and small bowel loops along with appendix was reduced back to abdomen. Perforated appendix forming localize pus collection and phlegmon was noted (Figure-2). Appendectomy was performed and copious abdominal wash with normal saline was done. Hernia sac was closed with purse string suture. Abdominal and inguinal incision was closed without mesh placement. Patient tolerated the procedure and was discharged after 3 days postoperatively on oral antibiotics and was advised follow up for elective mesh repair of hernia.

DISCUSSION

Among abdominal wall hernia, inguinal hernia is most common type of hernia. Hernial sac in inguinal hernia vary from patient to patient and among peculiar contents are bladder, Meckle's diverticulum but appendix being the content is still rare despite the first case reported by Claudius Amyand in 1735.⁷

Amyand's hernia is commonly found on right side in indirect inguinoscrotal hernia and in male gender.⁷⁻⁸ In our case patient had right sided incarcerated inguinoscrotal hernia too.

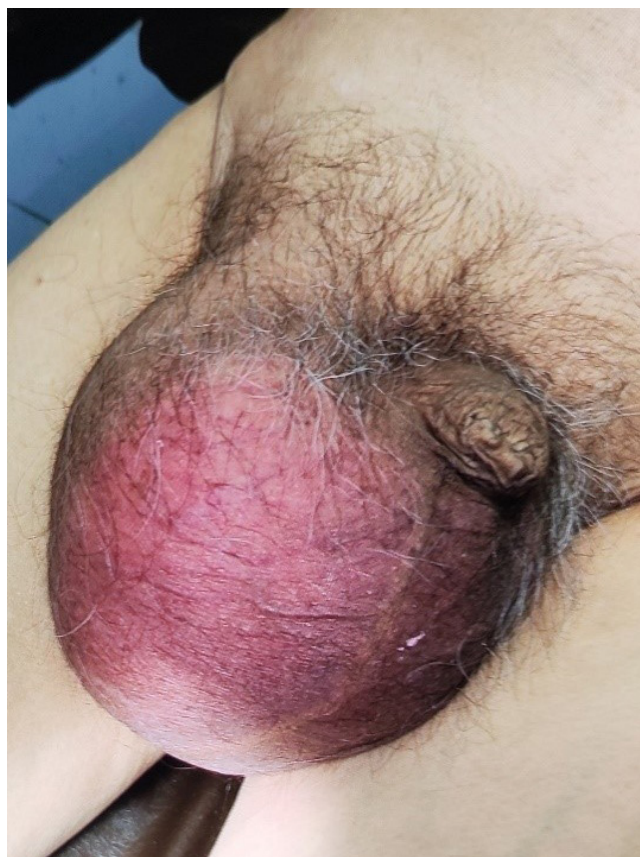

Figure-1. Inguinoscrotal swelling

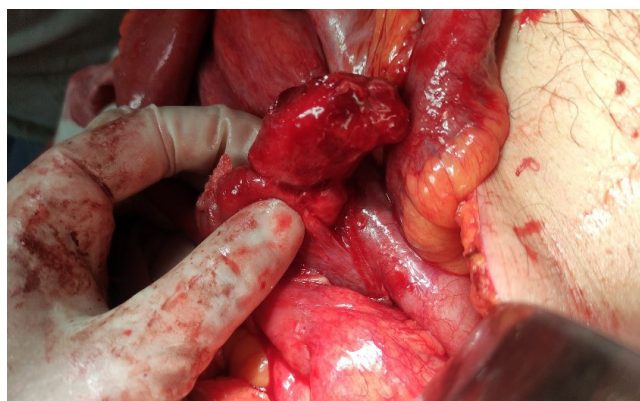


Figure-2. Perforated appendix

Lasanoff and Basson classified Amyand's Hernia (Table-I) into four types based on presence of appendicitis, associated peritoneal inflammation.^{9,10}

The preoperative diagnosis through ultrasound and CT scan has been reported in many literatures but Amyand's hernia is often found intraoperatively as CT scan is rarely done in preoperative investigations of inguinal hernia.⁷

In our case preoperative assessment was done only through ultrasound but it showed no sign of appendix inside the hernia sac and the reason may come down to operative dependent sensitivity of ultrasound.

Classifications	Description	Management
Type 1	Normal appendix in an inguinal hernia	Hernia reduction, mesh placement
Type 2	Acute appendicitis in an inguinal hernia with no abdominal spesis	Appendectomy, primary no prosthetics hernia repair
Type 3	Acute appendicitis in an inguinal hernia with abdominal and abdominal wall sepsis	Laparotomy, appendectomy, and primary no prosthetic hernia repair
Type 4	Acute appendicitis in an inguinal hernia with abdominal concomitant pathology	Same as type 3 plus management of concomitant disease

Table-I. Losanoff and Basson classification of Amyand's hernia

Amyand's Hernia management depends on its type.^{9,10} In most of cases hernia is repaired in same operation when there are no signs of local and systemic inflammations but in presence of inflammation hernia repair is often avoided. When there is obvious signs of peritonitis then midline laparotomy is preferred.^{5,11} In our case it was type 3 Amyand's hernia with peritoneal sepsis and after intraoperative findings through inguinal incision lower midline laparotomy was performed for peritoneal sepsis where copious wash with normal saline was done and appendectomy was performed for perforated appendix and hernia repair was deferred.

CONCLUSION

Amyand's hernia is difficult to diagnose preoperatively because of its low incidence and no specific signs and symptoms and is most commonly found intraoperative. This case highlights the importance of proper intraoperative assessment of incarcerated inguinal hernia and Amyand's hernia should be kept in mind while operating such cases. We also want to emphasize

on value of preoperative CT scan in incarcerated or strangulated inguinal hernia cases as it may enables the possibility of identifying different abdominal contents in hernia sac.





Copyright© 26 July, 2022.

REFERENCES

1. Amyand C: **Of an inguinal rupture, with a pin in the appendix caeci, incrusted with stone, and some observations on wounds in the guts, Philos.** Trans R Soc Lond. 2011; 17(36):329-36. 10.1007/s10029-006-0153-8.
2. Feitosa Cavalcante J, Melo Teixeira Batista H, Cavalcante Pita Neto I, et al.: **Amyand's Hernia with Appendicitis: A Case Report and Integrative Review.** Case Reports in Surgery. 2015; 2015:941039. <https://doi.org/10.1155/2015/941039>
3. Logan MT, Nottingham JM. **Amyand's hernia: A case report of an incarcerated and perforated appendix within an inguinal hernia and review of the literature.** The American Surgeon. 2001; 67(7):628. Retrieved from <https://pubmed.ncbi.nlm.nih.gov/11450774/>
4. D'Alia C, Lo Schiavo M, Tonante A, et al.: **Amyand's hernia: Case report and review of the literature.** Hernia. 2003; 7(2):89-91.10.1007/s10029-002-0098-5
5. Sharma H, Gupta A, Shekhawat NS, Memon B, Memon MA: **Amyand's hernia: a report of 18 consecutive patients over a 15-year period.** Hernia. 2007; 11(1):31-5. 10.1007/s10029-006-0153-8
6. Thomas WE, Vowles KD, Williamson RC: **Appendicitis in external herniae.** Ann R Coll Surg Engl. 1982; 64(2):121-2.
7. Namdev GH, Sanjay P, Varun S, Padnanabh D: **Amyand's hernia: A case report.** International Surgery Journal. 2020; 7(6):2072-4. 10.18203/2349-2902.isj20202440
8. Gurer A, Ozdogan M, Ozlem N, Yildirim A, Kulacoglu H, Aydin R. **Uncommon content in groin hernia sac.** Hernia. 2006; 10(2):152-5. 10.1007/s10029-005-0036-4
9. Losanoff J, Basson M. **Amyand hernia: A classification to improve management.** Hernia. 2008; 12(3):325-6. 10.1007/s10029-008-0331-y
10. Green J, Gutwein LG. **Amyand's hernia: A rare inguinal hernia.** Journal of surgical case reports. 2013; 2013(9). 10.1093/jscr/rjt043

11. Lyass S, Kim A, Bauer J. **Perforated appendicitis within an inguinal hernia: Case report and review of the literature.** American Journal of Gastroenterology (Springer Nature). 1997; 92(4). Retrieved from <https://pubmed.ncbi.nlm.nih.gov/9128329>

AUTHORSHIP AND CONTRIBUTION DECLARATION

No.	Author(s) Full Name	Contribution to the paper	Author(s) Signature
1	Muhammad Zeb	Main Author	
2	Sabir Khan Khattak	Co-Author	
3	Syed Shayan Shah	Co-Author	
4	Abdul Haseeb	Co-Author	
5	Syed Qasim Ali Shah	Co-Author	