



ORIGINAL ARTICLE

Comparison of sodium tetradecyl sulphate versus conventional hydrocelectomy for adult hydrocele aspiration.

Hamid Raza Laghari¹, Muhammad Akram², Farhan Ali³, Syed Kashif Hussain⁴, Illahi Bux Brohi⁵, Zulfiqar Ahmed Qaim⁶

Article Citation: Laghari HR, Akram M, Ali F, Hussain SK, Brohi IB, Qaim ZA. Comparison of sodium tetradecyl sulphate versus conventional hydrocelectomy for adult hydrocele aspiration. Professional Med J 2022; 29(11):1601-1608. <https://doi.org/10.29309/TPMJ/2022.29.11.7130>

ABSTRACT... Objective: To evaluate the treatment of hydrocele and compare the post-operative course and outcome of sodium tetradecyl sulfate (3 %) (STDS) as a harmless and active sclerosant followed by aspiration with conventional hydrocelectomy for the management of adult hydrocele. **Study Design:** Cross Sectional. **Setting:** Liaquat University of Medical and Health Sciences, Jamshoro. **Period:** 1st May 2019 to 31st October 2019. **Material & Methods:** Fifty patients with unilateral or bilateral primary vaginal hydrocele were included in this study. Subjects with secondary vaginal hydrocele (secondary to trauma, malignancy, or epididymo-orchitis), communicating hydrocele, infected hydrocele, having a positive history of previous intervention (sclerotherapy or operation) and/or uncontrolled diabetes mellitus were excluded. Data were analyzed in SPSS version 22.0. **Results:** All patients were equally divided into two groups A and B. Group A (n = 25) patients were submitted to Sclerotherapy and Group B (n = 25) patients were submitted to the Conventional Surgical Hydrocelectomy. Most of the patients 24(96.0%) who underwent in Group A (Sclerotherapy, n = 25), were discharged within 1-6 days i.e. less postoperative stay whereas the majority of the patients 14(56.0%) who underwent in Hydrocelectomy group were discharged between 1 to 6 days. Patients who underwent Hydrocelectomy had more postoperative stay and in 3 cases up to 18 days. **Conclusion:** Sclerotherapy is the treatment of choice for primary hydrocele. Complications like pain, hematoma, and infection are less than surgical procedures. Hospital stay is minimal and does not affect the day-to-day work of the patient having sclerotherapy.

Key words: Hydrocele, Sodium Tetradecyl Sulphate, Sclerotherapy.

INTRODUCTION

A assortment of liquid within the testicular tunica vaginalis is known as hydrocele., one of the five most commonly reported urological problems presented with scrotal lump or swelling. Pathophysiological classification has divided hydrocele into 2 types; primary hydrocele, represented by closed or non-communicating and communicating hydrocele, and secondary hydrocele, which usually develops secondary to other disorders, such as surgery complication, epididymitis, tumor, and /or trauma to the groin region.^{1,2} Prevalence rates of hydrocele are about 1% in 40 years or above males and 4.7% in neonates. Affecting fertile age males the most, affecting fertility, sexual life, and mental health as well.³ Undistinguished of age groups, hydrocele

prevalence is due to a parasitic infection caused by *Wuchereria bancrofti*, this parasite is endemic in the humid and subtropical counties of the Americas, the Pacific, the Middle East, and Africa, an estimation of cases reported as 25,000,000 males infected by this parasite and developed hydrocele.⁴ The infection is usually assimilated in the early years of life but complications, such as elephantiasis and hydrocele, occur usually after the fourth decade of life. Diagnosis is clinical and requires thorough history to consider any variation in size, suggesting an obvious processus vaginalis. Scrotal ultrasonography is required in non-palpable testicles to rule out a subtending testicular solid mass requiring inguinal exploration.⁵

1. MBBS, FCPS, MS, Assistant Professor Surgery and Allied, PAQSJ.
2. MBBS, FCPS, Assistant Professor Surgery and Allied, PAQSJ.
3. MBBS, FCPS, Assistant Professor General Surgery, PAQSJ.
4. MBBS, MS, Consultant General Surgery, Al Hayat Hospital.
5. MBBS, FCPS, Assistant Professor Pediatric Surgery, PAQSJ.
6. MBBS, FCPS, Assistant Professor Urology, PAQSJ.

Correspondence Address:
Dr. Hamid Raza Laghari
Surgery and Allied, PAQSJ.
raza_hamid22@hotmail.com

Article received on: 17/05/2022
Accepted for publication: 19/08/2022

Surgical intervention is known as the gold standard to treat hydrocele as it is widely accepted and the most definitive modality to ensure success worldwide. However, surgical complications are traumatic including prolonged recovery duration, financial strain, pain of surgery and anesthesia related complications.^{4,6} Another less painful and comparatively comfortable procedure is to repeatedly aspirate the fluid, but it increases the risk of recurrent infections.⁷ The commonly reported intra-operative complications are bleeding, damage to the cord arrangements and epididymis, and rotation of the testis after a defective finding postoperatively.^{8,9} In the last decade the exemplary alteration were recorded in minimally invasive surgeries, sclerotherapy gained popularity as a safe, effective, and painless procedure with minimal duration required for hospital stay and recovery, reduced financial burden, and patient satisfaction or convenience is also improved in sclerotherapy.¹⁰ Sclerotherapy is an extremely effective, harmless, and cost-effective procedure that authorizes one to avoid invasive procedures, anesthesia, and hospitalization in patients. Its usage is justified in adults, particularly in the elderly.¹¹ Although repetition may require in some patients to achieve complete eradication of hydrocele. Developing countries like India, Pakistan, Bangladesh studies reported sclerotherapy as a procedure of choice due to minimal cost of the procedure and fewer days requirement to recover as urologists reported the problems in developing countries is a financial burden not only on patients but health care setups as well. Excessive patient influx and prevalence of urological disorders keep urology institutes busy¹² Many studies evaluated the efficacy of sclerotherapy separately, while comparison studies are a few, and literature improvement is required.

This study aims to evaluate the two most commonly used techniques in the treatment of hydrocele and compare the post-operative course and outcome of sodium tetradecyl sulfate (3 %) (STDS) as a harmless and active sclerosant followed by aspiration with conventional hydrocelectomy for the management of adult hydrocele.

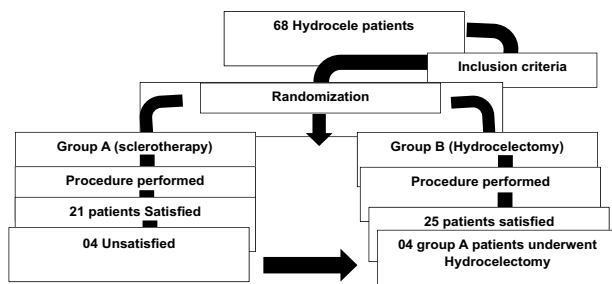
MATERIAL & METHODS

This is a randomized, cross-sectional study, conducted at Liaquat University of medical and health sciences, Jamshoro for six months from 1st May 2019 to 31st October 2019. Ethical approval was obtained from the institutional review board with ERC number of LUMHS/REC/739. Sample size was calculated with the help of referenced study conducted in China¹³ required sample size was 50 patients. Inclusion criteria was defined as age group ranging from 15 years to 60 years, with unilateral or bilateral primary vaginal hydrocele. Participants with secondary vaginal hydrocele (secondary to trauma, malignancy, or epididymal-orchitis), communicating hydrocele, infected hydrocele, having a positive history of preceding intervention (sclerotherapy or operation), and/or uncontrolled diabetes mellitus were excluded.

The diagnostic criteria involve clinical examination for fluctuation and transillumination test, routine CBC, urine routine examination and microscopy plus Ultrasonography of the scrotum in nominated cases the testicular tumor is presumed clinically. Informed consent was signed by the patient after thorough counseling regarding randomization and follow-up schedule from the primary investigator, each patient underwent four sessions of assessment, at one week, one month, three months, and finally at sixth month after surgery and earlier if complications occur.

Fifty patients were included in the study and randomly allotted within 2 groups, group A had 25 patients who underwent Sclerotherapy and group B had 25 patients who underwent Hydrocelectomy. Randomization was performed with the help of a computerized randomization application and patients were given random case numbers to eliminate biases. 04 patients of group A (sclerotherapy) were reported as dissatisfied with the therapy they have received and switched to Hydrocelectomy after the first aspiration. (Flow chart)

Chart:



Procedure Technique

Paint the scrotum with a povidone-iodine solution followed by dressing. Identify the site by transillumination before puncturing to elude wound to the testis. Scrotal puncture by a 20-G venous cannula to drain the fluid with a 20-cc disposable syringe. Subsequent to aspiration of the whole innards of the sac inject 03 % STDS. The amount of sclerosant injection will be based on the amount of fluid drained. For ≤ 200 ml of fluid 02 ml of STDS; for 201–300 ml, 03 ml of STDS; for > 300 ml of fluid sapped, inject 04 ml of STDS. Four ml were the extreme dose, and not more than 4 ml to be used under any situation. After the shot of the sclerosant, the two layers of the sac were opposed. All patients were specified with prophylactic antibiotics (Ciprofloxacin—500 mg) twice daily for 5 days. Only Paracetamol is to be arranged as and when required. No other anti-inflammatory drug was given. Patients in whom fluctuation and transillumination persist after 1 month remained a second dose of sclerosant. Hydrocele was considered cured when the patient no longer had fluid on the fluctuation test and negative transillumination on clinical examination. Fluctuation and transillumination persisting after 3 months were taken as failure and surgery was advised.

All the data was entered and analyzed into SPSS 22.0 version. The quantitative data for continuous variables like age and duration of hospital stay, duration of hydrocele, and size of hydrocele were presented as Mean \pm Standard Deviation and the Student t-test was applied to compare the means between two groups A (Sclerotherapy) and B (Hydrocelectomy). Frequency and percentage were computed for the qualitative variables like age in groups, side of hydrocele, clinical

presentation, and postoperative complications, and chi-square test was applied to compare the proportions between the groups, and P-value < 0.05 was considered as significant.

RESULTS

A total of 50 patients with the diagnosis of hydrocele were included in this study. All patients were similarly allocated into two groups A and B. Group A ($n = 25$) patients were submitted to Sclerotherapy and Group B ($n = 25$) patients were submitted to the Conventional Surgical Hydrocelectomy.

The age range of study participants was 15 to 60 years, the youngest patient age was 15 years and the oldest was 60 years. The group distribution indicated 10 (40%) patients in 21-30 years age group, 8 (32%) in 31-40 years, and 4(16%) in 41-50 years age category within group A (sclerotherapy) while Group B participants age distribution indicated 2(8%) in 21-30 years, 8(32%) in 31-40 years, 6(24%) in 41-50 category and 8(32%) in 51-60 category. The P-value of age categories was significant with a 0.041 value. The mean age \pm SD of Group A (Sclerotherapy, $n = 25$) was 36.60 ± 11.75 years while the mean age \pm SD of Group B (Hydrocelectomy, $n = 25$) was 43.68 ± 12.34 years. Age comparison was significant and represented with a p-value of 0.043. The size of hydrocele was documented and group A and group B participants showed a mean value of 298.0 ± 135.35 and 330.04 ± 187.66 ml respectively. (Table-I)

The duration of hydrocele was measured in frequency and percentage with 05 categories ranging 0-6 months, 7-12 months, 13-24 months, 25-36 months, and 37-48 months indicating 14(28%), 11(22%), 10(20%), 8(16%) and 7(14%) respectively. (Figure-1)

Variables	Procedure		Total n=50	P-Value
	Clerotherapy (Group A) n=25	Hydrocelectomy (Group B) n=25		
Age (years) mean ± St. deviation	36.60±11.75	43.68±12.34		0.043
Age distribution within groups (years):				
15 - 20	0	1(4.0%)	01(2.0%)	0.041
21 - 30	10(40.0%)	2(8.0%)	12(24.0%)	
31 - 40	8(32.0%)	8(32.0%)	16(32.0%)	
41 - 50	4(16.0%)	6(24.0%)	10(20.0%)	
51 - 60	3(12.0%)	8(32.0%)	11(22.0%)	
Size of hydrocele (in ml) mean ± St. deviation	298.0±135.35	330.04±187.66		0.492

Table-I.

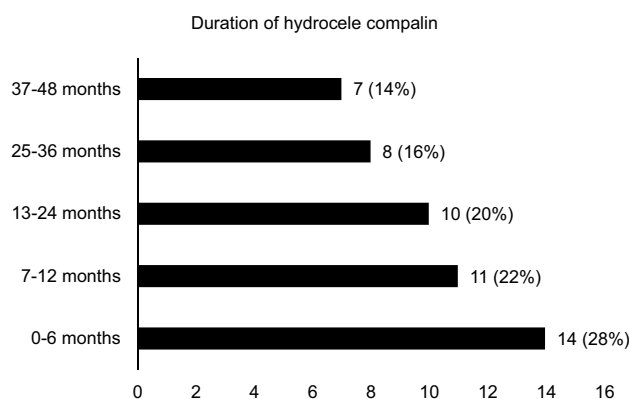


Figure-1

Hospital stay was described in days, the requirement of days to recover from surgery in conventional Hydrocelectomy and Sclerotherapy were represented in three categories ranging from 1-6 days, 7-12 days, and 13-18 days indicating 24(96%) of Group A participants get discharged within first 6 days of the procedure, and only 1(4%) required administration after 6th day of the procedure and discharge within 7-12 days. While the Hydrocelectomy group participants required prolonged stay at the hospital after surgery, 14(56%) were discharged within 6 days, 8(32%) were discharged within 7-12 days and 3(12%) needed 13-18 days of hospital stay. (Table-II)

Post-procedure complications were determined as post-operative pain, hematoma, scrotal edema, infection, and recurrence. They complained of postoperative pain was increased in group A (sclerotherapy) with 6 (24%) patients while group B (Hydrocelectomy) represented only 4 (16%) patients with post-operative pain. However, increased frequency of hematoma and scrotal edema was noted in group B (Hydrocelectomy) with 8 (32%) and 6 (24%) frequency as compared to 2 (8%) and 2 (8%) of results from group A (Sclerotherapy), in hydroceles wound infection was represented in one case (4.0%) of the sclerotherapy group and three cases (12.0%) of the Hydrocelectomy group. The chi-square test the p-value is found to be p=0.28; NS. This means that the difference in the occurrence of postoperative complication infection between the two procedures is statistically not significant. While the rate of recurrence was noted as improved in Group A (sclerotherapy) with 8(32.0%) patients as compared to that Group B (Hydrocelectomy) with 4(16.0%) cases only. On applying the chi-square test the p-value is found to be 0.004, in the case of large-sized hydroceles. This “p-value” shows that the alteration in the occurrence of postoperative relapse amid the procedures is statistically significant.

Hospital Stay in Groups	Procedure		Total	P-Value
	Sclerotherapy n = 25(%)	Hydrocelectomy n = 25(%)		
1 to 6 days	24(96.0%)	14(56.0%)	38(76.0%)	0.0002
7 to 12 days	1(4.0%)	8(32.0%)	9(18.0%)	
13 to 18 days	0	3(12.0%)	3(6.0%)	
Total	25	25	50	

Table-II

Overall, 21 of 25 (84%) patients treated with aspiration and sclerotherapy were completely satisfied with their treatment, and this is the most pertinent finding of our study. Four patients were dissatisfied with their initial aspiration and sclerotherapy and chose hydrocelectomy over a second aspiration and sclerotherapy procedure.

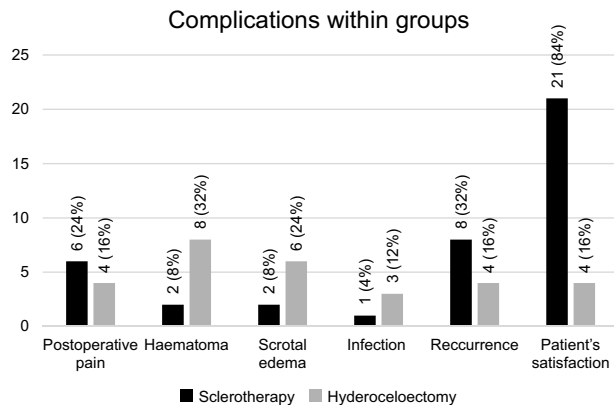


Figure-2

DISCUSSION

A hydrocele, a common chronic condition in men, causes physical, psychological, social, and economic distress. Many men with a hydrocele think that they will never be cured, are often embarrassed by the condition, and frequently lose hope of living a normal life. Hydrocelectomy is measured as the gold standard practice for hydrocele; aspiration and sclerotherapy represent fewer complications and the success rate are lower as compared to hydrocelectomy. Sclerotherapy is an interventional radiological technique commonly used to treat cystic lesions and lymphatic malformations, mainly not acquiescent to invasive resection.

Current literature recommends that sclerotherapy can be used to treat hydroceles in the adult population.⁸ The recommended contrivance of action is that the sclerosant acts as an irritant, eroding the epithelium of the sac, destroying its ability to produce fluid. Repetitive treatments are essential but their minimally invasive nature makes this tolerable to patients. Complications are characteristically negligible. This study has been carried to compare the results of Injection Sclerotherapy using sodium tetradecyl sulfate (03% STD) and Surgery (conventional

hydrocelectomy) for the management of adult hydrocele concerning complications like pain, scrotal edema, wound infection, reoccurrence, and patient satisfaction. The age range of this study defended the previous researches and indicated the higher prevalence rates of hydrocele in young adults, in the adult age group the youngest patient was 15 years old and the oldest was 83 years old which is almost similar to our study subject's participation.¹⁴ Primary vaginal hydrocele was more prevalent in the fourth decade of life.¹⁵ This study documented the duration of hydrocele and results indicated the patients reported to a health care facility within the first 6 months of disease occurrence, with 14 (28.0%) followed by 11 (12.0%) patients had a duration of presenting complaints from 7 months to 1 year. Another study presented the presenting duration of hydrocele as 2.5 years of mean duration¹⁶, The laterality of hydrocele was dominant on the right side, results are endorsed with many pieces of research indicating unilateral hydrocele more frequent with right side dominance.¹⁷

In the present study 16.0% of cases, developed postoperative pain and required Lord's procedure¹⁸, other studies reported postoperative pain after Hydrocelectomy in 20% - 30% of patients¹⁹, in another study Postoperative pain was present in 24% of patients in sclerotherapy and 20% of patients in surgery groups.²⁰ In hydroceles, sclerotherapy recorded an 8.0% incidence of post-procedure hematoma at all, which is significantly lower compared to other conventional techniques; as compared to Lord's Plication, which had 32.0% incidence. Similar results were presented by other researchers indicating fewer hematoma incidents in sclerotherapy as compared to Hydrocelectomy.^{20,21} In the current study, the Sclerotherapy technique had fewer hematoma when related with eversion or elimination of the sac. Explaining the basis that much dissection is not required. Hence, no hematoma formation occurred which is preclude all other complications present with conventional methods of treatment. Scrotal edema was more in Jaboulay's procedure 24% cases and sclerotherapy technique 8.0%. Management of scrotal edema was done with

the help of post-operative antibiotics and pain management drugs. Another study indicated the higher rates of scrotal edema as a complication after sclerotherapy while Hydrocelectomy cases were not reported as prevalent for scrotal edema.^{22,23}

Wound infection was noted only in the case of hydroceles as noted in one case (4.0%) of the sclerotherapy group and three cases (12.0%) of the Hydrocelectomy group, the reason for scrotal swelling could be wound infection²⁴ while only 8 cases (32%) who underwent sclera therapy had a recurrence as compared to all the other cases who underwent surgery and 4(16.0%) had recurrence during the study period.²⁵ Prolonged hospital stay was noted in group B or Hydrocelectomy patients as study subjects required more time to recover, while sclerotherapy patients were discharged from hospital within 3 days.²⁶

In both present and other studies duration of stay in hospital is less in Sclerotherapy with 5% phenol when compared to surgical (Jaboulay's) procedure, as it is a less invasive procedure. These findings are similar to this study. There are several studies in the medical literature that have confirmed the efficacy of aspiration and sclerotherapy in the management of benign scrotal cysts. However, it is hard to associate many studies due to difference of relapse, overall success after the first treatment has been reported with phenol (48%), polidocanol (59%), doxycycline (84–86%).^{27,29}

RECOMMENDATIONS

Patient counselling is necessary for understanding of procedure and related complications for both sclerotherapy and hydrocelectomy.

CONCLUSION

Sclerotherapy had fewer to nil complications as compared to hydrocelectomy in our study.

The financial strain of sclerotherapy is considerably lower, patient satisfaction was improved with sclerotherapy, and Post-treatment recovery is excellent.






Copyright© 19 Aug, 2022.

REFERENCES

- Ahmad T, Ullah S, Nabi G, Ullah N, Rahman K. **A mini review on hydrocele: The most common scrotal problem.** Social and Basic Sciences Research Review. 2014; 2(12):571-5.
- Gadelkareem RA. **Abdominoscrotal hydrocele: A systematic review and proposed clinical grading.** African Journal of Urology. 2018 Aug 7; 24(2):83-92.
- Aldoah B, et al. **Effects of hydrocele on morphology and function of testis.** Ann Med Health Sci Res. 2020; 10:764-770.
- Lundström KJ, Söderström L, Jernow H, Stattin P, Nordin P. **Epidemiology of hydrocele and spermatocele; incidence, treatment and complications.** Scandinavian journal of urology. 2019 May 4; 53(2-3):134-8. <https://doi.org/10.1080/21681805.2019.1600582>
- Cimador M, Castagnetti M, De Grazia E. **Management of hydrocele in adolescent patients.** Nature Reviews Urology. 2010 Jul; 7(7):379-85. <http://dx.doi.org/10.1038/nrurol.2010.80>
- Sawers L, Stillwaggon E, Chiphwanya J, Mkwanda SZ, Betts H, Martindale S, Kelly-Hope LA. **Economic benefits and costs of surgery for filarial hydrocele in Malawi.** PLoS Neglected Tropical Diseases. 2020 Mar 25; 14(3):e0008003. <http://dx.doi.org/10.1371/journal.pntd.0008003>
- Low LS, Nair SM, Davies AJ, Akapita T, Holmes MA. **Aspiration and sclerotherapy of hydroceles and spermatoceles/epididymal cysts with 100% alcohol.** ANZ Journal of Surgery. 2020 Jan; 90(1-2):57-61. ANZ J Surg. 2020; 90(1–2):57–61.
- Taylor WS, Cobley J, Mahmalji W. **Is aspiration and sclerotherapy treatment for hydroceles in the aging male an evidence-based treatment?.** The Aging Male. 2019 Jul 3; 22(3):163-8. <https://doi.org/10.1080/13685538.2018.1425987>
- Keller AK, Howard MM, Jensen JB. **Complications after scrotal surgery—still a major issue?.** Scandinavian Journal of Urology. 2021 Sep 3; 55(5):404-7. <https://doi.org/10.1080/21681805.2021.1884131>
- Tsoufias G, Hoballah JJ, Velmahos GC, Ho YH, editors. **The surgical management of parasitic diseases.** Springer International Publishing; 2020 Jul 23.
- Korkes F, Teles SB, Nascimento MP, Almeida SS, Codeço AM. **Comparison of outcomes and costs of surgery versus sclerotherapy to treat hydrocele.** Einstein (São Paulo). 2021 Jul 16; 19:1-5.

12. Hussain M. **Evolution of urology services in Pakistan.** J Coll Physicians Surg Pak. 2021 Jun 1; 31(6):746-9.
13. Lin L, Hong HS, Gao YL, Yang JR, Li T, Zhu QG, Ye LF, Wei YB. **Individualized minimally invasive treatment for adult testicular hydrocele: A pilot study.** World journal of clinical cases. 2019 Mar 3; 7(6):727. doi: 10.12998/wjcc.v7.i6.727
14. Lashen AM, Nafea MA, Elsayed MA. **Hydrocelectomy through inguinal approach in adults.** The Egyptian Journal of Hospital Medicine. 2019 Jul 1; 76(3):3801-6.
15. Prasad K. **A comparative study of sclerotherapy with 5% phenol in water versus surgical treatment for primary vaginal hydrocele.** Int J Pharm Med Res. 2015; 3(1):10-4.
16. Okorie CO, Pisters LL, Liu P. **Longstanding hydrocele in adult Black Africans: Is preoperative scrotal ultrasound justified?** Nigerian Medical Journal: Journal of the Nigeria Medical Association. 2011 Jul; 52(3):173. doi: 10.4103/0300-1652.86130
17. Lozano J, Arbulú I, Rey-Maqueira J. **The greening role of tour operators.** Environmental management. 2016 Jan; 57(1):49-61. <https://doi.org/10.1007/s00267-015-0587-9>
18. Singh DR, Gupta SK, Gupta S. **Lord's procedure: A curative outpatient operation for primary hydrocele.** Journal of the Indian Medical Association. 1996 Apr 1; 94(4):141-2.
19. Agnihotri IP, Jain SC, Swarnkar MM. **Comparative study of inguinal versus scrotal approach in idiopathic vaginal hydrocele.** International Surgery Journal. 2018 Mar 23; 5(4):1464-8.
20. Labib MA, Munthali G. **A comparative study of sclerotherapy with phenol versus surgical treatment for hydrocoele.** East and Central African Journal of Surgery. 2004; 9(2):25-7.
21. Dunaevskii IL, Gorokhov ME. **[A comparative evaluation of surgical methods for treating hydrocele].** Urol Nefrol (Mosk). (1):59-62.
22. Lin L, Hong HS, Gao YL, Yang JR, Li T, Zhu QG, Ye LF, Wei YB. **Individualized minimally invasive treatment for adult testicular hydrocele: A pilot study.** World journal of clinical cases. 2019 Mar 3; 7(6):727. doi: 10.12998/wjcc.v7.i6.727
23. Roy A, Jain V, Majumdar J. **Aspiration sclerotherapy: A novel and cost-effective approach to the management of hydroceles in a developing country.** International Surgery Journal. 2017 Nov 25; 4(12):3884-9. <http://dx.doi.org/10.18203/2349-2902.isj20175071>
24. Latif U, Bashir MA, Rashid A, Shah TA. **Hydrocele;; Surgery vs. Sclerotherapy.** The Professional Medical Journal. 2008 Mar 10; 15(01):125-8. DOI: <https://doi.org/10.29309/TPMJ/2008.15.01.2709>
25. Saber A. **Minimally access versus conventional hydrocelectomy: A randomized trial.** International braz j urol. 2015 Jul; 41:750-6.
26. Tsai L, Milburn PA, Cecil CL, Lowry PS, Hermans MR. **Comparison of recurrence and postoperative complications between 3 different techniques for surgical repair of idiopathic hydrocele.** Urology [Internet]. 2019; 125:239-42. <https://doi.org/10.1016/j.urology.2018.12.004>
27. Rassam J, Healey AE, Wood SJ, Corbett HJ. **A challenging abdomino-scrotal hydrocele—successful resolution with the help of interventional radiology guided sclerosis.** Journal of Surgical Case Reports. 2018 Sep; 2018(9):rjy232. <https://doi.org/10.1093/jscr/rjy232>
28. Francis JJ, Levine LA. **Aspiration and sclerotherapy: A nonsurgical treatment option for hydroceles.** The Journal of urology. 2013 May 1; 189(5):1725-9. <https://doi.org/10.1016/j.juro.2012.11.008>
29. Jahnson S, Sandblom D, Holmäng S. **A randomized trial comparing 2 doses of polidocanol sclerotherapy for hydrocele or spermatocele.** The Journal of urology. 2011 Oct; 186(4):1319-23. <https://doi.org/10.1016/j.juro.2011.06.005>

AUTHORSHIP AND CONTRIBUTION DECLARATION

No.	Author(s) Full Name	Contribution to the paper	Author(s) Signature
1	Hamid Raza Laghari	Objective, Problem statement.	
2	Muhammad Akram	Procedure	
3	Farhan Ali	Write up	
4	Syed Kashif Hussain	Data analysis.	
5	Illahi Bux Brohi	Result interpretation.	
6	Zulfiqar Ahmed Qaim	Final approval.	