



ORIGINAL ARTICLE

## Diagnostic accuracy of magnetic resonance spectroscopy (MRS) for diagnosis of focal brain lesions taking histopathology as gold standard.

Samia Musawar<sup>1</sup>, Asma Shaukat<sup>2</sup>, Amber Manzoor<sup>3</sup>, Iqra Manzoor<sup>4</sup>

**Article Citation:** Musawar S, Ayyaz AS, Manzoor A, Manzoor I. Diagnostic accuracy of magnetic resonance spectroscopy (MRS) for diagnosis of focal brain lesions taking histopathology as gold standard. Professional Med J 2022; 29(11):1740-1744.  
<https://doi.org/10.29309/TPMJ/2022.29.11.7094>

**ABSTRACT... Objective:** To determine diagnostic accuracy of MRS for diagnosis of malignant brain lesions taking histopathology as gold standard. **Study Design:** Cross Sectional Validation study. **Setting:** Department of Radiology, Lahore General Hospital, Lahore. **Period:** March 2021 to September 2021. **Material & Methods:** A total number of 127 patients who were referred for the diagnosis of focal brain lesions were included. In all patients, MRS was done by consultant radiologist to diagnose malignancy. All patients underwent surgery in the neurosurgery department and after surgery biopsy specimen were taken for diagnosis of malignancy using histopathology findings. **Results:** Mean age of patients was  $40.88 \pm 11.37$  years. There were 88 (69.29%) males and 39 (30.71%) female patients. On MRS, malignancy was diagnosed in 99 (77.95%) patients and on histopathology malignancy was diagnosed in 102 (80.31%) patients. Regarding diagnostic accuracy, MRS was 97.00% sensitive, 94.10% specific, with PPV of 78.60% and NPV of 88.00%. **Conclusion:** Magnetic resonance spectroscopy (MRS) has good sensitivity and specificity in differentiating neoplasm from non-neoplastic focal brain lesions.

**Key words:** Magnetic Resonance Spectroscopy (MRS), Malignant Lesions, Focal Brain Lesions, Histopathology.

### INTRODUCTION

The name “brain tumors” refers to a variety of malignancies that arise from various cells of the brain parenchyma or from systemic tumors that have spread to the brain. The chances of developing a primary brain tumor are 8/100000. They are the most frequent solid tumor in children, as well as the ninth most prevalent malignancy in adults. The signs of a brain tumor might be physical or psychological.<sup>1</sup> Headaches, weariness, sleep disturbances, sleepiness, motor problems, communication difficulties, dry mouth, and depression are the most prevalent symptoms of brain tumors. These can have a substantial influence on the patients’ quality of life.<sup>2</sup>

Diagnosis of brain and other localized intra-cranial lesions only on imaging modalities remains a difficult topic. Accurate diagnosis is critical for therapeutic option of brain tumour patients.<sup>3</sup> Most tumours are surgically removed when

they are accessible; there is a delicate balance between eliminating tumour tissue and protecting important brain processes.<sup>4</sup>

Magnetic Resonance Imaging (MRI) or computed tomography (CT) are utilized historically to identify focal lesions and parenchymal abnormalities in the brain.<sup>5</sup> The diagnosis of localised brain lesions with MRI or CT scan is typically challenging since they have similar appearances most of the time, and it is hard to differentiate neoplastic lesions from non-neoplastic.<sup>6,7</sup>

MRS is a non-invasive diagnostic procedure that analyses chemical composition of human tissues. MRS was initially used in therapeutic settings in the 1980s.<sup>8</sup> The chemicals in the body have a function in MRS. These chemicals generate radio-frequency signals when exposed to a high magnetic field. By analysing the chemicals in an aberrant tissue region, MRS has the capacity to

1. MBBS, FCPS (IMM), Diagnostic Radiology, Trainee, LGH.  
2. MBBS, FCPS (Diagnostic Radiology), Senior Registrar Radiology, Niazi Medical Collage Sargodha.  
3. MBBS, FCPS (IMM), Postgraduate Trainee Diagnostic Radiology, Madina Teaching Hospital, Faisalabad.  
4. MBBS, Demonstrator Medical Education, UMDC, Faisalabad.

**Correspondence Address:**  
Dr. Asma Shaukat Ayyaz  
Department of Radiology  
Niazi Medical Collage Sargodha.  
dr.asmashaukat@outlook.com

**Article received on:** 19/04/2022  
**Accepted for publication:** 04/08/2022

provide crucial knowledge that can aid in the identification of abnormal conditions.<sup>7</sup>

Aim of present research is to determine diagnostic accuracy of MRS for differentiating malignant brain lesions in patients presenting with focal brain lesions. Because existing literature has reported variable diagnostics accuracy of MRS and most of these studies were conducted using small sample size. MRS is non-invasive and is performed pre-operatively so it can also help in decision making of surgical procedure for removal of tumors by pre-operatively knowing the possible etiology of focal brain lesions.

## MATERIAL & METHODS

This Cross sectional (validation) study was carried out in the radiology department, Lahore General Hospital, Lahore from March-02-2021 to September-01-2021. Non-probability consecutive sampling technique was used.

This sample size of 127 was calculated by taking estimated frequency of malignant lesions in patients of focal brain lesions 30.9%.<sup>5</sup> and taking expected sensitivity of 87.5% (9) and 69.7% specificity.<sup>10</sup> and by taking margin of error as 10.5%.

### Inclusion Criteria

Adult patients of either gender, having age from 18 to 60 years referred to radiology department for diagnosis of focal brain lesions.

### Exclusion Criteria

Patients who did not give informed consent for participation in study.

### Data Collection Procedure

Following permission by the hospital's ethics committee, patients of focal brain lesions fulfilling the inclusion criteria of the study were included. A written informed consent was taken from each patient before including them in study. In all patients, MRS was done by consultant radiologist having atleast three years post fellowship experience and findings were evaluated by him and diagnosis of malignancy was confirmed as per operational definitions. I served as assistant

in all procedures. After that all patients underwent surgery in the neurosurgery department and after surgery biopsy specimen were taken and sent to the histopathology department for diagnosis of malignancy using histopathology findings. All the study relevant information was noted on a pre-designed Pro-forma.

### Data Analysis Procedure

Data was entered and analyzed in SPSS version 25. For quantitative variables like age, mean  $\pm$  SD was utilized. Qualitative variables like gender, Presence/absence of malignant lesions using MRS findings and histopathology. 2 $\times$ 2 table was used to calculate sensitivity, specificity, PPV, NPV and diagnostic accuracy of MRS taking histopathology as gold standard.

## RESULTS

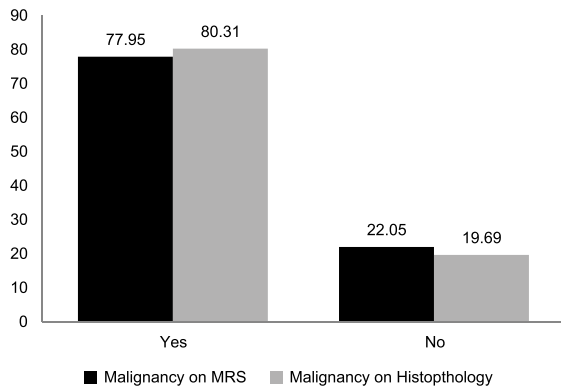
Mean age of the patients involved in this research was 40.88 $\pm$ 11.37 years with minimum age 18 and maximum age 60 years. There were more male (69.29%) patients than females (30.71%) (Figure-1).

Malignancy on MRS was diagnosed in 99 (77.95%) patients and it was not found in 28 (22.05%) patients. Malignancy on histopathology was diagnosed in 102 (80.31%) patients and it was not found in 25 (19.69%) patients (Figure 2).

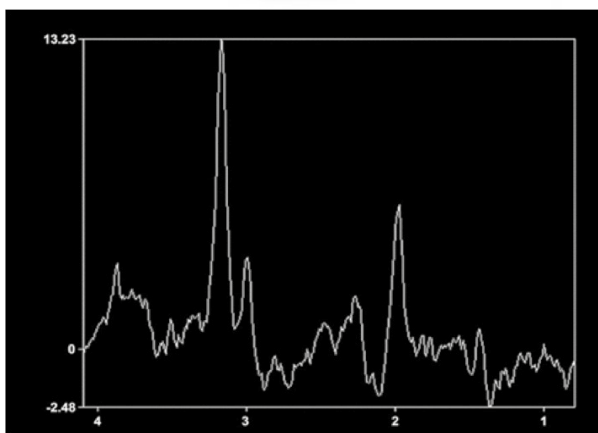
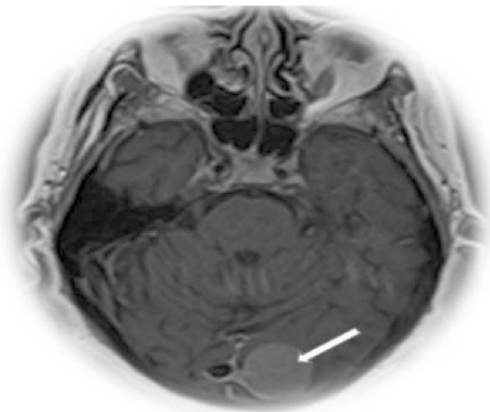
Variable	N	%
Gender		
Male	88	69.29
Female	39	30.7
Age Groups		
18-39 Years	66	51.97
40-60 Years	61	48.03
Total	127	100

**Table-I. Gender and age of the patients**

Regarding diagnostic accuracy, 2/2 table was made to calculate diagnostic accuracy, sensitivity, specificity, PPV and NPV on MRS and histopathology. MRS was 97.00% sensitive, 94.10% specific having 78.60% PPV and 88.00% NPV.



**Figure-1. Frequency of malignancy on MRS and Histopathology**



**Figure-2. MRS image of patients showing high Cho/Cr, and Cho/NAA peaks with necrotic area revealing high lipid/lactate peak**

Malignancy on Histopathology	Malignancy on MRS	
	Yes	No
Yes	96	06
No	03	22

**Table-II. Comparison of malignancy on histopathology with malignancy on MRS**

Stratification of gender was also performed and no association was found of gender with malignancy of histopathology with malignancy on MRS. In male patients, MRS was 97.10% sensitive, 93.10% specific having 73.70% PPV and 87.50% NPV. In female patients, MRS was 96.70% sensitive, 96.70% specific having 88.90% PPV and 88.90% NPV (Table-III).

Malignancy on Histopathology	Malignancy on MRS	
	Yes	No
Males		
Yes	67	05
No	02	14
Females		
Yes	29	01
No	01	08

**Table-III. Association of gender with malignancy on histopathology with malignancy on MRS**

Stratification of age was performed and no association was found of age with malignancy of histopathology with malignancy on MRS. In patients having age 18-39 years, MRS was 98.10% sensitive, 94.40% specific having 78.60% PPV and 91.70% NPV. In patients having age 40-60 years, MRS was 95.70% sensitive, 93.80% specific having 78.60% PPV and 84.60% NPV (Table-IV).

Malignancy on Histopathology	Malignancy on MRS	
	Yes	No
18-39 Years		
Yes	51	03
No	01	11
40-60 Years		
Yes	45	03
No	02	11

**Table-IV. Association of age with malignancy on histopathology with malignancy on MRS**

**DISCUSSION**

MRS is an useful technique for assessing brain tumours since it may detect the grade and type.<sup>9</sup> The spectra produced by brain tumours differed significantly from those produced by normal brain tissue. The majority of brain tumours induced a reduction in N-acetyl aspartate (NAA) and an increase in Choline (Cho), resulting in elevated Cho/NAA ratios. Because NAA is thought to be

predominantly of neuronal and axonal origin, the reduction in NAA is commonly interpreted as the loss or malfunction of normal neural tissue. Because of increased membrane turnover, the 'Cho' signal increased in brain tumours. Other metabolic abnormalities in human brain tumours include increased lactate and lipid levels, as well as increased myo-inositol (ml) levels in short echo time (TE) spectra.<sup>10</sup> MRS is most commonly utilised as a supplemental approach in clinical practise when other methods have failed to provide adequate information for diagnosis and therapy. In such circumstances, interpreting MRS data is far more complex than in typical scientific initiatives, when MRS is utilised in a restricted number of patients with limited alternative diagnoses to answer well-defined issues.<sup>11</sup>

In current study, mean age of patients was  $40.88 \pm 11.47$  years. There were 69.3% male and 30.7% female patients. In a study by Rehman et al there were 40% females and 60% males with mean age of  $37 \pm 13.24$  years. Surur et al included 57.9% women and men 42.1% ranging in age from 12 to 81 years (35 years on average) in their research.<sup>12</sup>

In present study, the sensitivity of MRS in diagnosing malignant lesions was 94.1%, specificity 88.0%, PPV of 97.0% and NPV of 78.6%. A study conducted by Jesrani et al. concluded that MRS is 87.5% sensitive, 93.3% specific, and has positive predictive value (PPV) 95.5%, negative predictive value (NPV) 89.7% and accuracy 92.1% for differentiating malignant lesions from benign lesions in patients presenting with focal brain lesions.<sup>13</sup>

Another study by Alam et al. reported that MRS has sensitivity, specificity, positive predictive value and negative predictive value and diagnostic accuracy of 90.16%, 64.70%, 90.16%, 64.70% and 78.20% respectively in differentiating malignant brain lesions from benign brain lesions.<sup>14</sup>

In another study Positive predictive value (PPV) of MRS in diagnosis of malignant brain lesions was 94.9%.<sup>15</sup>

Jesrani et al. concluded that MRS is 87.5% sensitive, 93.3% specific, and has PPV 95.5%, NPV 89.7% and accuracy 92.1% for differentiating malignant lesions from benign lesions in patients presenting with focal brain lesions.<sup>13</sup>

Another study by Alam et al found that MRS has sensitivity, specificity, positive predictive value, and negative predictive value, as well as diagnostic accuracy of 90.16 %, 64.70 %, 90.16 %, 64.70 %, and 78.20 % in differentiating malignant brain lesions from benign brain lesions, respectively.<sup>14</sup>

In MRS, two primary dangers are insufficient field homogeneity and volume averaging. Paramagnetic materials can cause poor field homogeneity, as can variances in tissue air magnetic sensitivity. Mesial anterior temporal and inferior frontal lobes are known to have poor field homogeneity in normal persons. When MRS voxel is polluted by other tissues, such as presence of subcutaneous fat, volume averaging occurs.<sup>16</sup>

## CONCLUSION

Magnetic Resonance Spectroscopy (MRS) has good sensitivity and specificity in distinguishing neoplasm from non-neoplastic focal brain lesions, an invasive brain biopsy procedure can be avoided in many cases where diagnosis is straightforward, reducing the morbidity and mortality associated with invasive procedures as well as the time to begin treatment and cost.




**Copyright© 04 Aug, 2022.**

## REFERENCES

1. DaShottaR S, bhikhabhai SuthaR R. **Magnetic resonance spectroscopy in diagnosing brain tumours? Is it Worth Doing.** 2019.
2. Ahmad M, Khalid M, Huda M, Ahmad SS. **MR spectroscopy in space occupying lesions of the brain: Does It Really Work?** 2014.
3. Alshammari QT, Salih M, Gameraddin M, Yousef M, Abdelmalik B, Loaz O. **Accuracy of magnetic resonance spectroscopy in discrimination of neoplastic and non-neoplastic brain lesions.** Current Medical Imaging. 2021; 17(7):904-10.

4. Nikmaneshi MR, Firoozabadi B, Mozafari A. **Chemo-mechanistic multi-scale model of a three-dimensional tumor microenvironment to quantify the chemotherapy response of cancer.** Biotechnology and Bioengineering. 2021; 118(10):3871-87.
5. Tarulli A. **Intracranial mass lesions.** Neurology. 2021;377-89.
6. Poussaint TY, Panigrahy A, Huisman TA. **Pediatric brain tumors.** Pediatric radiology. 2015; 45(3):443-53.
7. Rafique Z, Awan MW, Iqbal S, Usmani NN, Kamal MM, Arshad W, et al. **Diagnostic Accuracy of Magnetic Resonance Spectroscopy in Predicting the Grade of Glioma Keeping Histopathology as the Gold Standard.** Cureus. 2022; 14(2).
8. Abdelaziz O, Eshra M, Belal A, Elshafei M. **Diagnostic value of magnetic resonance spectroscopy compared with stereotactic biopsy of intra-axial brain lesions.** Journal of Neurological Surgery Part A: Central European Neurosurgery. 2016; 77(04):283-90.
9. Shokry A. **MRS of brain tumors: Diagrammatic representations and diagnostic approach.** The Egyptian Journal of Radiology and Nuclear Medicine. 2012; 43(4):603-12.
10. Ahmed NGM, Aamin A, Khalifa S, Elhassan SM, Albashir M, Ahmed M, et al. **Characterization of brain lesions using magnetic resonance spectroscopy.** 2021.
11. Hellström J, Romanos Zapata R, Libard S, Wikström J, Ortiz-Nieto F, Alafuzoff I, et al. **The value of magnetic resonance spectroscopy as a supplement to MRI of the brain in a clinical setting.** PloS one. 2018; 13(11):e0207336.
12. Surur A, Cabral JF, Marangoni A, Marchegiani S, Palacios C, Herrera E, et al. **Contributions of magnetic resonance spectroscopy in brain lesions.** RAR. 2010; 74(3):239-49.
13. Rajasree D, Kumar TL, Vijayalakshmi K. **Role of magnetic resonance spectroscopy in the evaluation of ring enhancing lesions of the brain.** Journal of Clinical & Diagnostic Research. 2020; 14(10).
14. Alam MS, Ahsan H, Sajjad Z, Beg M, Bhatti U, Enam A, et al. **Magnetic resonance spectroscopy of enhancing cerebral lesions: Analysis of 78 histopathology proven cases.** JPMA The Journal of the Pakistan Medical Association. 2014; 64(10):1141.
15. IMRAN M, AFZAL M, RANI F, Malik A, Rasheed N. **Positive Predictive Value (PPV) of Magnetic Resonance Spectroscopy (MRS) in diagnosing neoplastic brain lesions taking histopathology as gold standard.** Pakistan Journal of Medical & Health Sciences. 2019; 13(4):749-50.
16. Mullins ME. **MR spectroscopy: truly molecular imaging; past, present and future.** Neuroimaging Clinics. 2006; 16(4):605-18.

### AUTHORSHIP AND CONTRIBUTION DECLARATION

No.	Author(s) Full Name	Contribution to the paper	Author(s) Signature
1	Samia Musawar	Paper writing & Data collection.	
2	Asma Shaukat	Data collection & analysis.	
3	Amber Manzoor	Data collector.	
4	Iqra Manzoor	Data analysis.	