



CASE REPORT

Cortical venous thrombosis in a patient with rheumatic heart disease and metallic prosthetic valves on warfarin: A case report.

Nauman Ismat Butt¹, Fahmina Ashfaq², Sabeen Aftab³, Khalid Mahmood⁴, Ali Anwar⁵

Article Citation: Butt NI, Ashfaq F, Aftab S, Mahmood K, Anwar A. Cortical venous thrombosis in a patient with rheumatic heart disease and metallic prosthetic valves on warfarin: A case report. Professional Med J 2022; 29(8):1439-1443.
<https://doi.org/10.29309/TPMJ/2022.29.09.7046>

ABSTRACT... We present the case of a 27 year old woman who presented with paralysis of left-half of the body and inability to speak for 1 day. She was a diagnosed patient of Rheumatic heart disease since her childhood for which mitral valve replacement with metallic valves had been done 7 years ago. She had been taking warfarin regularly but INR had not been monitored. She had one child born through Cesarean section at 37 weeks of gestation 4 weeks prior to presentation. She had taken warfarin throughout her pregnancy, and discontinued it 2 days before her delivery. Her CT brain showed multiple bilateral asymmetrical hemorrhagic venous infarcts due to sinus thrombosis subsequently confirmed by Magnetic Resonance Venography. The final diagnosis was Rheumatic heart disease with hemorrhagic venous infarcts due to cortical venous thrombosis and a multidisciplinary management involving radiologist, cardiologist, neurologist and gynecologist was planned.

Key words: Cortical Venous Thrombosis, Heparin, Prosthetic Heart Valves, Rheumatic Heart Disease, Warfarin.

INTRODUCTION

Cortical Venous Thrombosis (CVT) is thrice more common in women as compared to men.¹ Two different mechanisms contributing to presentation of CVT are thrombosis in cerebral veins or dural sinus resulting in parenchymal cerebral injury, and blockage of dural sinus leading to diminished cerebrospinal fluid absorption with raised intracranial pressure.¹ The most frequent risk factors include pregnancy, puerperium, oral contraceptive use, infections, malignancy and prothrombotic conditions either such as anti-thrombin deficiency, Factor V Leiden mutation, protein C or protein S deficiency, Antiphospholipid syndrome, polycythemia rubra vera and thrombocythemia.² CVT usually has a favorable outcome. However up to 5% patients may die in acute phase of CVT due to transtentorial herniation.³ Deep venous system thrombosis, depressed mental status, right hemisphere hemorrhage and lesions in posterior fossa predict mortality in the acute phase. There

is 2-4% risk of recurrent CVT and 4-7% risk of recurrent thromboembolism affecting other sites.³ Long-term mortality is nearly 10 percent and is predominantly related to underlying condition. Poor long-term prognostic factors include male sex, age >37 years, infections of central nervous system, underlying malignancy, deep venous system thrombosis and Glasgow coma scale score <9 at presentation.^{2,3}

CASE REPORT

We present the case of a 27 year old woman who was admitted through the medical emergency with paralysis of left half of body and inability to speak for 1 day. She was a diagnosed patient of Rheumatic heart disease since her childhood for which mitral valve replacement with metallic valves had been done 7 years ago. She had been taking warfarin regularly but INR had not been monitored. Now, 1 day ago she developed complete paralysis of the left-half of the body. This was her 2nd episode of paralysis and it was sudden in onset,

1. MBBS, FCPS, Assistant Professor Medicine, Azra Naheed Medical College, Superior University Lahore.
2. MBBS, MRCP, MCCEE, Assistant Professor Medicine, Azra Naheed Medical College, Superior University Lahore.
3. MBBS, FCPS, Assistant Professor Medicine, Azra Naheed Medical College, Superior University Lahore.
4. MBBS, FCPS, Assistant Professor Medicine, Azra Naheed Medical College, Superior University Lahore.
5. MBBS, SMO Medicine, Azra Naheed Medical College, Superior University Lahore.

Correspondence Address:
Dr. Nauman Ismat Butt
Department of Medicine & Allied
Azra Naheed Medical College, Superior University,
17-km Main Raiwind Road, Kot Araian, Lahore.
nauman_ib@yahoo.com

Article received on: 28/02/2022
Accepted for publication: 20/06/2022

non-progressive, associated with headache and 2 episodes of projectile vomiting, one cupful in quantity, containing partially-digested food particles. Along with this she developed complete inability to speak however there was no history of fever, fits, loss of consciousness, numbness and visual disturbance. The 1st episode of paralysis occurred 10 days ago when she developed complete paralysis of the right-half of the body on waking up that morning, sudden in onset, non-progressive, along with slurring of speech. She was taken to a local hospital where a diagnosis of ischemic stroke was made and she was prescribed oral anticoagulants with physiotherapy and then discharged home. There was partial improvement in power of her limbs over the next couple of days but her speech did not improve. There was no past or current history of abdominal pain or fullness, weight loss and body or pedal swelling, skin rash, photosensitivity, joint pain, oral ulcers, Reynaud's phenomena, lumps or bumps, easy bruisability, purpura or petechiae, bleeding from nose, gums or in urine and stools, cough, sputum, shortness of breath, orthopnea, PND, nose or ear discharge.

She had one child born through Cesarean section at 37 weeks of gestation 4 weeks prior to presentation. She had taken warfarin throughout her pregnancy, and discontinued it 2 days before her delivery. Prior to her gestation, there were no complaints of menstrual problems or abortions. She was diagnosed with gestational diabetes mellitus 4 months ago during the 7th month of pregnancy for which she was taking injectable insulin. She had no known allergies, did not smoke or use illicit drugs and oral contraceptives. On examination the patient was conscious, appeared anxious, but was unable to speak. She understood and followed the commands properly during the examination. Pain, touch and sense of vibration were intact bilaterally with no nystagmus or pendular knee jerk. Coordination of movements could not be assessed and she was unable to walk. There was no ptosis and pupils were normal in size and shape with intact light and accommodation reflexes. Eye movements were normal. Corneal and conjunctival reflexes were present with normal wrinkling of forehead,

closure of eyelids and nasolabial folds. Angle of mouth was not deviated and shape of tongue was normal. On CVS examination, a scar mark was present along the left edge of sternum with no visible pulsations. Apex beat was palpable in the 6th intercostal space in the anterior axillary line, character ill-sustained heave but no thrill. Left parasternal heave was not palpable with S1 of variable intensity and loud P2. Metallic clicking sounds were audible. A high-pitched grade-III early-diastolic murmur was present at pulmonary area and became loud on inspiration. JVP was not raised. Rest of the examination was unremarkable.

Her blood work up is shown in Table-I. Her CT brain (Figure-1 and Figure-2) showed multiple bilateral asymmetrical hemorrhagic venous infarcts involving supra-tentorial cerebral hemispheres, bilateral parietal, bilateral central semi-ovale, brain stem, left occipital and right high cortical parietal regions suggestive of hemorrhagic venous infarcts due to sinus thrombosis subsequently confirmed by Magnetic Resonance Venography. Her chest X-ray is shown in Figure-3. Her echocardiography revealed normal sized aortic root with dilated left atrium, normal dimensions of left ventricle with moderate systolic dysfunction and ejection fraction 40%, moderately severe hypokinesia of anterior and antero-lateral wall, prosthetic mitral valve in-situ with normal opening and closing of both discs, mild tricuspid regurgitation due to mild pulmonary hypertension, other valves were normal with intact intra-atrial and intra-ventricular septa, and no evidence of mass or clot was noted. Our final diagnosis was Rheumatic heart disease with hemorrhagic venous infarcts due to cortical venous thrombosis and a multidisciplinary management involving radiologist, cardiologist, neurologist and gynecologist was planned.

DISCUSSION

The differential diagnosis of our patient included Ischemic stroke due to atrial fibrillation or cardiac thrombosis, hemorrhagic stroke due to warfarin toxicity, infective endocarditis with septic emboli, postpartum cardiomyopathy, Antiphospholipid syndrome, infections (particularly chlamydia and HIV), multiple sclerosis, Moyamoya disease,

fibromuscular dysplasia, polycythemia rubra vera and Call-Fleming syndrome (postpartum angiopathy).

Investigation	Patient's Value	Reference Range
Hemoglobin (G/dl)	8.9	12.0-16.0
TLC (per mm ³)	1,200	4,000-11,000
Platelets (per mm ³)	193,000	150,000-450,000
Neutrophils (%)	76	50-70
Lymphocytes (%)	18	20-45
Monocytes (%)	04	02-08
Eosionphils (%)	02	01-04
PT (seconds)	25	13
INR	1.9	1-1.3
APTT (seconds)	35	34
Total Proteins (G/dl)	7.0	6.4-8.3
Albumin (G/dl)	4.2	3.5-5.0
Serum Bilirubin (mg/dl)	0.6	Up to 1.0
AST (U/L)	30	Less than 35
ALT (U/L)	11	Less Than 35
Alkaline Phosphatase (U/L)	108	30-120
Blood Urea (mg/dl)	57	10-50
Serum Creatinine (mg/dl)	0.9	0.6-1.4
Sodium (mmol/L)	146	133-150
Potassium (mmol/L)	4.2	3.5-5.0
Calcium (mg/dl)	8.2	8.4-10.2

Table-I. Blood investigations of the patient

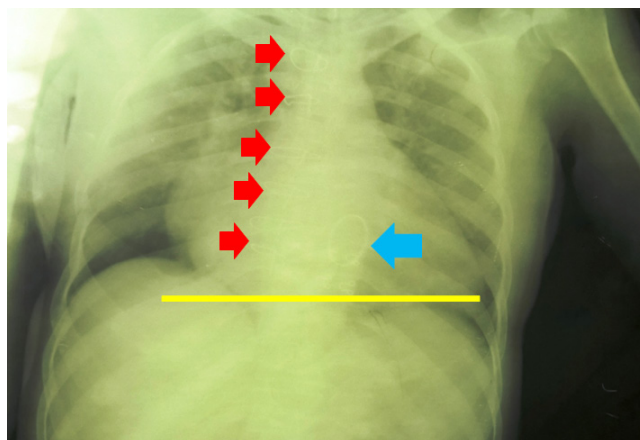


Figure-3. Chest X ray of the patient

While the overall aim of treatment for CVT is to improve outcome, the immediate objectives are to re-canalize the thrombosed sinus/vein, to limit the spread of thrombus to the bridging veins, to treat any underlying state causing thrombosis and to prevent CVT recurrence. Management with anticoagulation or thrombolytic therapy is usually done however there is a risk of increase in intracranial hemorrhage with anticoagulation. Existing data recommends using systemic anticoagulation even in presence of cerebral hemorrhage.^{5,6} Initial therapy should be done with unfractionated or low molecular weight heparin and subsequent maintenance with warfarin three to six months (transient underlying cause) or lifelong (prothrombotic underlying cause and recurrent cases) aiming at an INR of 2-3.⁵ Thrombolytic therapy by local instillation with microcatheter or direct instillation during surgical thrombectomy is not routinely done.⁶ To control raised intracranial pressure acutely or impending herniation, decompressive surgery might be done. Effectiveness and safety of Rivaroxaban has not been determined in CVT yet.⁷

Temporary anticoagulation should be done in pregnant women who have had CVT with a prothrombotic state or additional thromboembolism.⁸ A reasonable regimen is subcutaneous low-molecular-weight heparin beginning in the third trimester and continuing up to eight weeks postpartum.⁸ For adolescent girls and adult women with a history of CVT, not using oral contraceptives has been recommended.⁸

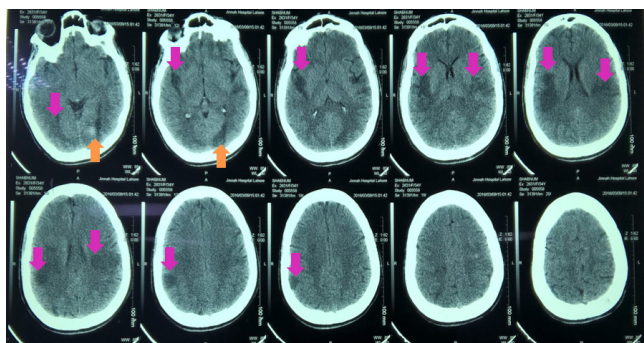


Figure-1. CT scan Brain of the patient

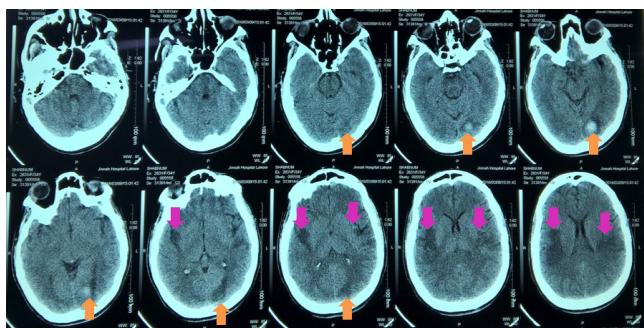


Figure-2. CT scan Brain of the patient

The initial goals when patients present with stroke include ensuring vitals' stability, rapidly reversing conditions contributing to illness, identifying pathophysiologic basis of neurologic symptoms and looking for any thrombolysis contraindications. Timely restoration of blood flow using thrombolytic therapy (tissue plasminogen activator, tPA) is an effective method to salvage ischemic brain tissue that has not infarcted already.⁹ However tPA administration should be done in <4.5 hours after onset of symptoms. Early (within 48 hours) initiation of aspirin (160 to 300 mg daily) has shown benefit for the treatment of acute ischemic stroke without increasing risk of hemorrhagic transformation and improves prognosis long-term.⁹ However aspirin should not be given for the first 24 hours following thrombolysis. Only preliminary evidence is available concerning the use of other antiplatelet agents (dipyridamole, ticlopidine, clopidogrel) immediately after acute ischemic stroke or TIA.

Oral anticoagulation for secondary stroke prevention has been recommended in patients with atrial fibrillation who have intra-cardiac thrombus associated with mechanical heart valves.¹⁰ Due to risk of hemorrhage, the timing of anticoagulation initiation is dependent upon infarct size. Infarcts larger than one-third of middle cerebral artery territory or one-half of posterior cerebral artery territory on CT or MRI imaging are considered large and are associated with high risk of bleeding and anticoagulation should be withheld for 2 weeks.¹¹ In small or moderate infarcts, anticoagulation with warfarin may be commenced after 24 hours of admission.¹¹ In cardio-embolic patient with ischemic stroke on warfarin, the dose is often sub-therapeutic and warfarin should be continued to keep INR in therapeutic range of 2.0-3.0. Lacunar infarcts are due to small cerebral artery disease and may occur with a therapeutic INR and increasing target INR to 2.5- 3.5 is indicated. Control of hypertension is an important component of the management of patients with atrial fibrillation who have had a stroke. Angiotensin converting enzyme (ACE) inhibitors reduce risk of warfarin-associated intracranial hemorrhage and stroke recurrence.¹²

The 5 major issues after prosthetic heart valve replacement include anti-thrombotic therapy, evaluation of valve functioning and durability, prophylaxis for infective endocarditis, exercise safety and guidance about pregnancy.¹³ Anticoagulation to prevent valve thrombosis and thromboembolism should be started with warfarin immediately after valve replacement and needs meticulous monitoring with 2-3 INR measurements per week initially. Subsequently INR is measured once a month when the patient is stable with warfarin dose adjustment as required to maintain INR.¹³ To achieve a therapeutic effect for warfarin, up to 5 days of treatment are usually necessary. Short-term bridging treatment with intravenous unfractionated heparin or subcutaneous low-molecular-weight heparin is indicated. In conclusion, lifelong warfarin should be given in patients after MVR with mechanical valves keeping a target INR of 2.5-3.5. Continuous monitoring of PT/INR is recommended. Warfarin is teratogenic and safety of rivaroxaban is uncertain, hence these should not be given in the 1st trimester of pregnancy. Heparin, preferably LMWH, should be prescribed in 1st trimester of pregnancy and two-weeks prior to delivery. Imaging for CVT should be performed in cases of cerebral infarction which cross typical arterial boundaries or intra-cerebral hemorrhage of undetermined origin.





Copyright© 20 June, 2022.

REFERENCES

1. Devasagayam S, Wyatt B, Leyden J, Kleinig T. **Cerebral venous sinus thrombosis incidence is higher than previously thought: A retrospective population-based study.** *Stroke.* 2016 Sep; 47(9):2180-2. doi: 10.1161/STROKEAHA.116.013617.
2. Bousser M-G, Ferro J. **Cerebral venous thrombosis: An update.** *Lancet Neurol.* 2007; 6:162-70.
3. Silvis SM, de Sousa DA, Ferro JM, Coutinho JM. **Cerebral venous thrombosis.** *Nat Rev Neurol.* 2017 Sep; 13(9):555-565. doi: 10.1038/nrneurol.2017.104.

4. Saposnik G, Barinagarrementeria F, Brown RD Jr, Bushnell CD, Cucchiara B, Cushman M, et al. **American heart association stroke council and the council on epidemiology and prevention. Diagnosis and management of cerebral venous thrombosis: A statement for healthcare professionals from the American Heart Association/American Stroke Association.** Stroke. 2011 Apr; 42(4):1158-92. doi: 10.1161/STR.0b013e31820a8364.
5. Linkins L-A, Choi P, Douketis J. **Clinical impact of bleeding in patients taking oral anticoagulant therapy for venous thromboembolism: A meta-analysis.** Ann Intern Med. 2004; 139:893–900.
6. Wasay M, Khan M, Rajput HM, Farooq S, Memon MI, AlRukn SA, et al. **New oral anticoagulants versus warfarin for cerebral venous thrombosis: A multi-center, observational study.** J Stroke. 2019 May; 21(2):220-223. doi: 10.5853/jos.2019.00150.
7. Landman GW, Gans RO. **Oral rivaroxaban for symptomatic venous thromboembolism.** N Engl J Med. 2011 Mar 24; 364(12):1178. doi: 10.1056/NEJMc1100734.
8. Mani H, Lindhoff-Last E. **New oral anticoagulants in patients with nonvalvular atrial fibrillation: A review of pharmacokinetics, safety, efficacy, quality of life, and cost effectiveness.** Drug Des Devel Ther. 2014; 8:789–98.
9. del Zoppo GJ, Poeck K, Pessin MS, Wolpert SM, Furlan AJ, Ferbert A, et al. **Recombinant tissue plasminogen activator in acute thrombotic and embolic stroke.** Ann Neurol. 1992 Jul; 32(1):78-86. doi: 10.1002/ana.410320113.
10. Kalus JS. **Antithrombotic alternatives for stroke prevention in atrial fibrillation: Critical differences and remaining questions.** Drugs Context. 2013; 2013:212251.
11. Canaple S, Bogousslavsky J. **Multiple large and small cerebellar infarcts.** J Neurol Neurosurg Psychiatry. 1999 Jun; 66(6):739-45. doi: 10.1136/jnnp.66.6.739.
12. Çoban E, Kirbaş D, Atakli D, Soysal A. **Efficacy and safety of warfarin experience in a stroke polyclinic in stroke patients.** Noro Psikiyatrs Ars. 2017 Dec; 54(4):318-321. doi: 10.5152/npa.2016.15951.
13. Tan CSY, Fong AYY, Jong YH, Ong TK. **INR control of patients with mechanical heart valve on long-term warfarin therapy.** Glob Heart. 2018 Dec; 13(4):241-244. doi: 10.1016/j.gheart.2018.08.003.

AUTHORSHIP AND CONTRIBUTION DECLARATION

No.	Author(s) Full Name	Contribution to the paper	Author(s) Signature
1	Nauman Ismat Butt	Study conception, Data collection, manuscript writing.	
2	Fahmina Ashfaq	Literature review, Manuscript writing and revising.	
3	Sabeen Aftab	Literature review, Data collection, Manuscript writing.	
4	Khalid Mahmood	Study conception, Manuscript writing and revising.	
5	Ali Anwar	Literature review, Data collection, Manuscript writing.	