



An unusual case of maxillary permanent 1st molar with two pulp canals with pulp necrosis; diagnosis and endodontic management.

1. BDS,
FCPS Resident Operative Dentistry
Liaquat University of Medical &
Health Sciences, Jamshoro.
2. BDS,
MSc Resident Operative Dentistry
Liaquat University of Medical &
Health Sciences, Jamshoro.
3. BDS, FCPS
Professor Operative Dentistry
Dean Institute of Dentistry,
LUMHS, Jamshoro.

Correspondence Address:

Dr. Sarang Suresh Hotchandani
Department of Operative Dentistry
Liaquat University of Medical &
Health Sciences, Jamshoro.
hotchandani@hotmail.com

Article received on:

16/08/2021

Accepted for publication:

09/10/2021

Sarang Suresh Hotchandani¹, Priya Rani Harjani², Feroze Ali Kalhoro³

ABSTRACT... The present case report highlights the need to identify variations in root canal anatomy as a prerequisite for effective nonsurgical root canal therapy planning. As clinicians, we need to develop our observational and clinical abilities as well as amend our understanding of the complexities of the canal anatomy. Reports describing the structure of teeth and pulp canals rarely report the presence of two pulp canals in two permanent upper 1st molars. In this case, it describes the nonsurgical root canal therapy of the upper right 1st permanent molar with two pulp canals, which was confirmed by a cone beam.

Key words: Aberration, Anatomy, Incidence, Molar, Manuscript, Root Canal Structure, Tooth Anatomy.

Article Citation: Hotchandani SS, Harjani PR, Kalhoro FA. An unusual case of maxillary permanent 1st molar with two pulp canals with pulp necrosis, diagnosis and endodontic management. Professional Med J 2021; 28(11):1687-1691.
<https://doi.org/10.29309/TPMJ/2021.28.11.6747>

INTRODUCTION

Understanding the shape of the pulp canal and the root of teeth is a crucial requirement for efficacious nonsurgical root canal therapy. Failure to find, disinfect, and fill all accessible pulp canals is the main reason for the failure of nonsurgical root canal therapy. Structure of pulp canals of the upper 1st molar permanent has been described in detail in the literature regarding the number of roots and pulp canals.

Vertucci¹ classified root canal systems into eight types; Type 1: 1 pulp canal runs from the pulp chamber to the apical orifice, Type 2: 2 pulp canals merge into one exit, Type 3: Single canal runs from the pulp chamber and divides into 2 parts which then merged into 1 afore leaving apex, Type 4: The 2 canals run separately, Type 5: Single canal is divided into two canals before exiting, Type 6: 2 pulp canals merge into 1 and then split into 2 afore reaching apex, Type 7: Single canal from the pulp chamber separates into and reconnects into 1 along its route and rifts into 2 parts afore leaving the apex and Vertucci Type 8: 3 pulp canals exit separately from each other at apex.

Blaine et al.² have reported in a review that 96.2% permanent upper 1st molars have 3 roots and 4 pulp canals including Mesio Buccal root which contain 2 canals, while the other two roots contain one canal each and a prevalence of 3.8% for two canals in the permanent upper 1st molars. In his overview, he also showed that fusion of distobuccal and palatal roots were found in 5.2% cases in the review while fusion between mesio Buccal and distobuccal root was found in a rare case. Other configurations of root and pulp canals include one, five, six, seven³ and C shaped configuration of canals.^{4,5}

In this case, it has been reported that the Vertucci type 1 root canal configuration with one buccal root and canal confirmed by cone-beam computed tomography successfully treated the first permanent upper molar.

Case Report

A 35 year old working female consulted to the department of operative dentistry, Institute of Dentistry, Liaquat University of Medical & Health Science, Jamshoro, Sindh, Pakistan. Her upper 1st molar had pain for 3 days which was aggravated

by biting with food relieved by over-the-counter analgesics. The patient's medical history did not contraindicate the root canal treatment.

Extra oral examination was insignificant. Intra oral clinical examination revealed multiple restorations. Upper right 1st molar examination revealed a gross carious lesion on the mesio occlusal surface adjacent the crown of tooth UR5. Tenderness on palpation and percussion was present in the vertical direction. The UR6 was unresponsive to cold tests and electric pulp test. Pre-operative periapical radiographic examination revealed gross radiolucency on the mesial aspect of UR6 with one root visible, while cone shift revealed two roots with PDL widening around the roots. After diagnosis of pulp necrosis with symptomatic apical periodontitis non-surgical root canal treatment of tooth UR6 followed by permanent crown restoration was advised.

After acceptance and consent by the patient, nonsurgical root canal treatment was initiated with infiltration under local anesthesia. Caries driven access cavity was prepared, and no bleeding was observed in canals confirming the diagnosis of pulp necrosis. After deroofting the pulp chamber, the pulpal floor map revealed two canals buccal & palatal, after cleaning the pulp chamber with 2.5% sodium hypochlorite and EDTA to remove dentinal chips search for other canals initiated under Loupes with 3.5x magnification (ZUMAX MEDICAL CO.) canal orifices were opened with SX rotary protaper files (Dentsply Sirona). (Figure-1) To confirm the presence of two canals and prevent inadvertent search of canals by damaging the tooth structure, CBCT was obtained which showed unilateral #3 with fusion of buccal roots and presence of one canal in each root (Buccal & palatal). (Figures-2 & 3) In the present case, the canal pattern evident in each of the two roots was Vertucci's Type 1 canal conformation.

After pulpectomy and orifice opening with SX rotary protaper file, the working length was determined by Woodpex III apex locator (Guilin Woodpecker Medical Instrument Co., Ltd) and confirmed with a periapical radiograph (Figure).

Buccal canal was enlarged with an initial apical file of ISO no.35 H – File and the palatal canal with ISO no.30 H – file. Canal preparation was performed using crown down with Manual ISO file up to the size of 50 in buccal canal and a size of 45 in the palatal canal using 2.5% sodium hypochlorite as irrigant and normal saline as final irrigant. Obturation of both pulp canals were done with ISO gutta percha cones (GAPADENT'S Gutta Percha) with Sealapex (Kerr Endodontics) as a sealer for cold lateral compaction. The chamber was restored with direct composite restoration and the patient was advised for crown. The patient was asymptomatic on follow-up.

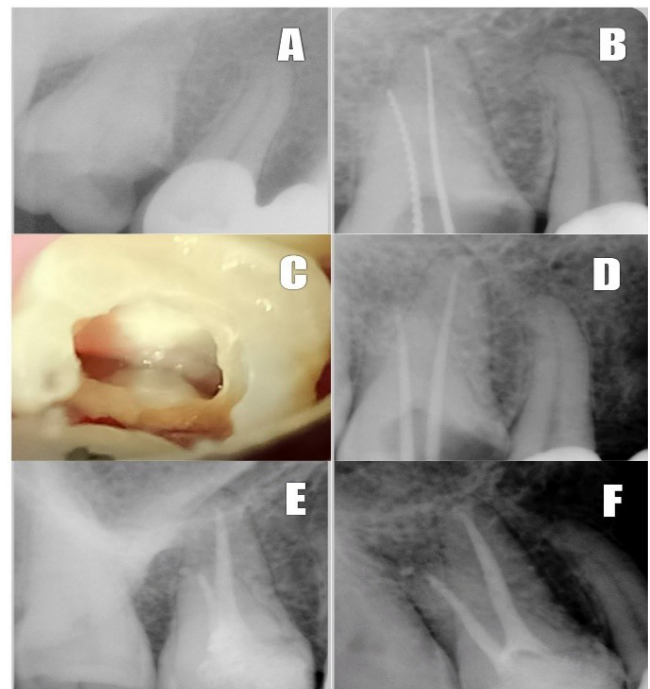


Figure-1. (A) Preliminary radiograph of the right upper 1st molar with one root on the buccal aspect (A); Working length determination (B); Two openings identified in the bottom of the pulp chamber (C); Master cone confirmation (D); Post obturation radiograph with cone shift (E & F).

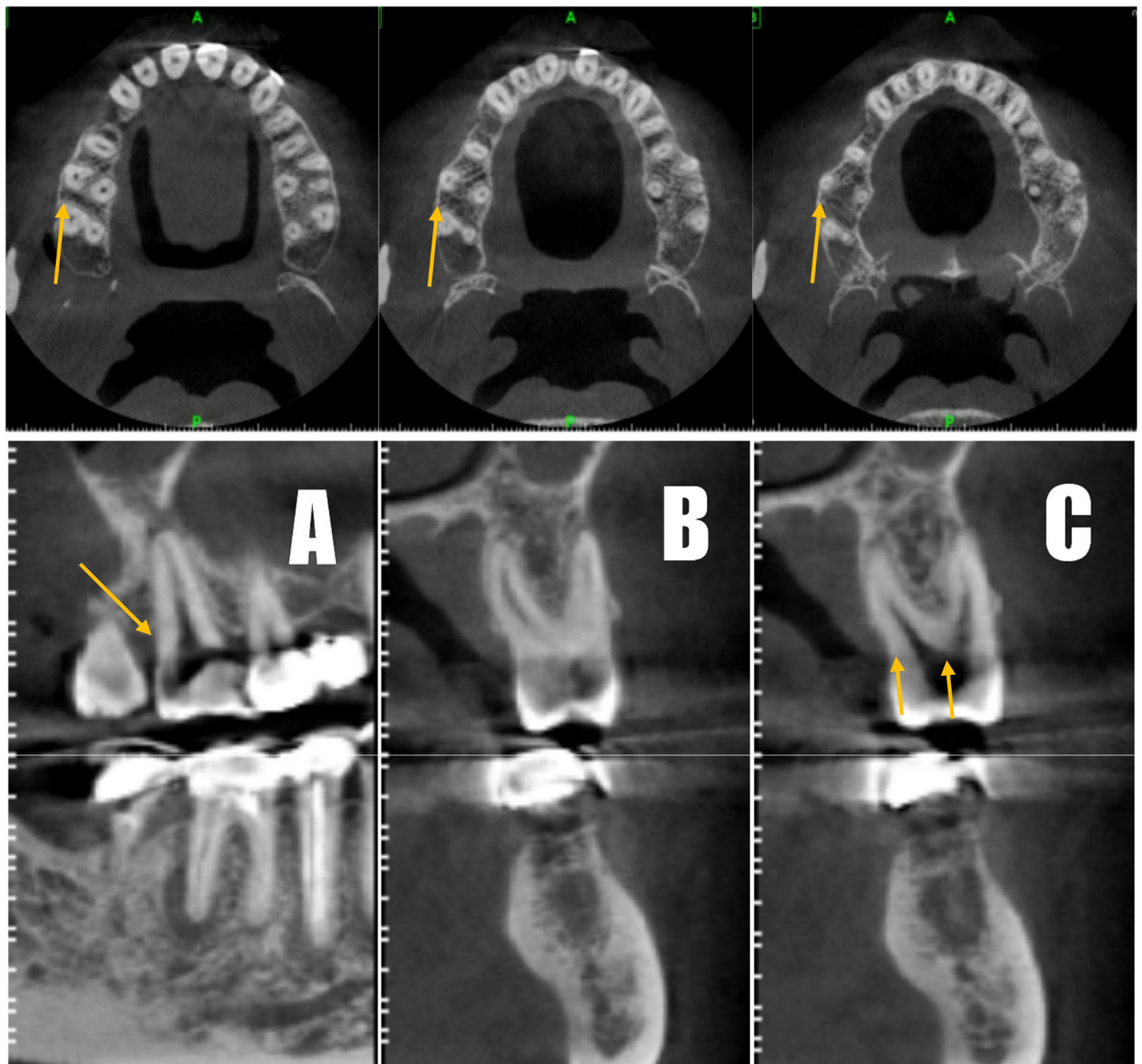


Figure-2. Axial View CBCT; Coronal, Middle & Apical third shows 2 orifices A) Sagittal View showing one root on the buccal aspect of the upper right 1st molar; B & C) Coronal View 2 Roots and 2 canals with Vertucci type 1 Configuration in all aspects.

DISCUSSION

The exact position of all canals in their roots requires the use of Dental Loupes, Dental Operating Microscope and CBCT and other angled radiographs and insight into the anatomy of roots. Many reports have evaluated the root and root canal structure of the 1st permanent upper molar because as Burns⁶ described permanent upper 1st molar is “arguably the most

treated, least understood, posterior tooth.” The most common anatomical structures of the upper 1st molars are three pulp canals (96.2%) and three to four pulp canals (98.32%).⁷ Therefore, reports on the changes of the 1st molars mainly focused on the MB2 structure and multiple canal recognition. There are few reports of two canals in the 1st molars of the upper jaw.

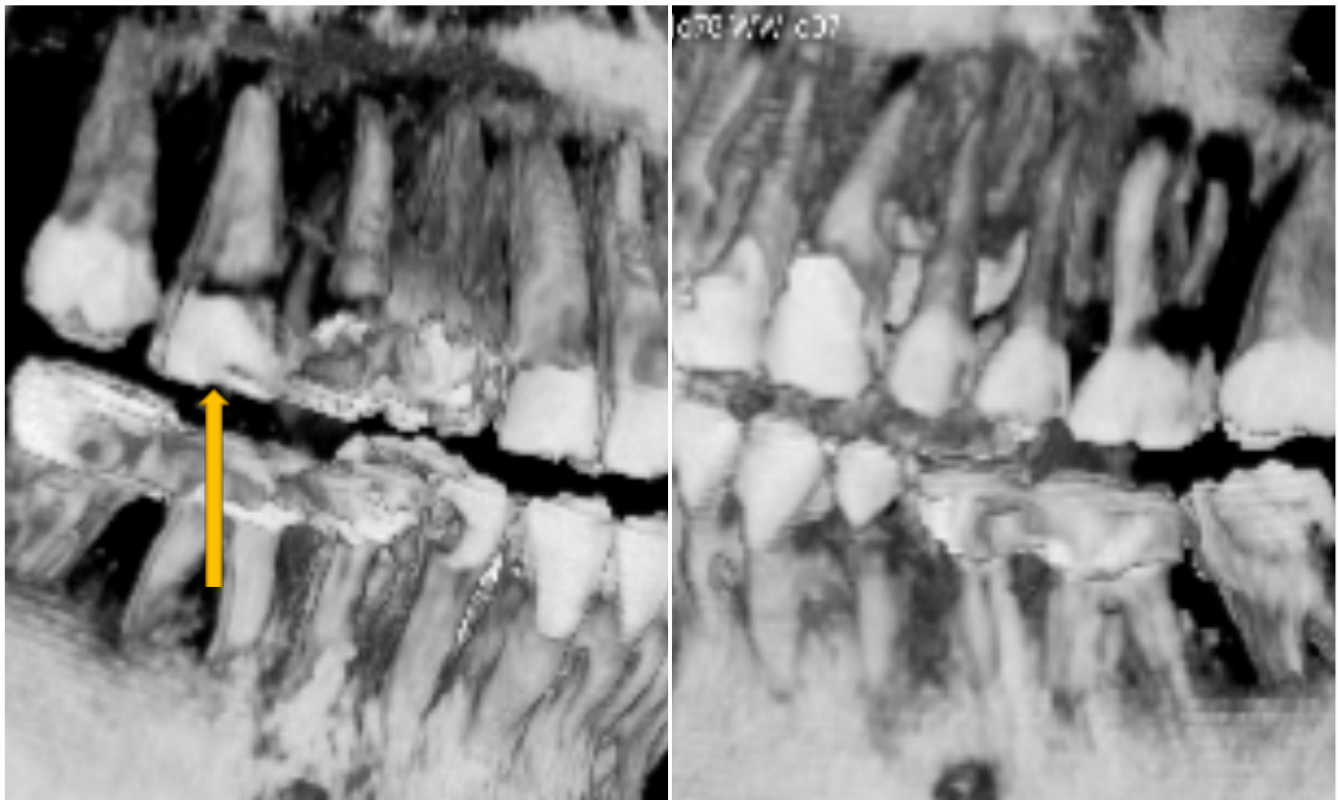


Figure-3. 3D CBCT View; right & left showing the right upper 1st molar with one root on buccal aspect (arrow) while left upper 1st molar with two roots on buccal aspect.

In teeth with multiple roots, the epithelial diaphragm is natively programmed to undergo differential growth, but occasionally, this failure of differential growth occurs which results in the formation of a smaller number of roots/fused roots in the tooth. Fusion of mesio-buccal and distobuccal roots is reported to be a typical anomaly with 0.4% - 1.3% prevalence in upper permanent 1st molars.⁸ The incidence of occurrence of two rooted teeth was reported at 3.8% with type 1 (1%).⁹ In this report, the patient's CBCT image showed two different roots separated from each other, one on the buccal side while the other on the palatal. Two pulp canals opened from one chamber and have their own apex. On the upper 1st molar, the fusion can be divided into three types: the fusion of the distobuccal root (DB) and the palatal root (P) (type A), and the fusion of buccal roots (type B). Fusion with two palatal roots (Type C).¹⁰ In this study, there was a fusion between MB and DB roots (type B) based on the position of the root canal.

Plotino et al. stated in his report that the percentage of symmetry between the left and right root and root canal anatomy is between 70% to 81%.¹¹ Therefore, it is interesting that in our case, the structure of each upper 1st molar is asymmetrical to the structure of the opposite side. This asymmetry is rarely seen in the literature. For most patients, it is important to check the contralateral teeth, which is essential for the management of the contralateral teeth for nonsurgical root canal therapy.

CONCLUSION



The current case article discourses the nonsurgical and non-surgical root canal therapy of an infrequent example of an upper permanent 1st molar with two roots along with two pulp canals and focusses the function of CBCT as a confirmative diagnostic instrument for root canal structure.

Copyright© 09 Oct, 2021.

REFERENCES

- Bansal R, Hegde S, Astekar MS. **Classification of root canal configurations: A review and a new proposal of nomenclature system for root canal configuration.** [Internet]. 2018 May [Cited January 4, 2021]; 12(5):ZE01-ZE05. DOI: 10.7860/JCDR/2018/35023.11615
- Cleghorn BM, Christie WH, Dong CC. **Root and root canal structure of the human permanent maxillary 1st molar: A literature review.** J Endod. 2006 Sep; 32(9):813-21. doi: 10.1016/j.joen.2006.04.014. Epub 2006 Jun 30. PMID: 16934622.
- Umer F, Nazeer MR, Adnan S. **A maxillary molar with seven canal orifices; An endodontic rarity.** J Pak Dent Assoc 2017; 26(1): 39-43.
- Gopikrishna V, Bhargavi N, Kandaswamy D. **Endodontic management of a maxillary 1st molar with a single root and a single canal diagnosed with the aid of spiral CT: A case report.** J Endod. 2006 Jul; 32(7):687-91. doi: 10.1016/j.joen.2005.10.057. Epub 2006 Apr 4. PMID: 16793482.
- Dankner E, Friedman S, Stabholz A. **Bilateral C shape configuration in maxillary 1st molars.** J Endod. 1990 Dec; 16(12):601-3. doi: 10.1016/S0099-2399(07)80204-4. PMID: 2094764.
- Burns RC, Herbranson EJ. **Tooth structure and cavity preparation.** In: Cohen S, Burns RC, editors. **Pathways of the Pulp.** 8th ed. St. Louis: Mosby, An Imprint of Elsevier; 2002. p. 173-229.
- Ghobashy AM, Nagy MM, Bayoumi AA. **Evaluation of root and canal structure of maxillary permanent molars in an Egyptian population by cone-beam computed tomography.** J Endod. 2017 Jul; 43(7):1089-1092. doi: 10.1016/j.joen.2017.02.014. Epub 2017 May 2. PMID: 28476465.
- Sabala CL, Benenati FW, Neas BR. **Bilateral root or root canal aberrations in a dental school patient population.** J Endod. 1994 Jan; 20(1):38-42. doi: 10.1016/s0099-2399(06)80025-7. PMID: 8182385.
- Neelakantan P, Subbarao C, Ahuja R, Subbarao CV, Gutmann JL. **Cone-beam computed tomography study of root and canal structure of maxillary first and second molars in an Indian population.** J Endod. 2010 Oct; 36(10):1622-7. doi: 10.1016/j.joen.2010.07.006. Epub 2010 Aug 30. PMID: 20850665.
- Liu J, Que KH, Xiao ZH, Wen W. **Endodontic management of the maxillary 1st molars with two pulp canals: A case report and review of the literature.** World J Clin Cases. 2019 Jan 6; 7(1):79-88. doi: 10.12998/wjcc.v7.i1.79. PMID: 30637256; PMCID: PMC6327126.
- Plotino G, Tocci L, Grande NM, Testarelli L, Messineo D, Ciotti M, Glassman G, D'ambrosio F, Gambarini G. **Symmetry of root and root canal structure of maxillary and mandibular molars in a white population: A cone-beam computed tomography study in vivo.** J Endod. 2013 Dec; 39(12):1545-8. doi: 10.1016/j.joen.2013.09.012. Epub 2013 Oct 15. PMID: 24238444.

AUTHORSHIP AND CONTRIBUTION DECLARATION

No.	Author(s) Full Name	Contribution to the paper	Author(s) Signature
1	Sarang Suresh Hotchandani	Conceived and designed the study, Conducted research, provided research materials and collected and organized data.	
2	Priya Rani Harjani	Wrote initial and final draft of article.	
3	Feroze Ali Kalhoro	Analyzed and interpreted data.	