



ORIGINAL ARTICLE

## Sonographic correlation of portal vein diameter with gender in population of Lahore.

Sibgha Aqeel<sup>1</sup>, Shurooq Amjad<sup>2</sup>, Javed Tauqir<sup>3</sup>, Mehreen Fatima<sup>4</sup>

**Article Citation:** Aqeel S, Amjad S, Tauqir J, Fatima M. Sonographic correlation of portal vein diameter with gender in population of Lahore. Professional Med J 2022; 29(5):607-612. <https://doi.org/10.29309/TPMJ/2022.29.05.6543>

**ABSTRACT... Objective:** To determine the reference values of normal portal vein diameter in correlation to gender in population of Lahore. **Study Design:** Cross Sectional study. **Setting:** Ultrasound Lab University of Lahore and Gondal Complex Lahore. **Period:** 5<sup>th</sup> October 2020 to 13<sup>th</sup> April 2021. **Material & Methods:** Sample size of my study were 164 males and 143 females. Simple random sampling was conducted. Healthy Individual with normal body mass index, both (male and female) individuals in fasting state and age between (20-25) years. Individual with history of portal hypertension, Fatty liver, Hepatomegaly and any other hepatic disorder. Xario XG. Convex 3.5 MHz-7.5MHz. **Results:** The mean diameter of portal vein for male was calculated as 10.51 + 1.468 mm (ranging from 13mm to 15mm), and for females was 10.085 ± 1.336 mm (ranging from 7 to 14mm). Independent t-test was applied to examine the difference of mean Portal vein in males and females. We found a statistical significant difference in two means of portal vein diameter as the p-value = 0.008 is less than  $\alpha = 0.05$ . **Conclusion:** In this study, portal vein diameter in adult men and women were found within the normal range among age limit 20-25years. But the diameter of portal vein showed direct relation with weight and Body Mass Index among females but in males none of the body factors had any impact on the diameter of portal vein.

**Key words:** BMI, Portal Vein Diameter, Portal Hypertension.

### INTRODUCTION

Blood supply of the liver is mutually shared by Portal vein and Hepatic artery almost 70-75% of hepatic blood supply is drained from portal vein of liver rest of the blood circulation is conducted by hepatic artery.<sup>1</sup> Most of the blood supply of the liver is supplied by the portal vein plus portal vein has its own clinical significance as thickness of the portal vein helps in the diagnosis of the hypertension of portal vein.<sup>2,3</sup> Portal vein is the combination of the two major veins one is superior mesenteric and second is splenic behind the neck of the pancreas at the level of 2<sup>nd</sup> lumbar vertebrae.<sup>5</sup> size of the trunk of the portal vein is 5cm to 7cm.<sup>4,5</sup> Radiological findings helps in diagnosing the patients whom are suffering from portal hypertension as the diameter of the portal vein is changed.<sup>6,7</sup> The convoluted link among the portal vein and the liver is responsible for maintain the homeostasis of the body.<sup>8</sup> It is the communication or important channel through

which blood is transmitted to the capillaries of the spleen to the capillaries of intestinal wall of the hepatic sinusoids.<sup>9</sup> Triad of the portal vein contains some branches of hepatic artery, portal vein and bile duct packed in a protective sheath of connective tissues which gives an echogenic walls appearance in liver sonography<sup>10,11</sup> Blood drain from the portal vein is lower part (abdominal part) of the alimentary canal except spleen, pancreas, gall-bladder and lower portion of the rectum.<sup>12</sup>

Portal vein diameter normally varies from the 7 to 16 mm and normal venous pressure is lies between the 5 and 10mmHg (almost 14cm of H<sub>2</sub>O) but if this pressure (venous pressure) is increases from 16 mmHg (30cm of H<sub>2</sub>O) then it indicates that patient is suffering from Portal hypertension.<sup>13,14</sup> As many studied showed that if portal vein diameter is 13mmHg then it is normal but many other studies shows that if PVD

1. Medical Imaging Doctor, Student, University Institute of Radiological Science and MUT.  
2. MB ch B (Iraq), MSDU (UOL), Senior Lecturer, Faculty of Allied Health Sciences, University Institute of Radiological Science and MIT.  
3. Medical Imaging Doctor, Lecturer, Faculty of Allied Health Sciences, University Institute of Radiological Science and MIT.  
4. M.Phil, Assistant Professor, University Institute of Radiological Science and MIT.

**Correspondence Address:**

Dr. Sibgha Aqeel  
Student Medical Imaging Doctor,  
University Institute of Radiological Science  
and MUT.  
sibgha.aqeel@outlook.com

**Article received on:** 19/04/2021  
**Accepted for publication:** 27/10/2021

is more than 10mmHg then it indicates a portal hypertension and this causes confusion the exact cutoff value of portal vein diameter.<sup>15</sup>

Sonographic measurements and about findings are the major findings in the diagnosis of portal hypertension among patients. As ultrasound or sonographic measurements shows much more accurate and reliable results.<sup>16</sup> The most common irregularity in the form of increase or decrease in the value of portal vein diameter leads a condition called Portal vein hypertension. Portal hypertension is defined as it is a dominant clinical disorder caused by the increase in the cutoff value of portal venous pressure which leads to the limitation of blood flow through vein into the hepatic circulation.<sup>17</sup> Portal hypertension leads to other clinical conditions such as enlargement of spleen known as splenomegaly, dilation of portal veins and formation of different collateral channels at different sites which leads to increasing the mortality and morbidity rate among population as they all conditions leads to severe chronic liver disease that is Liver cirrhosis.<sup>18,19</sup> Ultrasound is essential in evidence on the problem of the gathering venous portal system in all related patients suffering with different medical disorders for example prolonged(chronic) disease of liver disease and portal hypertension. The increase in the size and thickness of the portal vein is revealing of portal hypertension. The vein as well distends in schistosomiasis with mutable degree of peri-portal thickening.<sup>20</sup>

Portal hypertension is defined as increase in the gradient between the hepatic veins and portal vein if the diameter rises from more than 13mmHg main contributing factor is increasing diameter of portal vein.<sup>21,22</sup> It is classified in various ways so it is easy to distinguish between them different types are intrahepatic, extra-hepatic and hyper-dynamic. As researches showed that extra-hepatic and hyper-dynamic portal hypertension are less common as compared to intrahepatic portal hypertension.<sup>23</sup>

Portal vein study play key role in spotting many medical situations. However sonographic examination helps in the detail study of normalities

and abnormalities of the portal vein. This evidence may be predominantly important in identifying and assessing patients with symptoms of portal hypertension.<sup>24,25</sup>

In our study we will determine the reference values of normal portal vein diameter in correlation to gender in the population of Lahore. This standard local values will be helpful in prompting and management of portal hypertension. Diagnostic tool is used for the measurement of the portal vein diameter is sonography i.e. ultrasound. The gap of my study is too small sample size because of the shortage of time and present COVID-19 pandemic and this research is conducted on small level data is only taken from Lahore. So authenticity of the research enhanced and suggested to further researchers that work on this topic on higher level.

## **MATERIAL & METHODS**

The study was a cross-sectional convenient sampling study design from October 2020 to April 2021. The study was conducted on three-hundred and seven patients in the Department of Radiology. UIRS MST. UOL and Radiology Department of Shadara Teaching Hospital, Lahore Pakistan.

### **Sample Selection**

#### **Inclusion Criteria**

- Healthy Individual with normal body mass index,
- male and females healthy individuals in fasting state
- Age between 20-25 years.

#### **Exclusion Criteria**

- Individual with history of portal hypertension
- Chronic liver disease
- Individuals in non-fasting state
- Hepatomegaly.

### **Sampling Technique**

Convenient sampling

### **Scanning Technique**

Participants were examined early in the morning in

fasting state in the supine position. For measuring the diameter of portal vein using a transducer with frequency of 3.5MHZ which is placed diagonally at the region of 2<sup>nd</sup> lumbar vertebrae at sub-costal region with minor modifications. While imagining will be optimal, readings of the portal vein diameter was reserved in soft respiration condition just before the entry of the portal vein into the liver. Measurements were attained in mm unit.

**RESULTS**

Total 307 patients were included in the study 143 patients (46.5%) were female and 164(53.4%) patients were male in order to determine the portal vein diameter by taking variables i.e. gender, BMI, age, weight and height using ultrasound as a diagnostic tool.

The mean + S.D diameter of portal vein for male was calculated as 10.51 + 1.468 mm (ranging from 7.30 to 15), and for females was 10.085 ±1.336 mm (ranging from 7 to 14). Independent t-test was applied to examine the difference of mean Portal vein in males and females. We found a statistical significant difference in two means of portal vein diameter as the p-value = 0.008 is less than α =0.05.

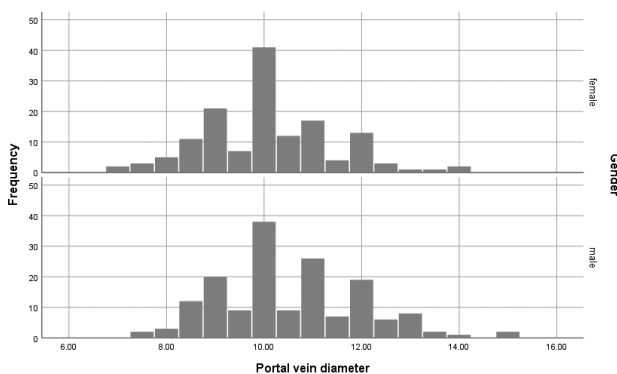


Figure-1. Portal vein diameter

Table-I. Portal Vein Diameter

Gender	Mean	N	Std. Deviation	Minimum	Maximum
Female	10.0846	143	1.33555	7.00	14.00
Male	10.5104	164	1.46822	7.30	15.00
Total	10.3121	307	1.42171	7.00	15.00

Table-II. Descriptive statistics of weight height and BMI in males and females

Gender		Weight	Height	BMI
Female	Mean	56.1958	164.6392	20.9769
	N	143	143	143
	Std. Deviation	4.90079	6.89433	2.13160
	Minimum	45.00	155.20	14.04
	Maximum	70.00	179.80	28.99
Male	Mean	61.5183	168.2116	21.9613
	N	164	164	164
	Std. Deviation	5.39651	7.81319	2.18951
	Minimum	50.00	154.90	16.54
	Maximum	75.00	185.90	26.62
Total	Mean	59.0391	166.5476	21.5028
	N	307	307	307
	Std. Deviation	5.80780	7.60008	2.21452
	Minimum	45.00	154.90	14.04
	Maximum	75.00	185.90	28.99

**DISCUSSION**

A cross-sectional gray scale sonographic assessment of the portal vein in Lahore population was done, age of the both gender varies starting from 20 to 25years. The mean diameter of portal vein was calculated as 10.01 ±1.8 mm (range 8.2 to 11.8). Thus findings determined that sexual category either male or female have not any influence on the portal vein diameter perhaps increasing the age directly effects the diameter so diameter of the individual is increased.<sup>26,27</sup> Successively, the identical findings also testified in the population of Nigeria forming the average portal vein diameter was measured as 11.46 ± 1.46 mm and also concluding that the diameter differs with increasing age but not affected with opposite gender.<sup>28,29</sup> A second research was conducted in Iran by using most accurate and advanced imaging technique that is Doppler ultrasound on sample size of thirty-seven healthy individuals. The age of the subjects were varied from the age of 20-40 years and the average portal vein diameter was measured as 9.46 ± 1.75 mm estimated the same results PVD increases with increase in age not affected by gender.<sup>30,31</sup> In recent study, the

portal vein diameters in males and females were measured as  $9.18 \pm 2.43$  mm and  $8.65 \pm 1.91$  mm respectively. They extended from 4.50 to 16.80 mm and 4.10 to 13.10 mm in men and women correspondingly. The mean diameter was more in males than females, though there were no statistical significant changes found in gender distribution.<sup>32,33</sup>

In the previous study, in males there was no relationship amongst diameter of portal vein and age of the healthy subjects, indicating that PVD does not differ with the age. But, height had a correlation with portal vein diameter.<sup>34,35</sup> With increase in height PVD proportionately increases.<sup>36,37</sup> In females there is no correlation between portal vein diameter and age as well as height, indicating that portal vein diameter had not varied with the age and height. In this present study, portal vein diameter had changed significantly with increasing weight and BMI.<sup>38,39</sup> In males, none of the body parameters were significantly correlated with portal vein diameter. But in females, though height was not correlated with the diameter but it was significantly correlated with increasing weight and BMI. Increasing age, weight and height proportionally affect the portal vein diameter mainly in females rather than males in one previous study researcher also concluded that The mean diameter increased from 15 to 60 years but gradually decreased after 60 years in males. But in females the diameter increased up to 60 years, after that remained almost similar.<sup>40</sup>

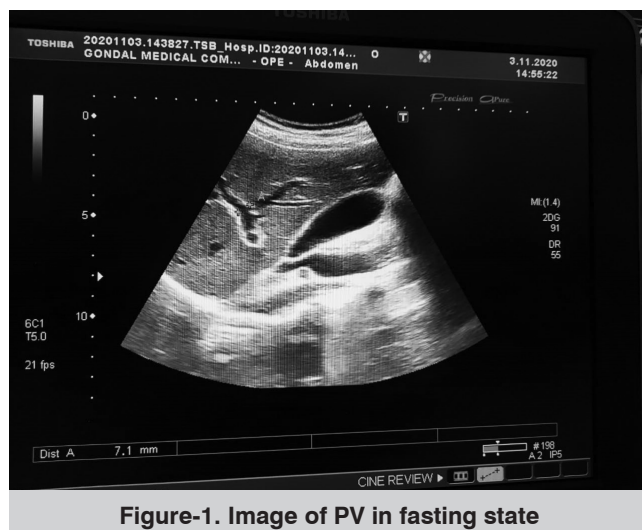


Figure-1. Image of PV in fasting state

## CONCLUSION

In this study, portal vein diameter in adult male and female determine the significant correlation with gender hence gender will be affected. But the diameter of portal vein linked with weight and Body Mass Index in all females but in males none of the body factors had any impact on the diameter of portal vein considerably. Therefore, portal vein diameter showed as reference significance among local population for evaluating differences of size of portal vein in diagnosing in clinical set up. Increase in the diameter of portal vein leads to portal hypertension so early detection of the condition helps in good recovery and prognosis.

Copyright© 27 Oct, 2021.

## REFERENCES

1. Bhattacharya J, Das A, Bhowmik A. **Sonographical assessment of portal vein diameter in Northern Part Of West Bengal, India. Octa Journal of Environmental Research.** 2013; 1(3).
2. Hawaz Y, Admassie D, Kebede T. **Ultrasound assessment of normal portal vein diameter in Ethiopians done at Tikur Anbessa specialized hospital. East and central African journal of surgery.** 2012; 17(1):90-3.
3. Cosgrove DO, Meire HB, Dewbury KC, Farrant P. **Abdominal and general ultrasound: Churchill Livingstone;** 1993.
4. Gupta E, Usman N, Gupta A. **Sonographic evaluation of portal vein diameter in north Indian population. National Journal of Integrated Research in Medicine.** 2013; 4(2):1-4.
5. Anakwue A, Anakwue R, Ugwu A, Nwogu U, Idigo F, Agwu K. **Sonographic evaluation of normal portal vein diameter in Nigerians. Euro J Sci Res.** 2009; 36(1):114-7.
6. Mandal L, Mandal SK, Bandyopadhyay D, Datta S. **Correlation of portal vein diameter and splenic size with gastro-oesophageal varices in cirrhosis of liver. J Ind Aca Clin Med.** 2011; 12(4):266-70.
7. Ohmae H, Tanaka M, Hayashi M, Matsuzaki Y, Kurosaki Y, Blas BL, et al. **Improvement of ultrasonographic and serologic changes in Schistosoma japonicum-infected patients after treatment with praziquantel. The American journal of tropical medicine and hygiene.** 1992; 46(1):99-104.

8. Al-Nakshabandi NA. **The role of ultrasonography in portal hypertension.** *Saudi Journal of Gastroenterology.* 2006; 12(3):111.
9. Lee W-K, Chang SD, Duddalwar VA, Comin JM, Perera W, Lau W-FE, et al. **Imaging assessment of congenital and acquired abnormalities of the portal venous system.** *Radiographics.* 2011; 31(4):905-26.
10. Shankar R, Shetty G, Srinath M, Kulkarni R. **Estimation of portal vein diameter in co-relation with the age, sex and height of an individual.** *Anatomica Karnataka.* 2011; 5(2):13-6.
11. Mengistu M, Shimelis T, Torben W, Terefe A, Kassa T, Hailu A. **Human intestinal schistosomiasis in communities living near three rivers of Jimma town, south Western Ethiopia.** *Ethiopian journal of health sciences.* 2011; 21(2):111-8.
12. Geleto G, Getnet W, Tewelde T. **Mean normal portal vein diameter using sonography among clients coming to radiology department of Jimma University Hospital, Southwest Ethiopia.** *Ethiopian journal of health sciences.* 2016; 26(3):237-42.
13. Ngene P, Ray-Offor O. **Normal main portal vein diameter and blood flow velocity measurement by color doppler sonography in adult Nigerians.** *West African Journal of Ultrasound.* 2016; 17(2).
14. Singh S, Pan kaj AK, Rani A, Sharma PK, Chauhan P. **Gender Linked Metric Analysis of Portal Vein: A Sonographic Appraisal.** *Journal of Clinical and Diagnostic Research: JCDR.* 2017; 11(3):AC13.
15. Jump up to: a b Chapman J, Azevedo AM. **Splenomegaly, Treasure Island (FL): Stat Pearls Publishing.** (2018), "article-29386", rSetrieved 2019-02-26 PMID 28613657.
16. Webb, L. J., Berger, L. A. & Sherlock, S. L., 1977. **Grey scale ultrasonography of portal vein.** *Lancet*, ii, 675-677.
17. Al-Nakshabandi NA. **The role of ultrasonography in portal hypertension.** *Saudi Journal of Gastroenterology.* 2006; 12(3):111.
18. Lopamudra M, Sanjay K M, Dipanjan B, Datta S. **Correlation of portal vein diameter and splenic size with gastro-oesophageal varices in cirrhosis of liver.** *JACM.* 2011; 12(4):266–270. [Google Scholar]
19. Shankar R, Shetty GS, Srinath MG, Kulkarni R. **Estimation of portal vein diameter in co-relation with the age, sex and height of an individual.** *Anatomica Karnataka.* 2011; 5(2):13-6.
20. Pinto-Silva RA, Queiroz LC, Azeredo LM, Silva LC, Lambertucci JR. **Ultrasound in schistosomiasis mansoni.** *Memorias do Instituto Oswaldo Cruz.* 2010; 105(4):479-84.
21. Moriyasu F, Nishida O, Ban N, Nakamura T, Sakai M, Miyake T, Uchino H. **"Congestion index" of the portal vein.** *American Journal of Roentgenology.* 1986; 146(4):735-9.
22. Chuo LS, Mahmud R, Salih QA. **Color Doppler ultrasound examination of the main portal vein and inferior vena cava in normal Malaysian adult population: A fasting and post prandial evaluation.** *Internet J Cardiovascular Res.* 2005; 2(2):s1-6.
23. ROKNI, YAZDI H., and H. Sotoudeh. **"Assessment of normal Doppler parameters of portal vein and hepatic artery in 37 healthy Iranian volunteers.** 2006; 213-216.
24. Jee MG, Baik SK, Park DH, Kim MY, Rhim DW, Jo KW, Hong JH, Kim JW, Kim HS, Kwon SO. **Intere quipment variability of Doppler ultrasonographic indices in patients with liver cirrhosis.** *The Korean journal of hepatology.* 2006; 12(4):539-45.
25. Namasivayam S, Kalra MK, Small WC, Saini S. **Liver: Normal anatomy and examination techniques.** In. **Gore RM, Levine MS. Text book of gastrointestinal radiology.** 3rd ed. Vol. 2. China: Saunders Elsevier; 2008. P. 1527-51.
26. Wilson SR, Withers CE. The liver. In: Rumack CM, Wilson SR, Charboneau JW, editors. **Diagnostic ultrasound.** 3rd ed. Vol 1 (Part II). St. Louis: Elsevier Mosby; 2005. p. 75-145.
27. Anakwue AC, Anakwue RC, Ugwu AC, Nwogu UB, Idigo FU, Agwu KK. **Sonographic evaluation of normal portal vein diameter in Nigerians.** *Euro J Sci Res* 2009; 36(1):114-7.
28. Hawaz Y, Admassie D, Kebede T. **Ultrasound assessment of normal portal vein diameter in Ethiopians done at Tikur Anbessa Specialized Hospital.** *East Cent Afr J Surg* 2012 Mar/Apr; 17(1):90-3.
29. Cosgrove DO. Liver anatomy. In: Cosgrove D, Meire H, Dewbury K, Farrant P, editors. **Clinical ultrasound a comprehensive text—abdominal and general ultrasound.** Vol 1. Edinburgh: Churchill Livingstone; 1994. p. 227-42.
30. Bosch J, Garcia-Pagan JC. **Complication of cirrhosis.** *J Hepatol* 2000; 32(1 Suppl):141-56.

31. Ravi Shankar.G Shailaja Shetty, Srinath.M.G, Roopa Kulkarni. **Estimation of portal vein diameter in co – relation with the age, sex and height of an individual.** Anatomica Karnataka 2011; 5(2):13-6.
32. Yazdi HR, Sotoudeh H. **Assessment of normal doppler parameters of portal vein and hepatic artery in 37 healthy Iranian volunteers.** Iran J Radiol. 2006; 4:213–216
33. Namasivayam S, Kalra MK, Small WC, Saini S. **Liver: normal anatomy and examination techniques. In. Gore RM, Levine MS.** Text book of gastrointestinal radiology. 3rd ed. Vol. 2. China: Saunders Elsevier; 2008. P. 1527-51.
34. Wilson SR, Withers CE. The liver. In: Rumack CM, Wilson SR, Charboneau JW, editors. **Diagnostic ultrasound.** 3rd ed. Vol 1 (Part II). St. Louis: Elsevier Mosby; 2005. p. 75-145.
35. Anakwue AC, Anakwue RC, Ugwu AC, Nwogu UB, Idigo FU, Agwu KK. **Sonographic evaluation of normal portal vein diameter in Nigerians.** Euro J Sci Res 2009; 36(1):114-7.
36. Hawaz Y, Admassie D, Kebede T. **Ultrasound assessment of normal portal vein diameter in Ethiopians done at Tikur Anbessa Specialized Hospital.** East Cent Afr J Surg 2012 Mar/Apr; 17(1):90-3.
37. Cosgrove DO. Liver anatomy. In: Cosgrove D, Meire H, Dewbury K, Farrant P, editors. **Clinical ultrasound a comprehensive text—abdominal and general ultrasound.** Vol 1. Edinburgh: Churchill Livingstone; 1994. p. 227-42.
38. Bosch J, Garcia-Pagan JC. **Complication of cirrhosis.** J Hepatol 2000; 32(1 Suppl):141-56.
39. Ravi Shankar.G Shailaja Shetty, Srinath.M.G, Roopa Kulkarni. **Estimation of portal vein diameter in co – relation with the age, sex and height of an individual.** Anatomica Karnataka 2011; 5(2):13-6.
40. Yazdi HR, Sotoudeh H. **Assessment of normal doppler parameters of portal vein and hepatic artery in 37 healthy Iranian volunteers.** Iran J Radiol. 2006; 4:213–216.

### AUTHORSHIP AND CONTRIBUTION DECLARATION

No.	Author(s) Full Name	Contribution to the paper	Author(s) Signature
1	Sibgha Aqeel	Authorship/Data acquisition, written, analysis, Interpretation and concept.	<i>Sibgha Aqeel</i>
2	Shurooq Amjad	Supervisor/Rectification and revieweing.	<i>Shurooq Amjad</i>
3	Javed Tauqir	Interpretation of data.	<i>Javed Tauqir</i>
4	Mehreen Fatima	Statistical analysis.	<i>Mehreen Fatima</i>