



ORIGINAL ARTICLE

# Clinical and radiological outcome measures in patients after reconstruction of displaced acetabular fractures.

Adnan Latif Malik<sup>1</sup>, Muhammad Abdul Basit<sup>2</sup>, Muhammad Shakeel<sup>3</sup>, Muhammad Iqbal<sup>4</sup>, Muhammad Hanif<sup>5</sup>

**Article Citation:** Malik AL, Basit MA, Shakeel M, Iqbal M, Hanif M. Clinical and radiological outcome measures in patients after reconstruction of displaced acetabular fractures. Professional Med J 2022; 29(3):297-302. <https://doi.org/10.29309/TPMJ/2022.29.03.6363>

**ABSTRACT... Objective:** To determine the clinical and radiological outcome parameters of surgical treatment of acetabular fractures in patients after reconstruction of displaced acetabular fractures. **Study Design:** Prospective study. **Setting:** Department of Orthopedics, Lahore General Hospital, Lahore. **Period:** January 2014 to December 2019. **Material & Methods:** A total of 27 cases of acetabular fractures operated with open reduction and internal fixation were included. Seven patients were lost to follow-up. The outcome measures were noted in 20 patients after three years follow-up. Modified Merle D'Aubigné and Postal score and Matta radiological scoring systems were utilized to note the outcomes. **Results:** There were 14 (70.0%) male and 6 (30.0%) female. Overall mean age was 35.5+8.4 years ranging between 25 to 65 years. Road traffic accidents were the most frequent mechanism of injury noted in 16 (80.0%) patients. The Kocher-Langenback approach was the most commonly adopted surgical approach done in 14 (70.0%) patients. The functional outcome according to Modified Merle D'Aubigné and Postal score was excellent in 9 (45%) patients and poor in 4 (20%). The radiological conclusion according to Matta's radiological score was excellent in 8 (40%) patients and poor in 4 (20%). Four patients developed avascular necrosis of head of femur for which total hip replacement was done later. **Conclusion:** Complications were common and outcome was variable after reconstructing of displaced acetabular fractures.

**Key words:** Acetabular Fracture, Functional Outcome, Necrosis.

## INTRODUCTION

High-velocity injuries cause fractures of acetabulum. Acetabulum fractures associated with other fatal injuries. The articular incongruity is the result of displaced fragments of fractures of acetabulum with or without dislocation that cause uneven distribution of force on articular surface of cartilage. It causes rapid breakdown of articular cartilage surface, which leads to osteoarthritis of hip joint.<sup>1</sup> The goal of management is to achieve anatomic reduction and secure fixation of the fragments so that head of femur is centrally reduced to achieve proper weight bearing in the roof/floor of acetabulum proposed by Judet, Judet and Letournal since 1964.<sup>2</sup> Acetabular fractures comprises of 10% of the pelvic disruptions. The most common are posterior wall fractures, comprises 24% of acetabular fractures.<sup>3</sup>

Major challenge to orthopaedic surgeon is the fixation of acetabular fractures. Twenty to twenty five percent patients are having poor functional outcome with different complications.<sup>3</sup> Management of fracture depends upon surgeon's training and expertise for certain surgical approach accuracy of reduction.<sup>4</sup> Components that affect outcome include delay in surgery, the fracture pattern, the patient's age, associated articular cartilage damage of head of femur and acetabulum, dislocation at the time of injury, correlated neurovascular injury and comorbidities of the patient.<sup>5-12</sup> This study was done to determine the clinical and radiological outcome of surgical treatment of acetabular fractures in patients after reconstruction of displaced acetabular fractures.

## MATERIAL & METHODS

This prospective study was done from January

1. MBBS, FCPS (Ortho), Associate Professor Orthopedic Surgery, Fatima Jinnah Medical University Lahore/ Sir Ganga Ram Hospital Lahore.
2. MBBS, MS (Ortho), Senior Registrar Orthopedic Surgery, Postgraduate Medical Institute/Ameer-ud-Din Medical College/ Lahore General Hospital Lahore, Pakistan.
3. MBBS, FCPS (Ortho), Assistant Professor Orthopedic Surgery, Postgraduate Medical Institute/Ameer-ud-Din Medical College/ Lahore General Hospital Lahore, Pakistan.
4. MBBS, MS (Ortho), Senior Registrar Orthopedic Surgery, Postgraduate Medical Institute/Ameer-ud-Din Medical College/ Lahore General Hospital Lahore, Pakistan.
5. MBBS, MD, FCPS (Ortho), Professor & HOD Department of Orthopedic Surgery, Postgraduate Medical Institute/Ameer-ud-Din Medical College/Lahore General Hospital Lahore, Pakistan.

### Correspondence Address:

Dr. Adnan Latif Malik  
Department of Orthopedic Surgery  
Fatima Jinnah Medical University Lahore/Sir  
Ganga Ram Hospital Lahore.  
[dr.adnanmalik@hotmail.com](mailto:dr.adnanmalik@hotmail.com)

**Article received on:** 18/01/2021  
**Accepted for publication:** 09/05/2021

2014 till December 2019 at the Department of Orthopedics, Lahore General Hospital, Lahore. A total of 27 patients of both genders aged 20 to 80 years having acetabular fractures with displacement who were managed surgically in our department were enrolled. Patients having simple and minimally displaced fractures, open fractures or fractures older than 3 weeks were excluded. We followed patients for three years. Seven patients lost follow up so those were excluded from our study. Approval from institutional ethical committee was taken (Ref:0026/18-30/08/2018). Informed written consent was sought from all study participants.

An ATLS protocol for all was carried out; data recording comprised of the mode of injury, fracture classification, any other injuries, complications and any other ailments. Standard plain radiographs, including antero-posterior pelvis, Judet views of pelvis, as well as CT scans, were carried out to evaluate the types of all fractures before surgeries according to Letournal and Judet.<sup>2</sup>

The basic early goal was structural reduction with stable fixation. Intra-operatively urethral catheterization was done. Intra-operative nerve monitoring was not used. The CT scan determined the approach for surgery with the help of fracture classification and whether closed or open fracture. Kocher-langenback, ilio-inguinal or combined approaches were used. Per-op C-arm was used to avoid intraarticular entry of any implant during surgery. Per-operative exploration of the sciatic nerve was done in patients with nerve injury before the surgery. Intra-operatively, the quality of reduction was noted by senior author (MH) as anatomical, acceptable or non-anatomical. (Table-I).

Post-operatively, three standard radiographs (anteroposterior pelvic, Obturator oblique and Iliac Oblique views) were acquired to categorized the quality of reduction into three groups: anatomical, imperfect and poor using Matta's radiological principle.<sup>1,13</sup> Five anatomical lines were observed for displacement (ilio-inguinal, ilio-ischial, dome, posterior wall, anterior wall) in

all three standard radiographs (Table-II).

Post-operatively, all patients received indomethacin 25mg three times daily to reduce the risk for heterotrophic ossification for six weeks along with pain management. Some patients were given low molecular weight heparin (40mg) pre operatively and post operatively. Antibiotics (Cefuroxime) were also given initially intravenously then per oral as required.

Clinical and radiological follow up of patients were carried out at two weeks, six weeks, twelve weeks, twelve months and then yearly. Functional outcome was recorded after 3<sup>rd</sup> year post-operatively using Modified Merle D'Aubigné and Postal score.<sup>1,14</sup> Radiological outcome was also recorded using Matta's radiological score.

## RESULTS

Initially, 27 patients were enrolled for this study. As 7 patients lost follow up so they were excluded and finally, 20 patients were included in the final analysis. There were 14 (70.0%) male and 6 (30.0%) female. Overall mean age was 35.5+8.4 years ranging between 25 to 65 years. Road traffic accidents were the most frequent mechanism of injury noted in 16 (80.0%) patients. The Kocher-Langenback approach was the most commonly adopted surgical approach done in 14 (70.0%) patients. Table-III is showing Baseline characteristics of the patients.

Table-IV is showing functional and radiological outcomes in the studied patients. The functional outcome according to Modified Merle D'Aubigné and Postal score was excellent in 9 (45%) patients and poor in 4 (20%). The radiological conclusion according to Matta's radiological score was excellent in 8 (40%) patients and poor in 4 (20%). Four patients developed avascular necrosis of head of femur for which total hip replacement was done later.

Anatomical	When all imperfections were corrected (noted visually or intra-operative imaging)
Acceptable	Comminution of bone or deficiencies of bone in fractures due to bone loss when hip was reduced (noted visually or intra-operative imaging)
Non-anatomical	When there was still lasting subluxation of hip and loss of parallelism of the femoral head in relation to geometry of acetabulum (noted visually or intra-operative imaging)

**Table-I. Criteria for quality of reduction as anatomical, acceptable or non-anatomical.**

Anatomical	Residual articular displacement of $\leq 1$ mm in all the three standard radiographs
Imperfect(congruent)	Displacement of $\leq 3$ mm in all the three standard radiographs
Poor (incongruent)	Displacement of $> 3$ mm in any of three standard radiographs

**Table-II. Matta and Merrit Radiological Principles.**

		Number	Percentage
Sex	Males	14	70%
	Females	6	30%
Mechanism of injury	Road Traffic Accident	16	80%
	Fall from Height	4	20%
Surgical approaches	Kocher- langenback	14	70%
	Ilio-inguinal	3	15%
	Combined	3	15%

**Table-III. Baseline characteristics of the patients. (n=20)**

Functional Outcome	Excellent	Good	Fair	Poor
Modified Merle D'Aubigné and Postal score	9 (45%)	5 (25%)	2 (10%)	4 (20%)
Matta's radiological score	8 (40%)	6 (30%)	2 (10%)	4 (20%)

**Table-IV. Functional and radiological outcomes. (n=20)**

## DISCUSSION

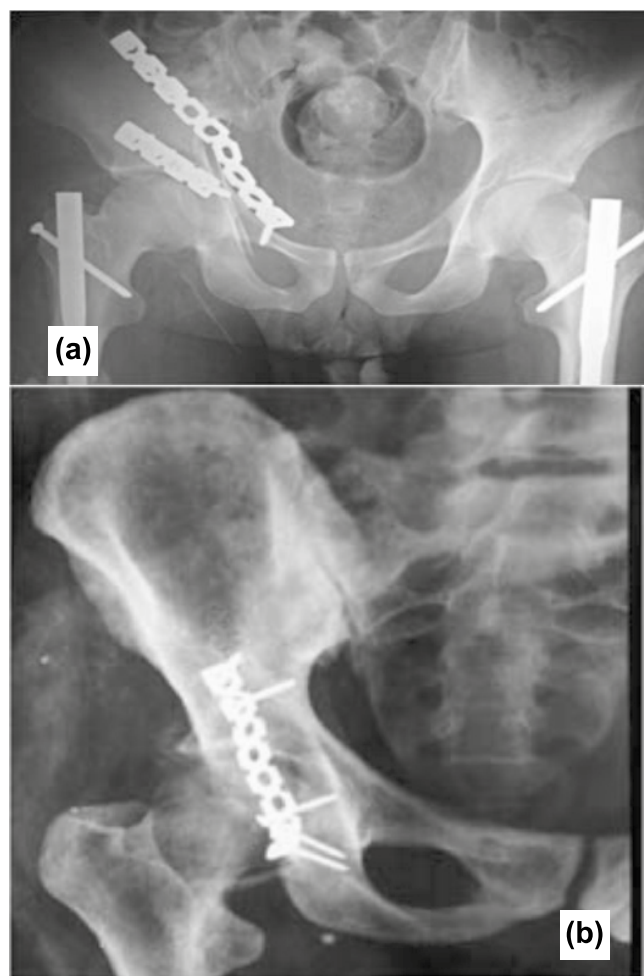
The objective of surgery of fracture of acetabulum is to achieve secure anatomic fixation with good function, ambulatory and pain free patient. The outcome depends upon better reduction.<sup>10</sup>

A complete consideration of the fracture classification, impact force, position of hip and bone quality is important. Sometimes, extra-articular malalignment is accepted to attain anatomical articular reduction as plastic deformations may occur making it difficult to judge fracture lines.

The surgical approach is dependent upon classification. Judet's classification<sup>2</sup> lists five simple fractures and five most common related fracture patterns. Classifying a fracture pattern is difficult as there is inter-observer and intra-observer discrepancy on plain radiographs.<sup>15,16</sup> Letournel and Judet classification<sup>2</sup> was originally established exclusively on radiographs which

with current advancement in CT scanning has questioned the requirement for Obturator and Iliac oblique views.

Many factors influence the outcome following acetabular fractures. Some are those which are beyond control of surgeon like cause of injury, fracture of head of femur, sciatic nerve injury, dislocation of head of femur, fracture pattern, other related injuries, age of patient and co-morbidities. The components comprise of timings of surgery, surgical approach and reduction and fixation quality are controllable and the most prognostic component of post traumatic osteoarthritis with articular congruently with stable fixation. We found that early fixation (within 5-10 days) gives good results than those fixed late. In Letournel original series, the consequence of the reconstruction surgeries after the three weeks was remarkably worse.<sup>17</sup>



**Figure-1. (a) Acetabulum fracture fixed through ilioinguinal approach, (b) Kocher Langenback approach.**

Most of the delays were due to availability of bed, imaging problems and work burden of other trauma on the ward which we believe is totally unacceptable, necessitating the need of fully developed and equipped state of the art specialized pelvic trauma unit.<sup>5,18</sup>

The standard of fixation depends on the size of step or gap.<sup>7,9,11</sup> We established that precise evaluation of steps and gaps was very difficult unless per-operative and so felt defensible using congruency of reduction observed on the radiographs after the surgery as part of evaluation, particularly for those fracture configurations revealed small gaps in particular surface of some anatomical classified reductions. We noted strong association between fixation and its effectiveness. The groups has far

higher rate of decent results where fixation was congruent. Incongruent reductions correlate strongly with poor outcome.<sup>10</sup> The excellent results can be achieved with poor reduction if the gap or step was outside the articular surface or non-weight bearing areas.<sup>19</sup>

We found that posterior column fracture, T-shaped fracture and associated damage to head of femur and cartilage have negative impact on outcome. This suggests that geometry of the fracture (primary articular cartilage damage) has now established the regulating factor. Careful selection of patients is very important for primary arthroplasty. So, a question should arise in mind of every orthopedic surgeon that is this fracture worth fixing or should primary arthroplasty a more suitable option.

The posterior wall acetabular fractures have reflective functional discrepancies. Fractures of the posterior wall with posterior column appear to have a bad outcome. The remaining displacement more than 3 mm along with marginal impaction is associated with the progress of early secondary osteoarthritis, which is correlated to poor functional outcome and the requirement for hip arthroplasty. Even though late hip arthroplasty did not reinstate function to the age- and gender-matched control groups, it may be suitable to consider direct hip arthroplasty for old aged patients with severe marginal impaction and comminution of the posterior wall given the high likelihood of their requiring hip arthroplasty immediately after fixation of the fracture.<sup>9</sup> The connotation of smoking with an obvious increased risk of heterotopic ossification requires further investigation, although the presence of this complication was not autonomously related with poor results.

Complications include infection, nerve damage, deep vein thrombosis, heterotopic ossification and osteoarthritis. To reduce the risk of infection antibiotics were given and patients were followed up with regular ESR and CRP check. Although intra-operative nerve monitoring was not used but it is useful in reducing the risk of iatrogenic sciatic nerve damage during posterior approach.

Obturator nerve is vulnerable during anterior ilio-inguinal approach. Delayed sciatic nerve palsy could be due to hematoma formation in sciatic notch. Patients receiving low molecular weight heparin did not develop deep vein thrombosis but it is a known complication. Two patients develop heterotopic ossification. Role of indomethacin is controversial and its tolerability is also not satisfactory.<sup>20,21</sup> Osteoarthritis remains the primary complication according to Matta et al<sup>13</sup> following acetabular fracture. The overall incidence of osteoarthritis reported by Briffa et al<sup>22</sup> was 38% and 26.6% by Giannoudis et al.<sup>3</sup> We noticed that the duration of follow-up is important as secondary osteoarthritis is likely to develop in even flawlessly fixed fractures. Longer follow-up ideally for life is required to understand the natural history of perfectly reduced fractures.

Our study has several limitations. The study is with less number of patients to draw tangible conclusion. However, since the study is still ongoing we will be registering more patients and follow-up time targeted as minimal 5 years so as to present a comprehensive study of these displaced acetabular fractures. Finally, there is no control group in this case series. It may be discussed that some acetabular fractures could be cured conservatively even those crossing the weight bearing or part of articular dome with a comparable effect provided compatibility is sustained during time of traction.

## CONCLUSION

The treatment result depends on many factors; the skill of the surgeon to classify the fracture so to opt the suitable surgical approach; to have sufficient and adequate instruments, theatre facilities and a proper surgical technique so as to get a near anatomic reduction with articular congruity. In spite of clearing these hurdles there are other factors that are not in surgeons control and can give a poor outcome like late presentation, gross comminution, osteoporosis and osteonecrosis of femoral head. Present study indicates that 70% patients have good to excellent functional outcome that correlates with radiological score, however a longer follow up and an appropriately powered study is

essential to make other conclusions regarding these fractures. At present the aim should be to achieve surgically, anatomical and firm fixation of displaced acetabular fractures as early as possible, thereby maintaining the congruence of the joint.





Copyright© 09 May, 2021.

## REFERENCES

1. Ziran N, Soles GLS, Matta JM. **Outcomes after surgical treatment of acetabular fractures: A review.** Patient Saf Surg. 2019; 13:16.
2. Judet R, Judet J, Letournel E. **Fractures of the acetabulum: Classification and surgical approaches for open reduction: Preliminary report.** J Bone Joint Surg Am. 1964; 46-A:1615-46.
3. Giannoudis PV, Grotz MR, Papakostidis C, Dinopoulos H. **Operative treatment of displaced fractures of the acetabulum. A meta-analysis.** J Bone Joint Surg Br. 2005; 87;2-9.
4. Moed BR, Kregor PJ, Reilly MC, Stover MD. **Acetabular fractures: A problem-oriented approach.** Instr Course Lect. 2017; 66:3-24.
5. Gavaskar AS, Gopalan H, Karthik B, Srinivasan P, Tummala NC. **Delayed total hip arthroplasty for failed acetabular fractures: The influence of initial fracture management on outcome after arthroplasty.** J Arthroplasty. 2017; 32(3):872-876.
6. Mesbahi SAR, Ghaemmaghami A, Ghaemmaghami S, Farhadi P. **Outcome after surgical management of acetabular fractures: A 7-year experience.** Bull Emerg Trauma. 2018; 6(1):37-44.
7. Stevens JM, Shiels S, Whitehouse MR, Ward AJ, Chesser TJ, Acharya M. **Bilateral acetabular fractures: Mechanism, fracture patterns and associated injuries.** J Orthop. 2019; 18:28-31.
8. Firoozabadi R, Cross WW, Krieg JC, Routt MLC. **Acetabular fractures in the senior population-epidemiology, mortality and treatments.** Arch Bone Jt Surg. 2017; 5(2):96-102.
9. Capone A, Peri M, Mastio M. **Surgical treatment of acetabular fractures in the elderly: A systematic review of the results.** EFORT Open Rev. 2017; 2(4):97-103.
10. Murray MM, Zurakowski D, Vrahas MS. **The death of articular chondrocytes after intra-articular fractures in humans.** J Trauma 2004; 56:128-31.

11. Hanschen M, Pesch S, Huber-Wagner S, Biberthaler P. **Management of acetabular fractures in the geriatric patient.** SICOT J. 2017; 3:37.
12. Dyskin E, Hill BW, Torchia MT, Cole PA. **A survey of high- and low-energy acetabular fractures in elderly patients.** Geriatr Orthop Surg Rehabil. 2019; 10:2151459319870426.
13. Matta JM, Mehne DK, Raffi R. **Fracture of the acetabulum fractures: Early results of a prospective study.** Clin Orthop 1996; 205:241-50.
14. Merle d'Aubigné R, Postal M. **functional results of hip arthroplasty with acrylic prosthesis: 1954.** J Bone Joint Surg Am. 1954; 36-A:451-75.
15. Meinberg EG, Agel J, Roberts CS, Karam MD, Kellam JF. **Fracture and dislocation classification compendium-2018.** J Orthop Trauma. 2018 Jan; 32(Suppl 1):S1-S170.
16. Masters J, Metcalfe D, Parsons NR, Achten J, Griffin XL, Costa ML. **White Collaborative Investigators. Interpreting and reporting fracture classification and operation type in hip fracture: Implications for research studies and routine national audits.** Bone Joint J. 2019; 101-B(10):1292-1299.
17. Letournel E, Judet R. **Operative treatment between three weeks and four months after injury. In: Fractures of the acetabulum.** Second ed. Berlin: Springer-Verlag, 1998:591-633.
18. Bircher M, Giannoudis PV. **Pelvic trauma management within the UK: A reflection of a failing trauma service.** Injury 2004; 35:2-6.
19. Starr AJ, Watson JT, Reinert CM, et al. **Complications following the "T extensile" approach: A modified extensile approach for acetabular fracture surgery: Report of forty-three patients.** J Orthop Trauma 2002; 16:535-42.
20. Matta JM, Siebenrock KA. **Does indomethacin reduce heterotopic bone formation after operations for acetabular fractures? A prospective randomized study?** J Bone Joint Surg Br. 1997; 79-B:959-63.
21. Burd TA, Lowry KJ, Anglen JO. **Indomethacin compared with localized irradiation for the prevention of heterotopic ossification following surgical treatment of acetabular fractures.** J Bone Joint Surg Am. 2001; 83-A:1783-8.
22. Briffa N, Pearce R, Hill AM, Bircher M. **Outcomes of acetabular fracture fixation with ten years' follow-up.** J Bone Joint Surg Br. 2011 Feb; 93(2):229-36.

### AUTHORSHIP AND CONTRIBUTION DECLARATION

No.	Author(s) Full Name	Contribution to the paper	Author(s) Signature
1	Adnan Latif Malik	Conceived Idea, Designed Research, Methodology.	
2	Muhammad Abdul Basit	Manuscript Writing, Data Collection.	
3	Muhammad Shakeel	Statistical analysis, Literature Review.	 Dr. Muhammad Shakeel
4	Muhammad Iqbal	Literature Search, Data Interpretation.	
5	Muhammad Hanif	Manuscript final reading and approval.	