



Comparison of Grey scale versus Doppler ultrasound to detect deep venous thrombosis in lower extremities.

Javed Tauqir¹, Anjum Tazeen², Syeda Khadija³, Mehreen Fatima⁴, Muhammad Zakir⁵,
Syed Yousaf Gilani⁶

1. Medical Imaging Doctor
Lecturer
Allied Health Sciences, University of
Lahore.
2. MBBS, MSDU, DMRD
Assistant Professor
Allied Health Sciences, University of
Lahore.
3. Ph.D., MSDU (Ultrasound)
Assistant Professor
Allied Health Sciences, University of
Lahore.
4. M.Phil., Ph.D (Biostatistics)
Assistant Professor
Allied Health Sciences, University of
Lahore.
5. Medical Imaging Doctor
Senior Lecturer
Allied Health Sciences, University of
Lahore.
6. M.Phil., Ph.D (Ultrasound)
Senior Lecturer
Allied Health Sciences, University of
Lahore.

Correspondence Address:
Dr. Javed Tauqir
Allied Health Sciences, University of
Lahore.
javedtauqir@gmail.com

Article received on:
28/12/2020

Accepted for publication:
04/02/2021

ABSTRACT... Objectives: The objective was to determine the accuracy of Gray Scale versus Doppler Ultrasound to Detect Deep Venous Thrombosis in Lower Extremities. **Study Design:** Cross Sectional Analytical study. **Setting:** The University of Lahore and Shalimar Hospital Lahore. **Period:** May to October 2020. **Material & Methods:** After a permission from the ethical committee and a written consent of the patients, on the basis of the clinical suspicions of deep vein thrombosis, A total of 140 patients of both the genders, aging from 20 to 90 years, were referred for Gray Scale & Doppler ultrasound examination. The convenient sampling technique and Statistical software for social sciences (SPSS version 22.0) were used for the analysis of data. **Results:** In 140 patients' present study on Gray Scale ultrasound, 120 (85%) cases were observed with significantly increased blood vessel size, intraluminal echogenicity and a loss of compressibility. However, on Doppler ultrasound, 130 (92%) cases were detected possessing significantly increased blood vessel size, intraluminal echogenicity, absence of blood flow and negative augmentation effect. **Conclusions:** From the result of present study, it is concluded that Doppler may be used as gold standard to diagnose the DVT in the lower extremities. This study concludes also that DVT detection accuracy difference between Doppler and Gray Scale ultrasound is minor i.e. 1:1.08. This minor difference encourages the radiology practitioners of periphery to screen DVT in lower extremities through Gray Scale ultrasound, if Doppler ultrasound is unavailable there.

Key words: Deep Venous Thrombosis (DVT), Doppler Ultrasound, Gray Scale Ultrasound, Lower Extremities Pulmonary Embolism (PE).

Article Citation: Tauqir J, Tazeen A, Khadija S, Fatima M, Zakir M, Gilani SY. Comparison of Grey scale versus Doppler ultrasound to detect deep venous thrombosis in lower extremities. Professional Med J 2021; 28(9):1219-1223.
<https://doi.org/10.29309/TPMJ/2021.28.09.6305>

INTRODUCTION

The establishment of a blood clot inside a deep vein is termed as the deep venous thrombosis (DVT). The Deep vein thrombosis (DVT) is a possibly life threatening problem that is common in the injured. However, it can occur initially also during hospitalization.¹ Screening and avoiding DVT during hospitalization have received an extensive consideration² Deep venous thrombosis usually originates in the lower extremity veins, starting at the calf veins (distal veins). If it progresses, involve the popliteal, femoral and iliac system (proximal veins). The venous thrombosis of distal veins is asymptomatic while proximal veins are usually symptomatic. In the 80-90% cases, it may lead to a very serious condition called pulmonary embolism (PE). DVT and PE are together referred

as venous thrombo-embolism (VTE). VTE is a significant contributor in the burden of worldwide sickness. In western societies, the incidence of DVT in the general population has been estimated to be 80-100/100,000 annually, while in South Asia, 4-75/100,000.³ The commonest sign and manifestations of deep vein thrombosis are aches / painfulness, puffiness, warmth, discoloration or redness and surface veins distention, though nearly half of them have no symptoms.⁴ The idiopathic or unprovoked clot in deep veins occur spontaneously without a cause.⁵ Ultrasound is currently the first-line imaging assessment for DVT in organization with an experienced Sonologist in the light of accessibility, affordability, relative usability, nonexistence of ionizing radiation or contrast material, and high

sensitivity and specificity.⁶ The color Doppler scanning now can deliver a fast and non-invasive supernumerary method of diagnosing DVT in the vein particularly in the lower extremity above the calf.⁷ Acute deep vein thrombosis can be revealed as a defect within the venous lumen without color on color Doppler imaging. In an acute DVT, the lumen of the vein is enlarged; vein compressible and no augmentation is demonstrated. The non-occlusive DVT usually gives fewer symptoms. In chronic DVT, The vein is incompressible, narrow and irregular, which shows an echogenic thrombus attached to the venous walls with collateral growth. The chronic DVT continues to be longer than 10-14 days. The DVT which has no symptoms, however is diagnosed with screening only, is termed as asymptomatic or incidental.^{8,9}

MATERIAL & METHODS

After the approval from ethical committee (MMUT02183001) of the University of Lahore and Shalimar Hospital Lahore, this research work was carried out during the period of 6 months from May to October 2020. This was a cross-sectional analytical study. Gray Scale and Doppler ultrasonography for the diagnosis of DVT was done by Toshiba (Xario) and Mindray (Z5) with a multi-hertz-/ linear frequency range from 7- 15 MHz, and convex transducers with frequency range 3-6 MHz. Based on the clinical suspicion of deep vein thrombosis, 140 patients of both the genders and aging 20 to 90 years, from the Emergency Department of Shalimar Hospital Lahore, were referred for ultrasound examination. Age- wise, they were divided into 7 groups while gender-wise, into 2 (Male and Female) groups. For analyzing the frequency of DVT in the right/left or both legs, the patients were divided in three groups. These patients were initially examined by Gray scale with compressibility test to screen out deep vein thrombosis (DVT). Then, Color and Spectral Doppler analyses were done to confirm the diagnosis with augmentation. Development of the collaterals was also observed in all the patients. MC Nemar test was applied to compare the findings of Gray Scale with Doppler Ultrasound. P-value < 0.05 was taken as critical. The data of results were also summarized in the form of graphs, tables, charts and images.

Quantitative data were presented in the form of mean and standard deviation and qualitative data were presented in the form of frequency and percentage. Statistical software for social sciences (SPSS version 22.0) was used for the analysis of the data.

RESULTS

The calculated sample size of this study was 140 at 95% level of significance and 5% margin of error. According to the Descriptive Statistics of age, the minimum age was 20 years and maximum age was 87 years. Whereas the mean and standard deviation of age was 50.9286 and 18.29245 respectively. Analyzing age distribution, 140 patients (20-90 years) of the present study, were observed in 7 different age Groups (Table-I). They were: 16 (11.4 %) patients in age Group 1 (20-30 years); 20 (14.28 %) patients in Group 2 (31-40years); 19 (13.6 %) patients in Group 3 (41-50 years); 40 (28.5 %) patients in Group 4 (51-60 years); 20 (14.%) patients in Group 5 (61-70 years); 19 (13.6%) patients in Group 6 (71-80 years) and only 6 (4.3 %) patients in Group 7 (81-90 years).

Under the limb involvement analysis, it was observed that in this study, 14 (10 %), 70 (50%), and 56 (40%) patients, had DVT on both legs, on left leg and on right leg respectively (Table-II). Observing the gender discrimination, 95 (67.9%) & 45 (32.1%) patients were female and male respectively (Table-III, Graph-1). On Gray scale ultrasound, in 120 (85%) cases found having significantly increased blood vessel size, intraluminal echogenicity and loss of compressibility out of total 140 cases (Image-1 & Graph-2). However, on Doppler, in 130 (92%) cases significantly increased blood vessel size, intraluminal echogenicity, absence of blood flow and negative Augmentation effect were observed (Images-1 and Graph-2). According to analysis of collaterals, 84 (60%) patients, 20 (14 %) and 36 (26%) patients had developed large, small and no collaterals respectively. The derived statistical values regarding sensitivity, specificity, positive/negative predictive value of the present study data are quoted in Table-IV.

No. of Group	Age of Patients in Years	Number & % Patients Out of 140 Case	
1	20-30	16	11.4%
2	31-40	20	14%
3	41-50	19	13.6%
4	51-60	40	28.5%
5	61-70	20	14%
6	71-80	19	13.6%
7	81-90	6	4.3%

Table-I. Analysis of seven groups of 140 cases on different age.

Affected Limb (Right/Left)	Frequency	Percent
Bilateral	14	10
Left	70	50
Right	56	40
Total	140	1000

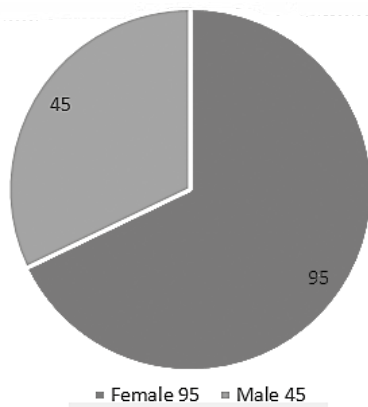
Table-II. DVT affected limb analysis.

Gender	Frequency	Percent
Female	95	67.9
Male	45	32.1
Total	140	100

Table-III. DVT Gender analysis.

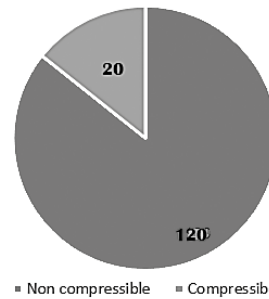
Statistic	Value
Sensitivity	87.88%
Specificity	70.73%
Disease prevalence (*)	70.71%
Positive Predictive Value (*)	87.88%
Negative Predictive Value (*)	70.73%
Accuracy (*)	82.86%

Table-IV. Statistic values.



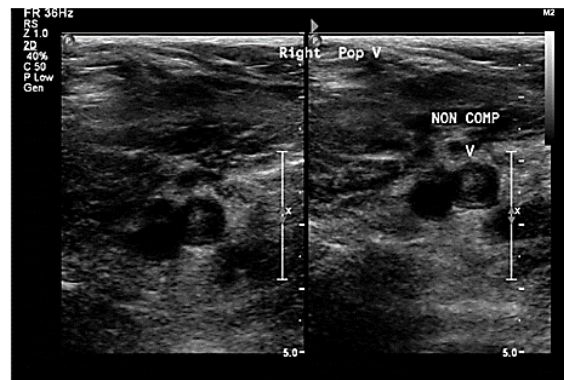
Gender Discrimination analysis

Graph-1

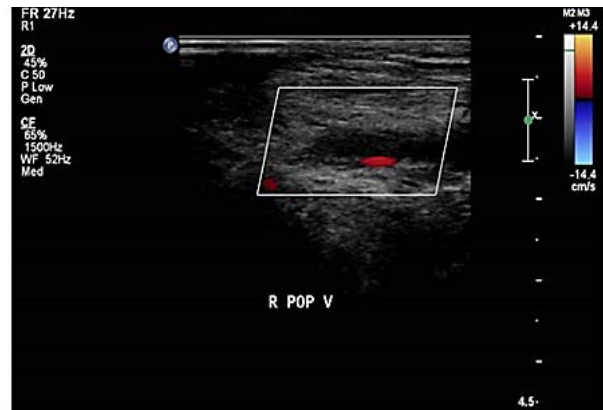


Graphically presented Gray Scale ultrasound analysis for compressibility Test

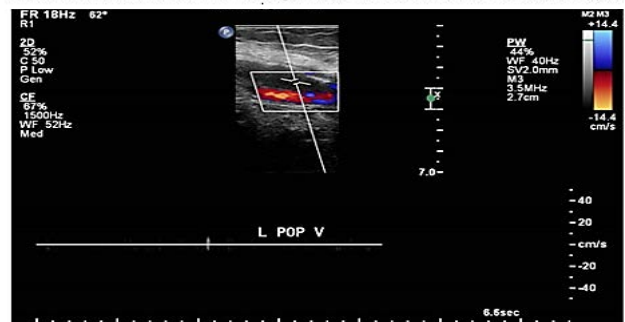
Graph-2



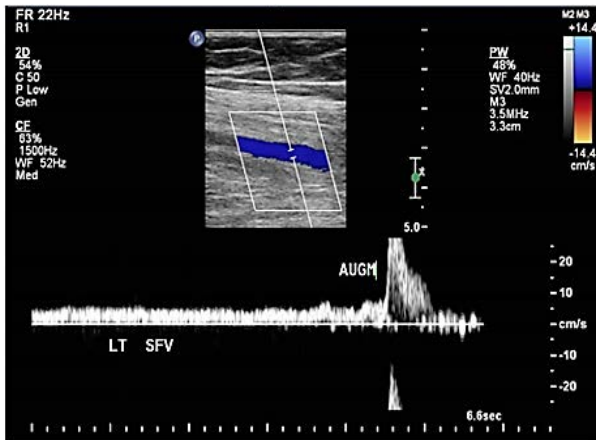Gray Scale Transverse scan showing occluded Rt. Popliteal vein (DVT) with significantly enlarged size, intraluminal echogenicity and loss of compressibility



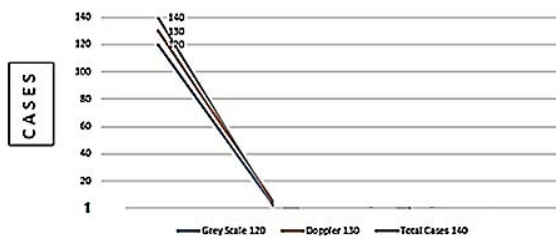
Sagittal scan showing occluded Rt. Popliteal Vein (DVT) with significantly increased Blood vessel size, intraluminal echogenicity, and absence of flow on color Doppler.



Sagittal scan showing occluded Lt. Popliteal vein (DVT) with significantly enlarged size, Intraluminal echogenicity, and absence of flow on color & spectral Doppler



Colour & spectral Sagittal scan showing a normal Augmentation response to squeezing the calf at Lt. superficial femoral vein



Graphically presented Gray Scale V/S Doppler DVT detection in lower extremity of 140 cases

Graph-3

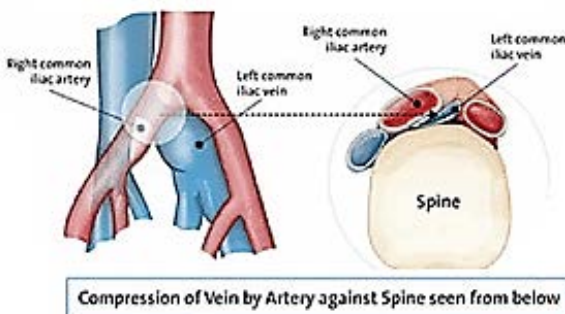


Figure-1

DISCUSSION

In the present study, the prevalence of DVT was more common in age group 51 -60 years. It indicates that the risk factors of DVT are strongly associated with fifth decade of age group. This finding of present study coincides with Engbers M (2010) “on his research “Venous thrombosis in elderly: incidence, Risk Factors and Risk Groups”.¹⁰ The exact cause of higher incidence of DVT, associated with fifty to sixty years of age group, is still unknown.

In the present study, the DVT was found more in female patients (95 / 67.9%) and less in males (45 / 32.1%). This female dominating finding does not agree to the study by Sanjay M Kalandar findings: “74% of the patients were males and 26% were females”.¹¹ However this finding of present study correlates well with the study conducted by Roosendaal FR et.al. Where higher incidence of DVT among females was found. The incidence of DVT is more in female population because estrogen and progesterone female sex hormones are associated with the initiation of DVT by forming thrombus in the blood vessels and first time it was explained by Rosendale FR et al. (2003) in his article “Estrogen, Progesterone and Thrombosis”.¹²

It was observed in this study that DVT was seen more in the left leg as compared to right legs. This disparity might be related to anatomical compression of the left common iliac vein (LCIV) by the right common iliac artery as clarified by Thijs W et.al 2010 in research “Predominance of left-sided deep vein thrombosis and body weight”¹³ and Ashley B. et.al. (2018).¹⁶

In this study, the DVT detection by Doppler was more i.e. (92%) as compared to 85% by Grey scale. This finding of present study coincides with that of Gi T et.al (2020).¹⁴ Similarly, it is supported also by Steve Goodacre et.al. (2005) in his Publication: “The value of clinical assessment in the diagnosis of deep venous thrombosis”.¹⁵

CONCLUSION






The present study result concludes that Doppler may be used as gold standard to diagnose the DVT in the lower extremities. It concludes also that DVT detection accuracy by Doppler and Gray Scale ultrasound is minor i.e. 1:1.08. This minor difference encourages the radiology practitioners of periphery to screen DVT in lower extremities through gray scale ultrasound, if Doppler ultrasound is unavailable there. DVT was seen more in the left leg as compared to right legs. Most commonly DVT was seen in 51-60 years age group. The DVT was seen more in female participants.

Copyright© 04 Feb, 2021.

REFERENCES

1. Wang P-F, Li J-H, Fei C, Li Z, Ke C, Shang K, et al. **Deep vein thrombosis in the uninjured limb in patients with lower extremity fractures: A retrospective study.** BioMed Research International 2020; 2020.
2. Heit JA. **Epidemiology of venous thromboembolism.** Nature Reviews Cardiology 2015; 12(8):464-74.
3. Galanaud J-P, Arnoult AC, Sevestre M-A, Genty C, Bonaldi M, Guyard A, et al. **Impact of anatomical location of lower limb venous thrombus on the risk of subsequent cancer.** Thrombosis and haemostasis 2014; 112(12):1129-36.
4. Geersing G, Zuithoff N, Kearon C, Anderson D, Ten Cate-Hoek A, Elf J, et al. **Exclusion of deep vein thrombosis using the Wells rule in clinically important subgroups: Individual patient data meta-analysis.** BMJ 2014; 348.
5. Meetoo D. **Understanding and managing deep vein thrombosis.** Nurse Prescribing 2013; 11(8):390-5.
6. Zierler BK. **Ultrasonography and diagnosis of venous thromboembolism.** Circulation 2004; 109(12_suppl_1):I-9-I-14.
7. Kahn SR, Shapiro S, Wells PS, Rodger MA, Kovacs MJ, Anderson DR, et al. **Compression stockings to prevent post-thrombotic syndrome: A randomized placebo-controlled trial.** The Lancet 2014; 383(9920):880-8.
8. Chalikias G, Diehm N. **Incidental versus symptomatic venous thrombosis in cancer: A prospective observational study of 340 consecutive patients.** Advances in Venous Arterial Thrombosis 2012; 1(4):175.
9. Iorio A, Kearon C, Filippucci E, Marcucci M, Maccura A, Pengo V, et al. **Risk of recurrence after a first episode of symptomatic venous thromboembolism provoked by a transient risk factor: A systematic review.** Archives of internal medicine 2010; 170(19):1710-6.
10. Engbers M, van Hylckama Vlieg A, Rosendaal F. **Venous thrombosis in the elderly: Incidence, risk factors and risk groups.** Journal of Thrombosis and Haemostasis 2010; 8(10):2105-12.
11. Khaladkar SM, Thakkar DK, Shinde K, Thakkar DK, Shrotri H, Kulkarni VM. **Deep vein thrombosis of the lower limbs: A retrospective analysis of doppler ultrasound findings.** Medical Journal of Dr. DY Patil University 2014; 7(5):612.
12. Rosendaal F, Van Hylckama Vlieg A, Tanis B, Helmerhorst F. **Estrogens, progestogens and thrombosis.** Journal of Thrombosis and Haemostasis 2003; 1(7):1371-80.
13. Thijs W, Rabe K, Rosendaal F, Middeldorp S. **Predominance of left-sided deep vein thrombosis and body weight.** Journal of Thrombosis and Haemostasis 2010; 8(9):2083-4.
14. Gi T, Kuroiwa Y, Yamashita A, Mizutani Y, Asanuma T, Miyati T, et al. **High signal intensity on diffusion-weighted images reflects acute phase of deep vein thrombus.** Thrombosis and haemostasis 2020; 120(10):1463.
15. Steve Goodacre, Alex J Sutton, Fiona C. Sampson **meta-analysis: The value of clinical assessment in the diagnosis of deep venous thrombosis.** Ann Intern Med. 2005 Jul 19; 143(2):129-39. doi: 10.7326/0003-4819-143-2-200507190-00012.
16. Ashley Barry, RVT, RDMS1. **Sonography's role in the diagnosis of may-thurner syndrome.** Journal of Diagnostic Medical Ssonography 2018, Vol. 34(1) 65-70.

AUTHORSHIP AND CONTRIBUTION DECLARATION

Sr. #	Author(s) Full Name	Contribution to the paper	Author(s) Signature
1	Javed Tauqir	Acquisition and Analysis.	
2	Anjum Tazeen	Rectification and reviewing.	
3	Syeda Khadija	Rectification and reviewing.	
4	Mehreen Fatima	Interpretation of Data.	
5	Muhammad Zakir	Conception and design.	
6	Syed Yousaf Gilani	Interpretation of data.	