



1. MBBS
Post graduate Trainee,
Civil Hospital Karachi, Pakistan.
2. MBBS, FCPS
Associate Professor
Department of Neurosurgery,
Civil Hospital Karachi, Pakistan.
3. MBBS, FCPS
Associate Professor
Department of Neurosurgery,
Civil Hospital Karachi, Pakistan.
4. MBBS
Honorary Researcher,
Department of Neurosurgery,
Civil Hospital Karachi, Pakistan.
5. MBBS, FCPS
Assistant Professor
Department of Neurosurgery,
Civil Hospital Karachi, Pakistan.
6. MBBS, FCPS
Assistant Professor
Department of Neurosurgery,
Civil Hospital Karachi, Pakistan.

Correspondence Address:

Dr. Syed Ijlal Ahmed
Honorary Researcher,
Department of Neurosurgery,
Civil Hospital Karachi, Pakistan
syedijlahmed@gmail.com

Article received on:

12/03/2018

Accepted for publication:

30/06/2018

Received after proof reading:

00/00/2018

INTRODUCTION

Ossification of the posterior longitudinal ligament (OPLL) is typically seen in patients of Asian descent, although it has been observed in all ethnic groups. There is a greater prevalence in males and the elderly.¹ Symptoms usually present in the 4th to 6th decades of life.^{2,3} A few conditions have been known to be associated with OPLL such as diffuse idiopathic skeletal hyperostosis, ossification of ligamentum flavum and ankylosing spondylitis. Schizophrenia may be possibly linked to it. The ossification of these ligaments mostly occurs in the mid-cervical spine and it can lead to central canal stenosis. Ossification of the posterior longitudinal ligament is subdivided into four types: continuous, segmental, mixed and localized.⁴ Congenital stenosis, degenerative diseases and trauma can cause myelopathy which is the injury to the spinal cord due to severe compression whereas the disease of spinal cord and nerve roots is called myeloradiculopathy.

CERVICAL LAMINOPLASTY;

OPEN DOOR CERVICAL LAMINOPLASTY FOR OSSIFICATION OF POSTERIOR LONGITUDINAL LIGAMENT; A TERTIARY CARE EXPERIENCE FROM KARACHI, PAKISTAN

Muhammad Sameer Khulsai¹, Muhammad Imran², Atiq Ahmed Khan³, Syed Ijlal Ahmed⁴, Qazi Muhammad Zeeshan⁵, Abdul Razaque Mari⁶

ABSTRACT... Background and Objectives: To analyze the functional outcome of open door laminoplasty (ODL) for the treatment of Cervical Ossified Posterior Longitudinal Ligament (OPLL). **Study Design:** Case series study. **Setting:** Civil Hospital Karachi. **Period:** 05 years, 2013 to 2017. **Material & Methods:** 18 patients (15 Male, 3 Female) underwent ODL for cervical OPLL, over a period of 5 years. Pre-operative & post-operative degree of myelopathy was assessed using Nurick grading score. Patients with Nurick grade > 2 were included in study. MRI compatible titanium micro plates & screws were used. Instability was assessed by X-ray Cervical Spine obtained 6 weeks post-operatively. **Results:** Mean age of presentation was 52 years. 2 to 3 levels were involved in most cases. Mean operative time was 2 hours 30 minutes. Following Nurick grading 94.4% (n=17) improved by grade 1 or more, while in only 5.6% (n=1) it remained same. No instability or kyphotic deformity was seen on follow up X-rays. **Conclusion:** ODL is a safe & effective procedure for the treatment of multiple level OPLL. It can avoid complications related to the anterior approach (like unintentional durotomy & spinal cord injury) and diminished the possibility of instability & kyphotic deformity associated with laminectomy alone.

Key words: Laminoplasty, Myelopathy, Ossified Posterior Longitudinal Ligament (OPLL).

Article Citation: Khulsai MS, Imran M, Khan AA, Ahmed SI, Zeeshan QM, Mari AR. Cervical laminoplasty; open door cervical laminoplasty for ossification of posterior longitudinal ligament; a tertiary care experience from Karachi, Pakistan. Professional Med J 2018; 25(8):1155-1159. DOI:10.29309/TPMJ/18.4872

Laminoplasty is the procedure used to treat stenosis by relieving pressure on the spinal cord. It involves cutting the lamina on both sides of the affected vertebrae. Modified open door laminoplasty with allograft bone and titanium mini-plates effectively treats neurological deficits.⁵

The purpose of this prospective study was to analyze the functional outcome of multiple cases of OPLL treated with open door cervical laminoplasty and to decide whether it is the best technique available or not.

METHODS

Our study was a case series of 18 patients conducted at Civil Hospital, Karachi, Pakistan. The sampling technique in our study was Non probability. The variables of our study include demographics of patients, vertebral segment involvement, presentation of patients and follow up of patients. The data was collected by post graduate trainees and was recorded on computer.

Data was analyzed by using SPSS version 21. Variables were observed for descriptive statistics.

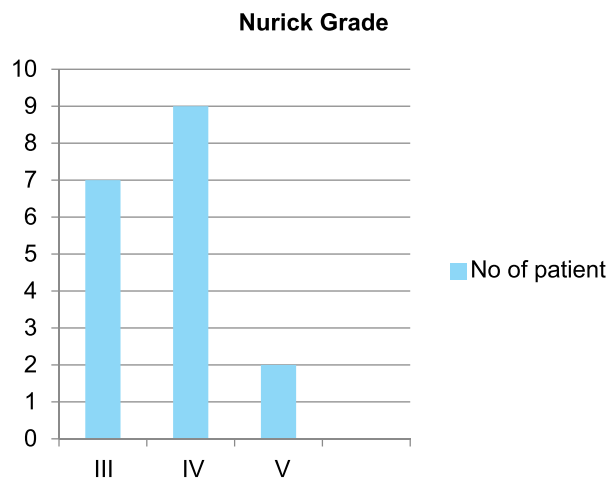
Surgical Technique

Following standard technique of general anesthesia, taking care of excessive neck extension, patient was placed in prone position with head on horse shoe head rest. Midline exposure was done from sub occipital bone to C7. Midline raphe was dissected with monopolar cautery, sub periosteal dissection done of involved segment to expose the junction of lamina and lateral mass on both side. High speed drill was used to make a gutter at the junction of lamina and medial aspect of lateral mass, through the outer cancellous bone till inner cortex is thinned bilaterally. 1 -2 mm kerison punch was used to transect lamina and ligamnetum flavum on opening side. On the hinge side, gutter has to be wide enough to permit a closing wedge osteotomy of approximately 4mm but inner cortex was left intact. A green stick osteotomy was performed by displacing the spinous process towards hinge side and the lamina was opened on the opening side. Bicortical graft was made preferably from spinous process otherwise from iliac crest of around 1.5 x 0.5 x 0.5 cm and was locked into its place between the opened lamina and lateral mass. Stabilization was made by 2mm titanium plate of 4 -5 hole bent in open Z shape secured by micro screw of 2-6 mm on lamina and 2-8mm on lateral mass. Wound was closed in standard fashion. Preoperative and postoperative radiology on Picture 01 – 03.

RESULTS

Our study included 18 patients (12 males, 6 females), with age ranging from 48 to 60 years (mean 52 years). The vertebral segment involvement was C3/4/5 in 6 patients, C4/5/6 in 9 patients and C5/6 in 3 patients. 15 patients presented with myelopathy and 3 patients with myeloradiculopathy. All patients had paresthesia, stiffness, progressive weakness, heaviness in legs and other symptoms included neck pain (15 patients), radicular pain (6 pain) and history of trivial trauma (3 patient). Symptoms ranging from 2 months to 4 years (mean 14.5 months). Hyperreflexia was found in all limbs (6 patients),

lower limb (12 patients) and ankle clonus (5 patients). Presentation as per Nurick grading is in Graph-1.



Graph-1. Presentation as per nurick grade

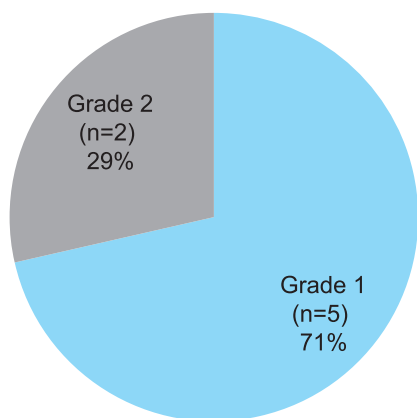
Shafferey modified open door laminoplasty was the technique employed, 2 levels in 3 patients and 3 levels in 15 patients, requiring the mean operating time of 2 hours 30 minutes. The bone graft used was iliac crest in 3 patients and spinous process in 15 patients.

The follow up of patients (mean time) was 1 year and were recommended to wear Philadelphia collar for 8 weeks after surgery. On follow up, X-ray cervical spine was performed after 8 weeks to exclude kyphotic deformity. Neurological symptoms were improved 17 patients. There was no improvement seen in one patient who underwent anterior approach later on. Improvement as per Nurick grading on Graph was 2 to 4.

DISCUSSION

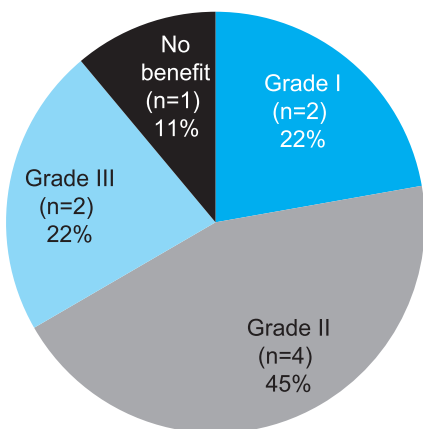
OPLL is a well known pathology compressing the cervical spinal cord resulting in myelopathy. It is twice common in male then with female and mostly presented in 5th to 6th decade of life. All patients had gait disturbance and stiffness on presentation. Symptoms were progressive with a mean of 14.5 months with only 16% (n=3) had history of trivial injury. All these results signifies degenerative pathology to be one of cause and are coherent with literature published.^{1,2}

Improvement among Nurick grade III



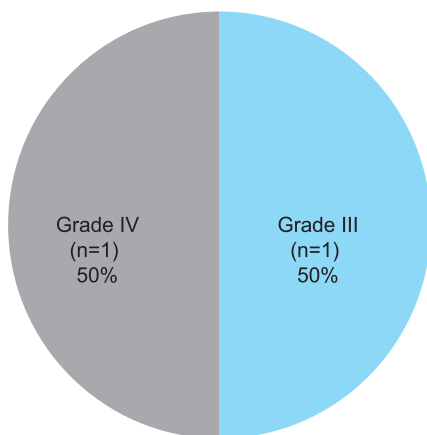
Graph-2. Improvement in patient with nurick grade 03

Improvement in patients with grade IV



Graph-2. Improvement in patient with nurick grade IV

Improvement in patients with Garde V



Graph-3. Improvement in patient with nurick grade V

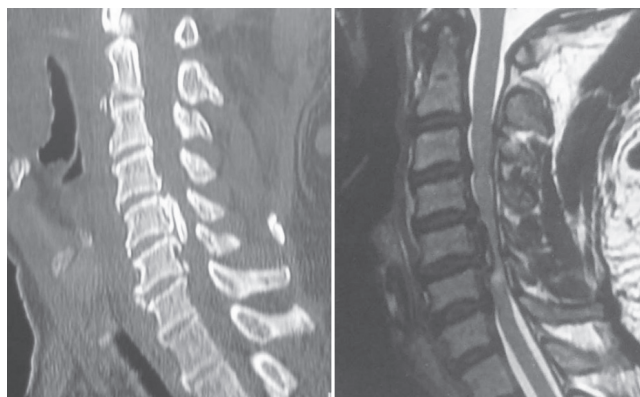


Figure-1. Preoperative CT scan and MRI (Sagittal View):

Various technique had been established using anterior approach, posterior approach or through combined approach.^{1,2} Anterior approach include anterior corpectomy, discectomy, removal of the calcified ligament, and fusion reported neurologic improvement upto 87%(6), but the incidence of dural tear and CSF leak is much higher, reported between 6.7% to 31.8%.⁷ Long term changes in adjacent level is also seen due to fusion at multiple levels⁸. Posterior approach using laminotomies alone is relatively easy and had been common procedure to decompress canal but associated with postoperative instability resulting in kyphotic deformity^{9,10} and risk of restenosis from post laminectomy membrane formation and arachnoiditis¹¹ To avoid post opp instability, laminectomy along with fusion (with lateral mass or pedicle) was advised, however, is associated with risk of neurovascular injuries.¹²

To avoid all these complication Hirabayashi et al¹¹ came up with idea of expansive open door laminoplasty which then modified by others.^{4,13} Two most common laminoplasty done and compare nowadays are open door and French door laminoplasty.^{14,15} We, in our case series of laminoplasties for OPLL used open door technique modified by Shaffrey et al⁵ We had a good experience of using autologous bones graft , used as spacer , sustained by molded titanium plates and micro screws to prevent spring back phenomenon. We prefer using local graft from spinous process whenever possible to reduce donor site pain, blood lose and decrease surgical time.

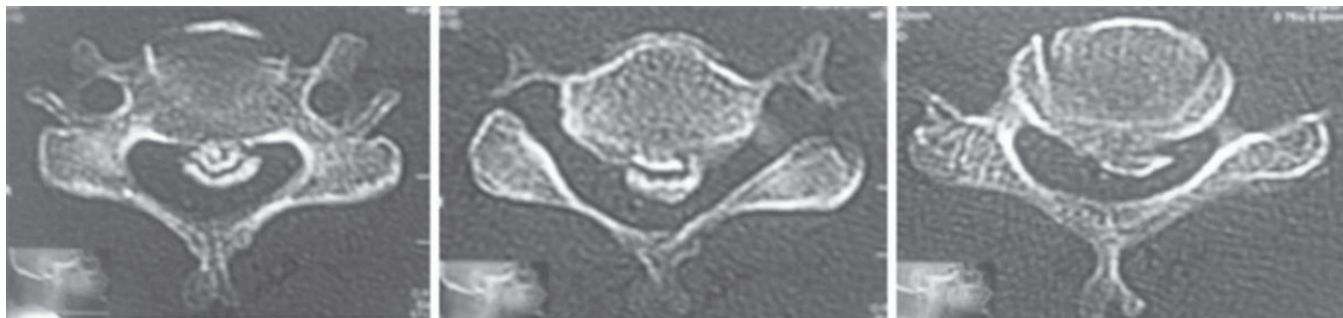

Figure-2. Preoperative CT scan (Axial View):

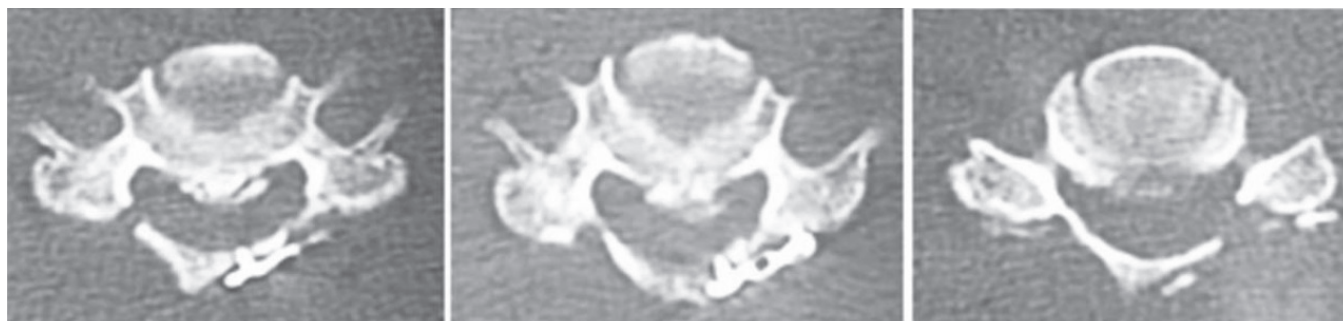


Figure-3. Postoperative CT scan (Axial View):

In this way, we are able to achieve adequate decompression and form new cervical canal.

With respect to duration of surgery, it was 4 hours in literature¹⁸, however lasted around 2 hours 30 minutes, with a mean blood loss of 200cc.

To follow the neurological improvement of patient post operatively, the degree of myelopathy should be quantified in standard method which was done by Nurick in 1972. It is largely based on gait disturbance and can be easily applied to retrospective data.¹⁶ In our series, 94.4% (n=17) atleast improvement in 1 or more score, which has significant effect in quality of life, like from grade 4 (walking with support) to grade 3 (walking without support).

Regarding post operative fusion, we normally advised philadilphea collar, for 6 weeks (which is a normal period of fibrosis) which as compared to other literature had advised soft collar for 3 months.¹⁸

Few studies have been conducted regarding long term results of laminoplasty. Mitazaki et al reported maintenance of neurological improvement for 21

years.¹⁷ We followed our patient for a mean time of 1 year only and need further long term follow up with increase number of patients to prolong efficacy of procedure.

CONCLUSION

Open door laminoplasty is the most preferred techniques, for the management of multiple level OPLL. It can effectively widen the spinal canal and improves the neurological outcome of patient. It can avoid the complication related to anterior approach like unintentional dural tear , spinal cord injury and that of laminectomy alone like kyphotic deformity , instability etc.

Long term studies need to be done for further progress of OPLL resulting in stenosis in adjacent level.






Copyright© 30 June, 2018.

REFERENCES

1. Saetia K, Cho D, Lee S et-al. **Ossification of the posterior longitudinal ligament: a review.** Neurosurg Focus. 2011; 30 (3): E1.
2. 2-Choi BW, Song KJ et al. **Ossification of the posterior longitudinal ligament: a review of literature.** Asian Spine J. 2011; 5 (4): 267-76.

3. Smith ZA, Buchanan CC et-al. **Ossification of the posterior longitudinal ligament: pathogenesis, management, and current surgical approaches.** A review. Neurosurg Focus. 2011; 30 (3): E10.
4. Shaffrey, Christopher I. et al. **“Modified open-door laminoplasty for treatment of neurological deficits in younger patients with congenital spinal stenosis: analysis of clinical and radiographic data.”** Journal of Neurosurgery: Spine 90.2 (1999): 170-177.
5. Kawaguchi Y, Nakano M, Yasuda T, Seki S, Hori T, Suzuki K, et al. **Characteristics of ossification of the spinal ligament; incidence of ossification of the ligamentum flavum in patients with cervical ossification of the posterior longitudinal ligament** Analysis of the whole spine using multidetector CT. Journal of Orthopaedic Science. 2016; 21(4):439-45.
6. Tadashi Kojima, M.D., Shiro Waga et al. **Anterior Cervical Vertebrectomy and Interbody Fusion for Multi-Level Spondylosis and Ossification of the Posterior Longitudinal Ligament,** Neurosurgery, Volume 24, Issue 6, 1 June 1989, Pages 864–872.
7. Mario J. Cardoso, M.D. et al. **Approach-related complications after decompression for cervical ossification of the posterior longitudinal ligament.** Neurosurgical Focus Mar 2011 / Vol. 30 / No. 3 / Page E12.
8. Baba H, Furusawa N et al. **Late radiographic findings after anterior cervical fusion for spondylotic myeloradiculopathy.** Spine 1993; 18:2167-73.
9. Cho WS, Chung CK et al. **Post-laminectomy kyphosis in patients with cervical ossification of the posterior longitudinal ligament: does it cause neurological deterioration?** J Korean Neurosurg Soc 43:259–264, 2008.
10. Kato Y, Iwasaki M, et al. **Long-term follow-up results of laminectomy for cervical myelopathy caused by ossification of the posterior longitudinal ligament.** J Neurosurg 89:217–223, 1998.
11. Hirabayashi K, Watanabe K et al. **Expansive open door laminoplasty for cervical spinal stenotic myelopathy.** Spine 1983; 8:693-9.
12. Hasegawa K, Hirano T et al. **Indications for cervical pedicle screw instrumentation in nontraumatic lesions.** Spine 33:2284–2289, 2008.
13. O’Brien MF, Peterson D et al. **A novel technique for laminoplasty augmentation of spinal canal area using titanium miniplate stabilization: A computerized morphometric analysis.** Spine 1996; 21:474-84.
14. Nakashima H, Kato F et al. **Comparative effectiveness of open-door laminoplasty vs French door laminoplasty in cervical compressive myelopathy.** Spine. 2014; 39: 642-647.
15. Lee DG1, Lee SH et al. **Comparison of surgical outcomes after cervical laminoplasty: open-door technique versus French-door technique.** J Spinal Disord Tech. 2013 Aug; 26(6):E198-203.
16. Nurick S: **The pathogenesis of the spinal cord disorder associated with cervical spondylosis.** Brain 1972; 95:87-100.
17. Mizayaki K, Hirohaji E, Ono S. **Extensive simultaneous multi-segmental laminectomy and posterior decompression with posterolateral fusion.** J Jpn Spine Res Soc. 1994; 5: 167.
18. Lara-Almunia M, Hernandez-Vicente J. **Open Door Laminoplasty: Creation of A New Vertebral Arch.** Int J Spine Surg. 2017 Feb 9; 11:6. doi: 10.14444/4006. eCollection 2017.

AUTHORSHIP AND CONTRIBUTION DECLARATION

Sr. #	Author-s Full Name	Contribution to the paper	Author=s Signature
1	M. Sameer Khulsai	Data analysis, Literature review, Discussion.	
2	Muhammad Imran	Principle idea, Data collection, Literature review, Proofreading.	
3	Atiq Ahmed Khan	Principle idea, Data analysis, Discussion, Proofreading.	
4	Syed Ijlal Ahmed	Study design, Manuscript writing.	
5	Qazi M. Zeeshan	Manuscript writing, Data analysis.	
6	Abdul Razaque Mari	Study design, Discussion.	