

## CASE REPORT

**Intraperitoneal metastatic malignant melanoma arising from small bowel..... A case report.**Fariha Ahmed<sup>1</sup>, Naveed Akhtar<sup>2</sup>, Shafiq Ullah Ch<sup>3</sup>, Syed Shams-ul-Hassan<sup>4</sup>**Article Citation:** Ahmed F, Akhtar N, Ch S, Shams-ul-Hassan S. Intraperitoneal metastatic malignant melanoma arising from small bowel..... a case report. Professional Med J 2023; 30(04):551-553. <https://doi.org/10.29309/TPMJ/2023.30.04.6035>

**ABSTRACT...** Small bowel tumors are very rare. Melanoma in small intestine can be primary or metastatic. Metastatic malignant melanoma in small intestine can arise from skin, eyes, oropharynx, esophagus or ano rectal mucosa. Primary malignant melanomas of small intestine are very rare. In this case report, we are going to present primary malignant melanoma of small intestine, which has already metastasized by the time of presentation. A 60 year old male, presented to us with abdominal pain, vomiting and absolute constipation. On exploration, black colored mass of 5x5cm in distal ileum which was attached to posterior wall of urinary bladder on right side and whole of the gut from stomach to rectum was involved. The patient was thoroughly examined and investigated for cutaneous melanoma, but there was no such tumor present. So it was concluded that this patient had primary malignant melanoma arising from distal ileum.

**Key words:** Primary Malignant Melanoma, Small Bowel Tumors and Gastrointestinal Tumors.

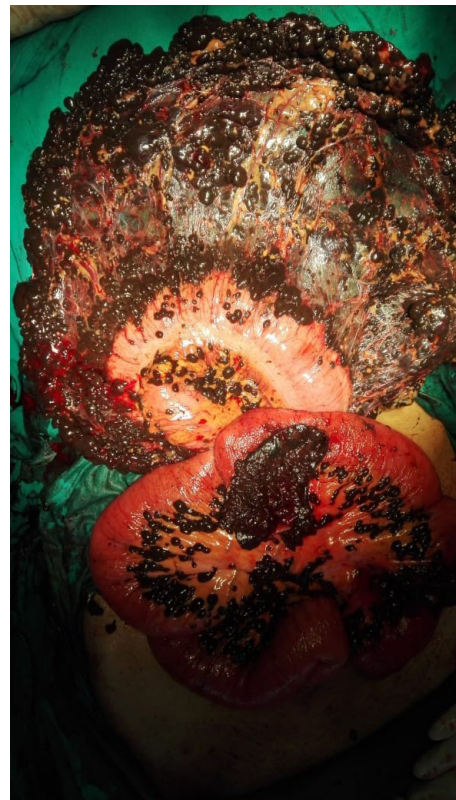
**INTRODUCTION**

Small bowel tumors are very rare. These are only 1-2% of all gastrointestinal tumours.<sup>1</sup> Most of the tumors in small intestine are secondary mets. Melanoma in small intestine can be primary or metastatic. Metastatic malignant melanomas in small intestine can arise from skin, eyes, oropharynx, esophagus or anorectal mucosa.<sup>2</sup> Primary malignant melanomas of small intestine are very rare; a few cases have been reported in the literature, which has no evidence of primary lesion in skin or elsewhere even after complete examination and investigation.<sup>3</sup>

In case report, we are going to present primary malignant melanoma of small intestine, which has already metastasized by the time of presentation.

**Case Presentation**

A 60 year old male, presented to us with abdominal pain, vomiting and absolute constipation.



1. MBBS, FCPS (G. Surgery), Senior Registrar Surgery, Nishtar Medical University/ Hospital Multan.  
2. MBBS, FCPS (G. Surgery), FCPS (Urology), Professor Surgery, Nishtar Medical University/ Hospital Multan.  
3. MBBS, FCPS (G. Surgery), Assistant Professor Surgery, Nishtar Medical University/ Hospital Multan.  
4. MBBS, FCPS (G. Surgery) Senior Registrar Surgery, Nishtar Medical University/ Hospital Multan.

**Correspondence Address:**

Dr. Naveed Akhtar  
Department of Surgery  
Nishtar Medical University/ Hospital Multan.  
[drchnaveedakhtar@gmail.com](mailto:drchnaveedakhtar@gmail.com)

**Article received on:** 26/08/2020

**Accepted for publication:** 28/02/2021

On examination, he had distended abdomen, tender mass in right lower abdomen and bowel sounds were exaggerated. In blood chemistry, he had mild anaemia with decreased haematocrit and increased total leucocyte count and neutrophilia. Rest of the labs was normal. He was explored in emergency. On opening the abdomen, bunch of black coloured small masses were present in the peritoneum and falciform ligament extending upto liver. There was a black coloured mass of 5x5cm, which was present in the distal ileum and it was attached to the posterior wall of the urinary bladder on right side. On further exploration, whole of the gut from stomach to the rectum was studded with small black coloured masses, the mesentery of small gut and large gut and whole of the greater omentum and lesser omentum were also loaded with such black masses and they bled to touch as shown in the Figure-1. Few black coloured nodules were present on the anterior surface of the liver. Undersurface of diaphragm was also found to have such bunches of black coloured masses. Debulking of the mass and omentectomy was done. And the specimens were sent for histopathology.

The morphology and immunohistochemistry were consistent with malignant melanoma. Tumour cells were arranged in sheets. Individual cells were large having vesicular nuclei, prominent nucleoli and abundant eosinophilic cytoplasm. Brown colour pigment was also identified. Sections were stained with a panel of monoclonal antibodies. The immunostains S100, Melan A and HMB 45 were all positive.

Patient recovered from the initial surgery and was sent to Oncology department for further management. He was followed up for two months, up till now, in which he was given two cycles of chemotherapy with D a c a r b a z i n e .

## DISCUSSION

Melanoma arises from the melanocytes which are dendritic cells present in the skin, the eye, the epithelium of the nasal cavity, oropharynx, esophagus, anus, vagina, penis and urinary tract. Usually the small intestine and colon do not have melanocytes.

One proposed origin of primary melanoma in small intestine is neural crest melanoblasts which migrate to distal ileum through the umbilical mesenteric canal.<sup>4,5</sup> This may be the reason of primary small bowel melanoma especially in ileum. The other hypothesis is that, intestinal melanomas can arise from amine precursor uptake and decarboxylation cells (APUD), which can undergo neoplastic transformation in noncutaneous sites.<sup>4,6</sup>

Out of mucosal melanomas, Primary mucosal melanoma is most common in anorectal (anal canal 31.4% and rectum 22.2%), large intestine 0.9%, gall bladder 1.4%, small intestine 2.3%, stomach 2.7%, esophagus 5.9% and oropharynx 32.8%.<sup>7</sup>

Primary intestinal melanoma has aggressive course and very poor outcome, as compared to cutaneous melanoma, especially if it is associated with the involvement of mesenteric lymph nodes.<sup>8</sup> It may be due to very low rate of diagnosis of mucosal melanomas, late presentation and rapid spread of tumour cells by rich vascular and lymphatic network of intestinal mucosa.<sup>8</sup>

Tumour cells depict spindle and epitheloid cells; in which epitheloid cells are large and pleomorphic with large eosinophilic nucleoli abundant cytoplasm. Tumours may have abundant melanin pigment.<sup>9</sup> Markers for malignant melanoma are Melan A, HMB 45 and S100 protein.<sup>9,11</sup>

The mainstay of treatment for resectable intestinal melanoma includes resection of gut containing the lesion with tumour free margins alongwith the mesentery and mesenteric lymph nodes.<sup>2,8,9</sup> Systemic adjuvant chemotherapy has limited role.<sup>9,10,11</sup> The chemotherapeutic agents include Cisplatin, Dacarbazine and Tamoxifen.<sup>9,11</sup>

## CONCLUSION




This patient had primary malignant melanoma arising from the distal ileum. The patient was thoroughly examined and investigated for cutaneous melanoma but there was no such tumour present. By the time of presentation it had already metastasized to different organs.

**Copyright© 28 Feb, 2021.**

## REFERENCES

1. Khosrohshahi E, Horvath W. **Primary malignant melanoma of the small intestine..... a case report.** Rontgenpraxis. 2002; 54(6):220-3.
2. Lens M, Bataille V, Krivokapic Z. **Melanoma of the small intestine.** Lancet Oncol. 2009 May; 10(5):516-21.
3. Woollens A, Derrick EK, Price ML, Darley CK. **Gastrointestinal malignant melanoma.** Int. J Dermatol 1997; 36:129-131.
4. AmarA, Jougon J, Edouard A, Laban P, Marry JP, Hillion. **Primary malignant melanoma of the small intestine.** Gastroenterology Clin Biol. 1991; 16(4); 365-7.
5. Das Gupta TK, Brasfield RD. **Metastatic melanoma of the gastrointestinal tract.** ArchSurg. 1964; 88:969-73.
6. KrugerS, Noack F, Blochle C, Feller AC. **Primary malignant melanoma of the small bowel: A case report and review of the literature.** Tumori. 2004; 91(1):73-6.
7. Cheung MC, Perez EA, Molina MA, Jinx, Gutierrez JC, Franceschi D, et al. **Defining the role of surgery for primary gastrointestinal tract melanoma.** J Ggastrointest Surg 2008; 12:731-8.
8. Kwan Ma Yang, Chan Wook Kim, So-Woon Kim, Jong Lyul Lee, Young Sik Yu, in Cheon Kim. **Primary malignant melanoma of the small intestine: A report of 2 cases and a review of the literature.** Ann Surg Treat Res 2018; 94(5):274-278.
9. A Manouras, M Genetzakis, E Lagoudianakis, H Markogiannakis, A Papadima, G Kafiri, K Fillis, PB Kekis, V Katergiannakis. **Malignant gastrointestinal melanomas of unknown origin: Should it be considered primary?** World J Gastroenterol 2007; 13(29):4027-29.
10. Elsayed AM, Albrahma M, Nzeako UC, Sobin LH. **Malignant melanoma in the small intestine: A case study of 103 patients.** Am J Gastroenterol.1996; 91:1001-6.
11. IS.G. Spiridakis, E.E. Polichronaki, E.E. Sfakianakis, M.E. Flamourakis, T.H. Margetousakis, A.S. Yekalou, G.K. Lianeris, E.S. Giannikaki, M.S. Christodoulakis. **Primary small bowel melanoma. A case report and a review of the literature.** G Chir 2015; 36:128-137.

## AUTHORSHIP AND CONTRIBUTION DECLARATION

No.	Author(s) Full Name	Contribution to the paper	Author(s) Signature
1	Fariha Ahmed	Main author, Surgeon and perform the procedure.	
2	Naveed Akhtar	Surgeon and perform the procedure.	
3	Shafiq Ullah Ch	Collection the data.	
4	Syed Shams-ul-Hassan	Analysis of data, Review the literature.	