



## Trans abdominal versus transvaginal ultrasound in assessment of polycystic ovary.

1. MBBS, MCPS, FCPS  
Associate Professor Radiology  
Jinnah Medical College and  
Hospital, Karachi.
2. MBBS, DMRD  
Senior Registrar  
Jinnah Medical College and  
Hospital, Karachi.
3. MBBS, FCPS  
Assistant Professor  
Sir Syed Medical College &  
Hospital, Karachi.
4. MBBS, MCPS, FCPS  
Assistant Professor Obs & Gynae  
Jinnah Medical College and  
Hospital, Karachi.
5. MBBS  
Sonologist  
Suleman Al Habib Hospital, Riyadh,  
Saudi Arabia.

**Correspondence Address:**  
Dr. Shazia Kadri  
Department of Radiology  
Jinnah Medical College and Hospital  
shaziaum\_wk@yahoo.com  
0300 2135110

**Article received on:**  
11/08/2020

**Accepted for publication:**  
02/10/2020

### INTRODUCTION

Polycystic ovary syndrome (PCOS) is a reproductive and metabolic condition with variable phenotype.<sup>1</sup> The abnormal findings are due to ovarian hyperandrogenism<sup>2,3</sup> and insulin resistance.<sup>4</sup> The polycystic ovaries are one of the important markers of polycystic ovary syndrome (PCO) which is an endocrine condition of unknown cause.<sup>5</sup> It has a variety of symptoms and contributing factors. Stein-Leventhal first described Polycystic ovaries syndrome in 1935, as infertility<sup>6</sup>, menorrhagia, and hirsutism with enlarged ovaries.<sup>7,8,9,10</sup>

These patients are also at high risk for endometrial hyperplasia, carcinoma, breast and ovarian cancers. Polycystic ovaries are usually seen during routine ultrasound examination of female of reproductive age group but few of them have typical complaints of PCOS like infertility,

**Shazia Kadri<sup>1</sup>, Safia Izhar<sup>2</sup>, Nazia Azeem<sup>3</sup>, Sadia Rashid<sup>4</sup>, Zafreen Naz Gudaro<sup>5</sup>**

**ABSTRACT... Objective:** The main objective of our study is basically to compare transabdominal and transvaginal ultrasound in assessment of polycystic ovaries. **Study Design:** Cross Sectional Comparative study. **Setting:** Jinnah Medical College and Hospital Karachi. **Period:** January 2016 to January 2017. **Material & Methods:** 200 married females were selected with complaints of irregular menses, hirsutism, obesity and infertility and age group 18-45 years. Patients with already diagnosed polycystic ovaries or on hormonal treatment were excluded. **Results:** Out of 200 patients, 54 patient shows poly cystic ovaries both on trans abdominal and Trans vaginal ultrasound, 16 patients on Trans vaginal ultrasound only but not on trans abdominal ultrasound in which 13 patients were very obese. Rest of the patients had normal ovaries on both types of ultrasound examinations. The prevalence of polycystic ovaries noted by transabdominal ultrasound is 27% (54/200) overall and by TVS ultrasound is 35% (70/200). **Conclusion:** PCOS is quite a common endocrine complaint. Our results suggest that prevalence of PCO is 27% by trans-abdominal u/s and 35% by TVS. The Mean volume of ovary is greater in women with polycystic ovaries but there is no significant difference seen in prevalence of polycystic ovaries diagnosed by both ultrasound examinations. Although it has been observed that TVS is better than transabdominal U/S in detection of PCO but our study shows that the two methods are almost analogous except in obese patient where TVS displayed better results.

**Key words:** Polycystic Ovaries, Transabdominal, Transvaginal Ultrasound.

**Article Citation:** Kadri S, Izhar S, Azeem N, Rashid S, Gudaro ZN. Trans abdominal versus transvaginal ultrasound in assessment of polycystic ovary. Professional Med J 2021; 28(2):202-207. <https://doi.org/10.29309/TPMJ/2021.28.02.5973>

amenorrhea, increased hair growth (hirsutism) or fatness. Those patients with polycystic ovaries usually not considered to have PCOS until additional workup is done.

The ultrasound appearance of polycystic ovaries was initially included as an important marker of PCO's in 2003 at a joint meeting of the European society for human reproduction and embryology (ESHRE) and the American society for reproductive medicine (ASRM). The recent guidelines of ultrasound are supported by ESHRE / ASRM consensus describes the polycystic ovary as having 12 or more follicles measuring 2-9mm and / or greater ovarian volume of more than 10 cm<sup>3</sup>. Increased echogenicity of stroma or stromal volume are one of the important features of PCO, but it has been observed that the volume calculation of the ovary is more important in clinical practice for quantification of that stroma.<sup>11</sup>

As the women having PCOS are usually fertile, so the existence of a dominant follicle (greater than 10 mm) or corpus luteum may upsurge the volume of ovary to more than 10 cm<sup>3</sup>. In these cases, the physician should perform additional scans during the patient's next menstrual cycle.

Different Histological studies showed that in normal ovaries the number of follicle is generally less than eight where as in polycystic ovaries the number of follicles usually more than eight. It has also been observed that serum hormone levels are not always abnormal in order to establish diagnosis of polycystic ovarian syndrome. In olden days, the biopsy of ovary was done by laparotomy or laparoscopically. These procedures were unacceptably invasive, so biochemical markers were used to establish the criteria for polycystic ovaries syndrome.

Nowadays ultrasound pelvis is used as standard method of diagnosis.<sup>12,13</sup> Transvaginal ultrasound is considered better for visualization of polycystic ovaries. As full urinary bladder is mandatory in transabdominal ultrasound for visualizing the pelvic structures so some women prefer transvaginal ultrasound because they cannot hold urine and it saves their time.<sup>14</sup> The main objective of our study is to compare transabdominal and transvaginal ultrasound in assessment of polycystic ovaries.

## MATERIAL & METHODS

This is a retrospective cross sectional comparative study conducted at Jinnah Medical College and Hospital Karachi from January 2016 to January 2017 with the approval from ethical committee of Jinnah medical College and Hospital (Reference code – Dec.29-2017). The study population included 200 married females patients presented in OPD with complaints of infrequent menses, hirsutism, obesity and infertility with age 18-45 years. The other health consequences of PCOS are elevated BP (Blood pressure), increased cholesterol, and increased blood sugar, cardiac and cerebrovascular disorder. Most of the patients with PCOS are clinically obese, are usually diabetic. The Patients who were already diagnosed case of polycystic ovaries or those,

which were on hormonal treatment, were not included in the study.

Different Radiologists performed Transabdominal ultrasounds imaging with 3.5 MHz and Transvaginal ultrasound with 5 MHz vaginal probe. Transvaginal ultrasound is considered the gold standard for better visualization of polycystic ovaries as it offers optimum picture of the inside ovary, especially in fatty people in comparison to transabdominal ultrasound. TVS is rapidly superseding Transabdominal ultrasound and has excellent resolution due to high frequency probes. In transabdominal ultrasound, we need full urinary bladder for visualizing the pelvic structures. So, prior to examination both written and verbal consent was taken from each patient. 3.5 MHz real time sector scanner (Toshiba nemio XG) did Transabdominal ultrasound scan. Polycystic ovaries were described according to previously published criterias.<sup>15,16,17</sup> There are usually 10 or greater peripheral cysts (2-9 mm in diameter) and increased ovarian stroma. The size and volume of ovary was measured. Thus, the ovaries classified as polycystic or normal by calculating the size and their number of follicles.

Patients were requested to empty their bladder after Transabdominal sonography and if she gives permission, than Transvaginal sonography was done on the same patient using a 5 mHz vaginal probe. The different Radiologist did the Transvaginal sonography. The uterus and both ovary were examined and number of periphery cyst noted. We also collected information of patient menstrual history, procreant history, levels of hormone and weight.

## RESULTS

A total of 200 married females were selected with complaints of irregular menses, hirsutism, obesity and infertility. The age range was 18year to 45 years. Patients with already diagnosed polycystic ovaries, normal menstrual cycle or on hormonal treatment were not included in the study.

The results of TVS and TAS were compared with mean ovarian volume, size, and number of follicles on both imaging. The frequency of polycystic

ovaries noticed by Transabdominal sonography is 27% (54/200) overall with mean ovarian volume 11.2 and number of follicles 7.0mm and by Transvaginal ultrasound is 35% (70/200) with mean ovarian volume 11.9 and number of follicles 7.9mm shown in Table-I. The P value of Transabdominal and Transvaginal ultrasound is 0.00001 and 0.00001 respectively (Table-II) and shows that two methods were almost similar.

Out of 200 patients, 54 patients showed polycystic ovaries on both Transabdominal and Transvaginal sonography (Table-III). There were 16 patients with polycystic ovaries on transvaginal sonography. They were not appreciated on transabdominal sonography, in which 13 patients were very obese. Rest of patient had normal ovaries on both transabdominal and transvaginal ultrasound.

The bilateral polycystic ovaries on Transabdominal sonography is shown in Figure-1 and on Transvaginal ultrasound Shown in Figure-2 images. Many studies suggest that unilateral polycystic ovary could have specific characteristics that differ from polycystic ovaries. However, we noticed that polycystic ovaries were bilateral in all our cases, which we have studied.

With the addition of 3D ultrasound to the transvaginal routine, it is even easier to assess and image the details needed for accurate diagnosis of PCOS. Individual follicle can be counted with certainty and complete ovarian volume can be calculated by minimizing the likelihood of an error. If transabdominal ultrasound is required in patient who are unmarried or refuses transvaginal examination, one must be careful that the urinary bladder should be properly filled but not overdistended as it can compress the ovary and results in inaccurate calculation of ovarian volume and counting of follicles.

**DISCUSSION**

Farquhar C M conducted a study comparing transvaginal and transabdominal ultrasound in detecting the prevalence of polycystic ovaries and found no significant difference in prevalence of PCOS by both sonographic techniques.

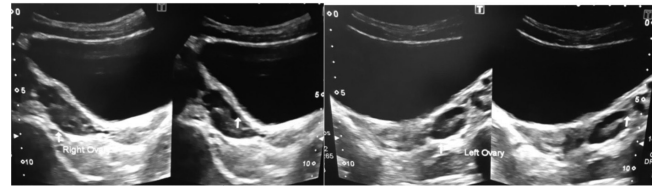


Figure-1. Transabdominal Ultrasound showing bilateral polycystic ovaries

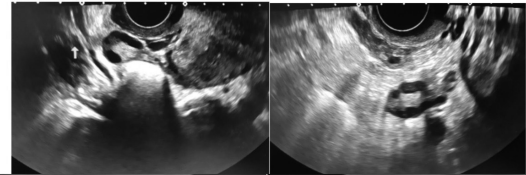


Figure-2. Transvaginal Ultrasound showing polycystic ovaries

Comparison of Trans abdominal Versus TVS		
<b>No. of follicles</b>		
Transabdominal U/S	10.3 (n=54)	3.1 (n=146)
Transvaginal U/S	10.4 (n=70)	3.5 (n=130)
<b>Size of follicles</b>		
Transabdominal U/S	7.0mm (n=54)	6.4mm (n=146)
Transvaginal U/S	7.9mm (n=70)	6.7mm (n=130)
<b>Mean volume cm<sup>3</sup></b>		
Transabdominal U/S	11.2	8.8
Transvaginal U/S	11.9	7.8

Table-I. Comparison of transabdominal and transvaginal ultrasound.

Prevalence of polycystic ovaries on U/S Exam			
Method	PCOS	Normal	P - value
Transabdominal	54	146	0.00001
Transvaginal	70	130	0.00001

Table-II. Prevalence of polycystic ovaries on U/S exam.

Method	PCOS
Transabdominal & Transvaginal Agreement	54
Transabdominal & Transvaginal Disagreement	16

Table-III. Agreement and disagreement of polycystic ovaries on U/S exam.

Similarly our results suggest that transabdominal and transvaginal ultrasound findings were almost similar except in obese patient where TVS displayed better results. PCOS is not only a disease but is a syndrome, so the sonographic findings of polycystic ovaries only are insufficient or diagnosing it. The incidentally seen polycystic ovaries are still not significant clinically as until further workup is done. Polycystic ovary syndrome (PCOS) is a state which disturbs level

of hormones in females and produces more than normal volume of male hormones. Our body makes hormone to make different work happens. Few of these hormone effect menstrual cycle and tied to ability to conceive / pregnant.

Androgens, Insulin, Progesterone play a major role in PCO's. Androgens are man hormones, but females also have them in small quantity. Females having PCOS usually have high levels. Since, Insulin a hormone that controls blood sugar level and if a patient has PCOS, her body may not respond to insulin in its usual manner. Similarly with Progesterone, if body does not have adequate hormone patient will have irregular cycle and miss periods for quite a long time. This disparity in hormone level results not only in menstrual period disturbances but also creates difficulty for females to conceive or to get pregnant. It also results in increased facial and body hair growth, hairlessness and long-standing health problems like diabetes and cardiac problems. Other symptoms include darkened skin or excess skin (skin tags) on the neck, in the armpits, mood changes, pelvic pain, and weight gain. It is diagnosed if female have at least two of three main symptoms like high androgen levels, irregular periods, and cysts in the ovaries. A pelvic exam, blood tests, and ultrasound can confirm the diagnosis.

The imaging of ovaries, done with the right tools, is important in the assessment of patients with suspected PCOS. The ultrasound report should include ovarian volumes, follicle counts and any other relevant information, like the presence of a dominant follicle or corpus luteum cyst. This is quite common to find polycystic ovaries during routine ultrasounds, but it is important to be aware of the requirements for making a PCOS diagnosis, especially if patients are being assessed for other syndromes that may signal the presence of this condition. One who has the most current knowledge of clinical definitions and imaging capabilities will be able to confidently diagnose PCOS and take the appropriate next steps with their patients.

Trans abdominal and Transvaginal ultrasound,

both are used for pelvic examination but Transvaginal sonography found to be more accurate to Transabdominal sonography in most of the cases of female genital abnormality. TAS considered the important imaging technique for baseline evaluation of the female pelvis followed by Transvaginal ultrasound if specified. In patients of suspected polycystic ovaries, endometrial abnormality, suspected ectopic pregnancy, or where ovarian follicle follow up needed, Transvaginal ultrasound plays vital role as the baseline imaging modality and can even substitute trans abdominal ultrasonography. The frequency of polycystic ovaries imaged by transabdominal ultrasound scanning is 27% in 200 married women with age of 18-45 years using acceptable diagnostic criteria and 35% by TVS examination. Histopathological studies demonstrate that less than eight number of follicles seen in normal ovary and in polycystic ovaries it is more than eight.<sup>15,16</sup> It has been established that disturbed serum hormones are not always necessary to diagnose polycystic ovarian syndrome.<sup>12,18,22</sup>

It is published in different studies that Transvaginal ultrasound is better than transabdominal ultrasound in the detection of polycystic ovaries.<sup>19</sup> However, there is no momentous difference noted in follicles number by transabdominal or Transvaginal sonography in our study of normal women population. We found that those women who were over heavy, Transvaginal ultrasound have better results. We have also noted that both ultrasound techniques can diagnose polycystic ovaries using well-known standards. Our data for ovaries volume are also similar to data elsewhere<sup>19,20,21</sup>, representing the consistency of our imaging principles. According to some publications, Transvaginal ultrasound is preferred by some females, as they cannot hold urine or cannot have distended bladder.<sup>14</sup> Nevertheless, some females avoid Transvaginal examination due to concerns regarding menstruation<sup>23,24</sup>, infections.<sup>25</sup>

## CONCLUSION

Polycystic Ovary syndrome is one of the common endocrine disorder may present with single

finding of polycystic ovaries morphology as detected by pelvis ultrasound. The aim of imaging is to detect polycystic ovaries. Pelvic imaging plays vital role in patients with suspected PCOS. The important imaging findings include volume of ovary with size and number of follicles. Polycystic ovaries often found at routine examination and are always not seen with PCOS, so knowledge of the criteria is vital to diagnose PCOS, especially in patients who are send for ovulatory dysfunction or hyperandrogenism workup. Thus, a radiologist must have enough knowledge of the clinical and imaging criteria for diagnosing PCOS. Our results suggest that prevalence of PCO's is 27% by transabdominal and 35% by Transvaginal ultrasound. Although it has been established that Transvaginal sonography has much better role to diagnose PCO than transabdominal sonography but our study shows two methods were almost similar except in obese patient where TVS displayed better results.





Copyright© 02 Oct, 2020.

## REFERENCES

- Azziz R, Adashi EY. **Stein and Leventhal: 80 years on.** Am J Obstet Gynecol 2016; 214:247-256.
- Rosenfield RL, Ehrmann DA. **The pathogenesis of polycystic ovary syndrome (PCOS): The hypothesis of PCOS as functional ovarian hyperandrogenism revisited.** Endocr Rev 2016; 37:467-520.
- Hayes MG, Urbanek M, Ehrmann DA, et al. **Genome-wide association of polycystic ovary syndrome implicates alterations in gonadotropin secretion in European ancestry populations.** Nat Commun 2015; 6:7502.
- Diamanti-Kandarakis E, Dunaif A. **Insulin resistance and the polycystic ovary syndrome revisited: An update on mechanisms and implications.** Endocr Rev 2012; 33:981-1030.
- Fauser BC, Tarlatzis BC, Rebar RW, et al. **Consensus on women's health aspects of polycystic ovary syndrome (PCOS): The Amsterdam ESHRE/ASRM-Sponsored 3rd PCOS Consensus Workshop Group.** FertilSteril 2012; 97:28-38.e25.
- Van Zuuren EJ, Fedorowicz Z, Carter B, Pandis N. **Interventions for hirsutism (excluding laser and photoepilation therapy alone).** Cochrane Database Syst Rev 2015; 2(4):CD010334.
- El Hayek S, Bitar L, Hamdar LH, Mirza FG, Daoud G. **Poly cystic ovarian syndrome: An Updated Overview.** Front Physiol. 2016; 7:124. Published 2016 Apr 5. doi:10.3389/fphys.2016.00124.
- McCartney CR, Marshall JC. **Clinical practice. Polycystic ovary syndrome.** N Engl J Med. 2016; 375(1):54-64. doi:10.1056/NEJMc1514916.
- Bani Mohammad M, MajdiSeghinsara A. **Polycystic Ovary Syndrome (PCOS), Diagnostic Criteria, and AMH.** Asian Pac J Cancer Prev. 2017; 18(1):17-21. Published 2017 Jan 1. doi:10.22034/APJCP.2017.18.1.17.
- Stein, I.F. and Leventhal, M.L. (1935) **Amenorrhea associated with bilateral polycystic ovaries.** Am. J. Obs. Gynaecol., 29, 181-191.
- ESHRE TR, ASRM-Sponsored PCOS Consensus Workshop Group. **Revised 2003 consensus on diagnostic criteria and long-term health risks related to polycystic ovary syndrome.** Fertility and sterility. 2004 Jan 1;81(1):19-25.
- Adams, J., Polson, D.W. and Franks, S. (1986) **Prevalence of polycystic ovaries in women with anovulation and idiopathic hirsutism.** Br. Med. J., 293, 355-9.
- Conway GS, Honour JW, Jacobs HS. **Heterogeneity of the polycystic ovary syndrome: clinical, endocrine and ultrasound features in 556 patients.** Clinical endocrinology. 1989 Apr;30(4):459-70.
- Goldstein SR. **Incorporating endovaginal ultrasonography into the overall gynecologic examination.** American journal of obstetrics and gynecology. 1990 Mar 1;162(3):625-32.
- Saxton DW, Farquhar CM, Rae T, Beard RW, Anderson MC, Wadsworth J. **Accuracy of ultrasound measurements of female pelvic organs.** BJOG: An International Journal of Obstetrics & Gynaecology. 1990 Aug;97(8):695-9.
- Pache TD, Wladimiroff JW, Hop WC, Fauser BC. **How to discriminate between normal and polycystic ovaries: transvaginal US study.** Radiology. 1992 May;183(2):421-3.
- Adams J, Reginald PW, Franks S, Wadsworth J, Beard RW. **Uterine size and endometrial thickness and the significance of cystic ovaries in women with pelvic pain due to congestion.** BJOG: An International Journal of Obstetrics & Gynaecology. 1990 Jul;97(7):583-7.

18. Fox R, Corrigan E, Thomas PG, Hull MG. **Oestrogen and androgen states in oligo-amenorrhoeic women with polycystic ovaries.** BJOG: An International Journal of Obstetrics & Gynaecology. 1991 Mar;98(3):294-9.
19. Polson DW, Wadsworth J, Adams J, Franks S. **Polycystic ovaries—a common finding in normal women.** The Lancet. 1988 Apr 16;331(8590):870-2.
20. Clayton RN, Ogden V, Hodgkinson J, Worswick L, Rodin DA, Dyer S, Meade TW. **How common are polycystic ovaries in normal women and what is their significance for the fertility of the population?.** Clinical endocrinology. 1992 Aug;37(2):127-34.
21. Swanson M, Sauerbrei EE, Cooperberg PL. **Medical implications of ultrasonically detected polycystic ovaries.** Journal of Clinical Ultrasound. 1981 Jun;9(5):219-22.
22. Robinson S, Rodin DA, Deacon A, Wheeler MJ, Clayton RN. **Which hormone tests for the diagnosis of polycystic ovary syndrome?.** BJOG: An International Journal of Obstetrics & Gynaecology. 1992 Mar;99(3):232-8.
23. Berek JS, editor. **Berek and Novak’s Gynecology.** 14th ed. Philadelphia, PA: Lippincott Williams & Wilkins; 2007.
24. Shalev J, Meizner I, Bar-Hava I, Dicker D, Mashiach R, Ben-Rafael Z. **Predictive value of transvaginal sonography performed before routine diagnostic hysteroscopy for evaluation of infertility.** Fertility and sterility. 2000 Feb 1;73(2):412-7.
25. **Center for disease control and prevention (2008) guideline for disinfection and sterilization in healthcare facilities.** Center for Disease Control and Prevention website. Available: [www.cdc.gov/hicpac/pdf/guidelines/Disinfection\\_Nov\\_2008.pdf](http://www.cdc.gov/hicpac/pdf/guidelines/Disinfection_Nov_2008.pdf).

### AUTHORSHIP AND CONTRIBUTION DECLARATION

Sr. #	Author(s) Full Name	Contribution to the paper	Author(s) Signature
1	Shazia Kadri	Conception, Design, Drafting, Final approval & accountable for accuracy.	
2	Safia Izhar	Conception, Design, Drafting, Final approval & accountable for accuracy.	
3	Nazia Azeem	Conception, Design, Drafting, Final approval & accountable for accuracy.	
4	Sadia Rashid	Conception, Design, Drafting, Final approval & accountable for accuracy.	
5	Zafreen Naz Gudaro	Conception, Design, Drafting, Final approval & accountable for accuracy.	