



1. MBBS, FCPS (Orthopedics)
Associate Professor
DOW University of Health Science.
2. MBBS, FCPS
Assistant Professor Orthopedic
Surgery
Shaheed Muhtarma Benazir Bhutto
Medical College, Lyari.
3. MBBS, FCPS
Assistant Professor
Dow University of Health Sciences.
4. MBBS, FCPS
Consultant Orthopedic Surgeon
Civil Hospital Karachi.
5. MBBS, FCPS
Assistant Professor Orthopedic
Surgery
Dow University of Health Sciences.
6. MBBS, FCPS
Assistant Professor Orthopedic
Surgery
Dow University of Health Sciences.

Pseudotumor involving the distal femur – the rare presentation.

Badar u Din Sahito¹, Masroor Ahmed², Dillep Kumar³, Arsalan Khalil Ayub⁴, Suneel Kumar⁵, Nauman Hussain⁶

ABSTRACT... Pseudotumor is the rare presentation of hemophilia, and is the sign of severe disease. We present a case of 16 years old boy with no known comorbid who presented with pain and swelling around the right distal thigh for one month, his physical examination, laboratory investigation and imaging were suspicious of any malignant pathology. Biopsy was performed and specimen was sent for histopathology, that turned to be clotted blood with no atypical or malignant cells. On the basis of above findings provisional diagnosis of hemophilia was made serum levels of factor VIII were sent and that turned out to be 2.2%. Factor VIII concentrates was administered, swelling around the knee joint gradually subsided after the administration of factor VIII but there was no improvement of range of movement at knee joint.

Key words: Distal Femur, Hemophilia, Pseudotumor.

Article Citation: Sahito B, Ahmed M, Kumar D, Ayub AK, Kumar S, Hussain N. Pseudotumor involving the distal femur – the rare presentation. Professional Med J 2021; 28(10):1531-1534. <https://doi.org/10.29309/TPMJ/2021.28.10.5307>

Correspondence Address:

Dr. Masroor Ahmed
Department of Orthopedic Surgery
Shaheed Muhtarma Benazir Bhutto
Medical College, Lyari.
drmasroor68@hotmail.com

Article received on:

22/06/2020

Accepted for publication:

28/07/2021

INTRODUCTION

Hemophilia is x- linked recessive disorder that affects the male only as the females are the carriers, it occurs due to deficiency of either factor VIII called as Hemophilia type A or factor IX known as Hemophilia type B. Hemophilia is congenital defect in coagulation process leading to repeated episodes of bleeding from the minor trauma or sometimes even without any prior history of trauma .Type A and Type B hemophilia are presents exactly the same way and cannot be differentiated from each other on the basis of clinical or radiological parameters.¹ Any child presenting with history of bruising, unprompted bleeding, or bleed associated with minor trauma or uncontrolled bleeding during or after surgery should always be considered for hemophilia². Hemophilia has been divided into different grades on the basis of severity of disease and deficient state of clotting factors i.e. mild when the clotting factor levels are less than 5%, moderate (1-5%), and severe when it is less than 1%.^{2,3} Pseudotumor is seen in about 1-2% of the population suffering from hemophilia, it can also be considered as

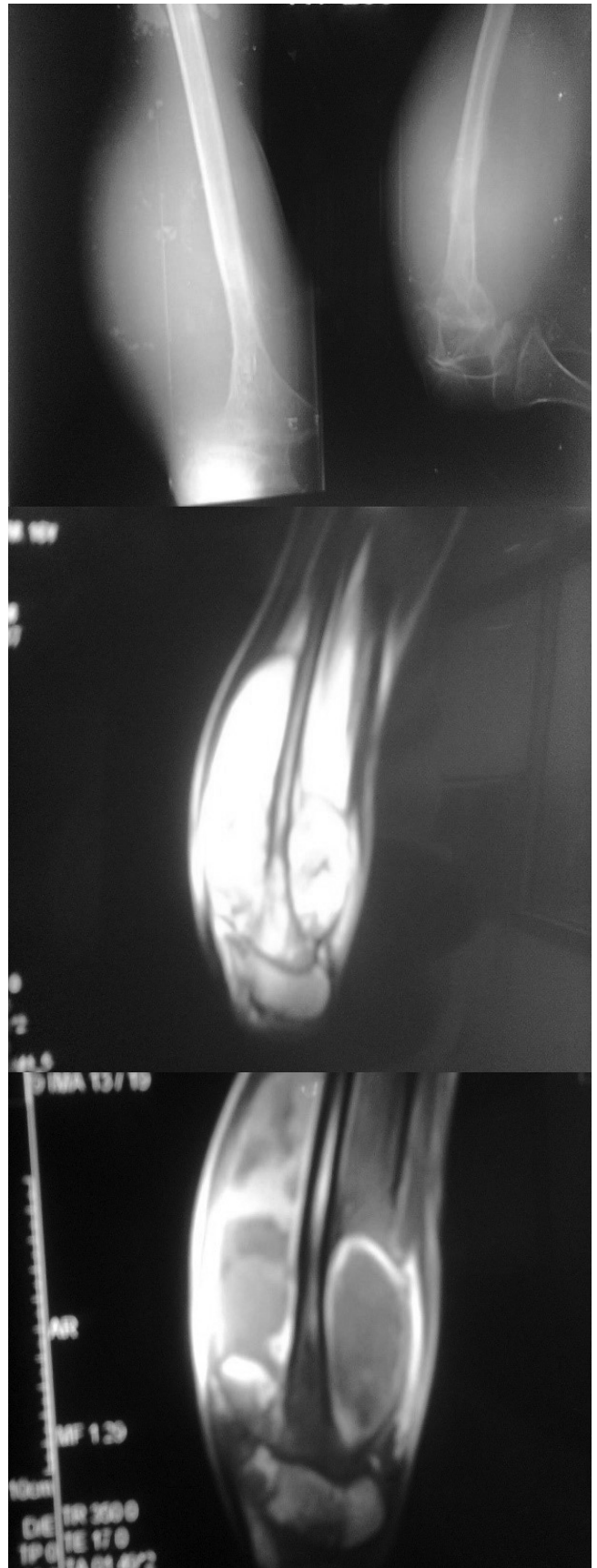the one of the sign of the severe disease.⁴ it develops due to recurrent bleeding episodes either at the fracture site or into soft tissues, these areas of clotted blood gets encapsulated and expand over the period of time leading to development of compression symptoms around the pseudotumor.⁵ This presentation of bone and joint destruction as a result of repeated abnormal bleeding and even presence of involvement of soft tissues give rise to picture of any malignant bone tumors, sometimes it becomes extremely difficult to differentiate these pseudotumors from the malignant one.⁶

CASE REPORT

We are reporting a case of 16 year old boy resident of Badin (230 km away from Karachi), who presented with swelling and pain around the right distal thigh for one month. He developed swelling after fall on the ground, it appeared slowly and gradually, it was associated with pain that was mild to moderate in intensity ,dull in nature, continuous, relieved by taking analgesic and aggravated by movement of knee joint there

is no swelling at any other part of body, and no history of fever or weight loss. Rest of the history was insignificant. On examination he was thin, lean boy with swelling around the right distal thigh of about 15 x 15 cm, oval swelling that was firm to hard in consistency, and fixed to underlying structures and skin as well. Enlarged lymph nodes were found at the level of inguinal region. He has fixed flexion deformity at knee joint with range of motion 40-70 degrees of flexion only, movements at the hip and ankle joints were within normal range. There was no any neurovascular involvement. On the basis of history and examination clinical suspicion of malignant tumor was made. On further investigation hemoglobin level was 4.7mg/dl, ESR was 48, CRP levels were 37.8, serum calcium was 8.9, phosphorus was 5 and alkaline phosphatase was 120 IU. His prothrombin time was 10.5 seconds and activated partial thromboplastin time (APTT) was 31.1.

X-ray knee joint with femur showed soft tissue swelling around the distal femur with erosion and periosteal elevation at diaphysis of femur. MRI of the affected area showed large mass of abnormal signal intensity within the anterior compartment of distal thigh with associated erosive changes involving the metaphysis-epiphyseal region of femur with infiltration into cortex and medullary cavity. There is large extra osseous component measuring 14.5 X 17.8 cm, most likely representing neoplastic lesion. CT scan chest was normal. On the basis of history, examination and investigation differential diagnosis of osteosarcoma, Ewing sarcoma and chondrosarcoma was made and Incisional biopsy was performed, there were multiple blood clots and no tumor cells seen on the slides. On the basis of above findings provisional diagnosis of hemophilia was made serum levels of factor VIII were sent and that turned out to be 2.2% (reference range 45-158%) and definitive diagnosis of hemophilia was made on above levels. Patient was discussed with hematologist blood transfused and factor VIII was administered. Swelling around the knee joint gradually subsided after the administration of factor VIII but there was no improvement of range of movement at knee joint.



DISCUSSION






Pseudotumor is one of the rare complications of hemophilia, soft tissues as well as bone both can be involved but usual location being the soft tissues i.e. intramuscular. When it involves the muscles near its attachment causes the erosion of bone. almost any bone can be affected from this condition but commonly affected are femur, pelvic bones, tibia and small bones of hand.⁷ Two types of pseudotumor has been described in literature, proximal type that involves the femur and pelvic bones and the distal pseudotumor that involves the hand and feet, proximal pseudotumor is associated with poor prognosis and good prognosis has been observed in children.⁸ Radiology is most important part apart from the clinical history and examination in diagnosis and evaluation of these disorders to differentiate it from its counterparts because it most often presents like tumor, as it is associated with extraosseous mass with bony destruction.^{9,10} There are multiple options in terms of radiological examination for evaluation of these disorders ranging from ultrasound, computed tomography (CT), and MRI everyone has its own advantages and disadvantages but MRI remains the best option as it not only provides information about bone as well as soft tissue extent of the lesion.¹¹ Usually conservative treatment seems to be the better option for these type of disorders as these are associated with increased risk of bleeding both intraoperatively and postoperatively, and it includes the replacement of factor VIII levels to reduce the recurrent bleeding episodes.

Copyright© 28 July, 2021.

REFERENCES

1. Kerr R. **Imaging of musculoskeletal complications of hemophilia.** Semin Musculoskelet Radiol 2003; 7:127-36.
2. Rodriguez-Merchan EC. **Musculoskeletal complications of hemophilia.** HSS J. 2010; 6(1):37-42.
3. World Federation of Hemophilia. **2nd Guidelines for the management of hemophilia.** Montreal: World Federation of Hemophilia; Blackwell Publishing Ltd; 2005
4. Magallon M, Monteagudo J, Altisent C, Ibanez A, Rodriguez-Perez A, Riba J, et al. **Hemophilic pseudotumor: Multicenter experience over a 25-year period.** Am J Hematol 1994; 45:103 – 108.
5. Duarte ML, Duarte ÉR, Solorzano EB. **Hemophilic pseudotumor – a rare complication.** Rev Bras Hematol Hemoter. 2017; 39(1):84-5.
6. Hermann G, Gilbert MS, Abdelwahab IF. **Hemophilia: Evaluation of musculoskeletal involvement with CT, sonography, and MR imaging.** AJR Am J Roentgenol 1992; 158:119-23.
7. Jaovisidha S, Ryu KN, Hodler J, Schweitzer ME, Sartoris DJ, Resnick D. **Hemophilic pseudotumor: Spectrum of MR findings.** Skeletal Radiol 1997; 26:468–474.
8. Ahlberg AK. **On the natural history of hemophilic pseudotumor.** J Bone Joint Surg Am. 1975; 57:1133-6.
9. Kerr R. **Imaging of musculoskeletal complications of hemophilia.** Semin Musculoskelet Radiol. 2003; 7(2):127-36.
10. Maclachlan J, Gough-Palmer A, Hargunani R, Farrant J, Holloway B. **Haemophilia imaging: A review.** Skelet Radiol. 2009; 38(10):949-57.
11. Rodriguez-Merchan EC, Jimenez-Yuste V. The role of selective angiographic embolization of the musculoskeletal system in haemophilia. Haemophilia 2009; 15:864–8.

AUTHORSHIP AND CONTRIBUTION DECLARATION

Sr. #	Author(s) Full Name	Contribution to the paper	Author(s) Signature
1	Badar u Din Sahito	Data collection and Idea.	
2	Masroor Ahmed	Manuscript writing.	
3	Dillep Kumar	Literature search.	
4	Arsalan Khalil Ayub	Literature search.	
5	Suneel Kumar	Data collection.	
6	Nauman Hussain	Literature search.	