

PRIMARY UNILATERAL CLEFT LIP REPAIR BY NOORDHOFF'S TECHNIQUE

DR. GHULAM QADIR FAYYAZ,
MBBS, DSS, MS

Assistant Prof. of Plastic Surgery
Department of Plastic Surgery,
PMC, Allied Hospital, Faisalabad.

DR. MUHAMMAD ASHRAF GANATRA,
MBBS, MS

Assistant Prof. of Plastic Surgery
Dow Medical University, Karachi.

DR. TANVEER AHMED RANA,
MBBS, FCPS

Senior Registrar,
Department of Plastic Surgery,
Allied Hospital, Faisalabad.

ABSTRACT: gqfayyaz@hotmail.com **Objectives:** To reconstruct the lip, anatomically, functionally, as well as aesthetically. **Design:** Prospective study. **Setting:** Allied Hospital (P M C) Faisalabad. Period: Jan 2003 to Dec 2003. **Material & Methods:** Noordhoff's technique of Cleft Lip repair was applied in 108 patients operated during the year 2003 at Plastic Surgery Unit of Allied Hospital, Faisalabad. Rule of ten i.e Hb = 10g/dl, Age = 10 Weeks and Weight = 10 Ib was applied for selection of patients. **Results:** Sex ratio was almost equal, 75 % patients belonged to rural areas while 25% belonged to urban areas. Vermilion restoration was good. Results during early follow up of alar reposition & Cartilage lift were satisfactory. **Conclusions:** This procedure improve the results of lip repair better than any other procedure described for cleft lip repair.

Key words: Unilateral Cleft Lip, Noordhoff, Millard, Cupid's Bow.

INTRODUCTION:

Cleft Lip is a common craniofacial anomaly with incidence of about 1.9: 1000 live births in our country. Its exact cause is unknown. Multiple factors are involved in its aetiology including genetic factors, drug intake during pregnancy specially steroids, smoking and folate deficiency. Surgical repair of the Cleft Lip is not carried out before 3 months of age, time generally taken by manifestation of other associated congenital diseases. Millard's technique¹ is commonly used method for lip repair. Samuel Noordhoff has refined the Millard's technique.

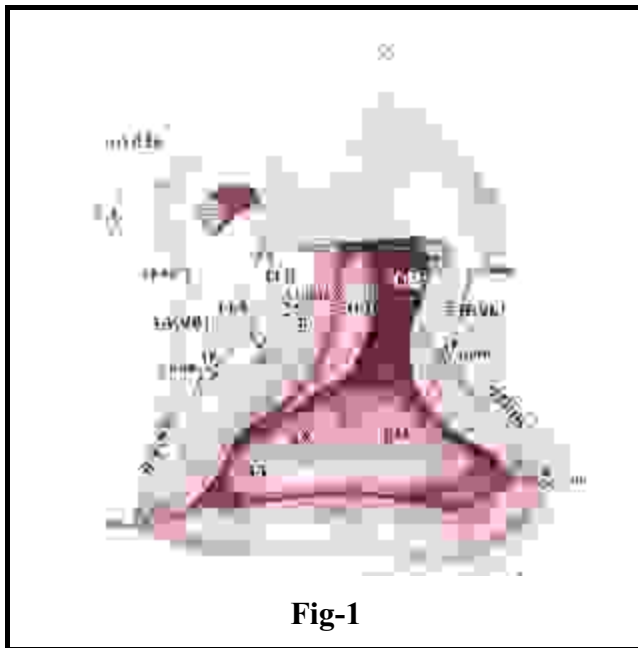
Critical observations reveal that Noordhoff's technique gives better cosmetic results in addition to functional and anatomical restoration. Understanding of anatomy of free border of the lip is important. It consists of vermilion, a unique type of epithelium and mucosa. Vermilion is separated from skin by white skin roll and from mucosa by a line called red line by Noordhoff.

MATERIAL & METHODS:

Noordhoff's technique² of Cleft Lip repair was applied in 108 patients operated during the year 2003

at Plastic Surgery Unit of Allied Hospital, Faisalabad. Rule of ten i.e Hb = 10g/dl, Age = 10 Weeks and Weight = 10 lb was applied for selection of patients. Systemic examination was done in all cases to rule out congenital associated anomalies. All cases were operated under General Anesthesia by endotracheal intubation. Key points were identified, marked and tattooed with gentian violet by hypodermic needle. Peaks of Cupid's bow were marked as point 2,3 and 3h ; vertical height of Lip as VR (right) and VL (left), horizontal length of Lip as HR (right) and HL (left). NORMALLY:

VR (5A) = VL (5B)
HR (6A) = HL (6B)



In Cleft lip, these measurements are invariably decreased on the cleft side^{3,4}. At this stage incision lines should not be adjusted according to these measurements, until after release of the tethered tissues.

Local examination was done to identify degree of cleft and associated degree of cartilaginous & bony abnormalities to fix the priorities for treatment. It is critical to identify the degree of exact pathology before surgical treatment as described by Afifi.

Normally Vermilion is widest at the bases of philtral columns but it is deficient on the cleft side of cupid's bow. Beauty of Noordhoff's technique is that it corrects this vermilion deficiency as well during Cleft Lip repair.

At the incision lines adrenaline 1:100000 was injected and after an interval of seven minutes, incisions were made to reduce haemorrhage per-operatively.

Medial Lip segment is rotated downwards (rotation flap) and lateral lip segment is advanced medially (advancement flap) as a basic principle of Cleft Lip repair described by the Millard for the first time in 1957. Degree of shortening in medial lip segment is first calculated by measuring the distance between point 2 to median point of columellar base (Point 4) and between point 3 to point 4. The difference between these measurements determines the degree of shortening. Same amount of lengthening of the lip is therefore required.

Methods Used for Lengthening of rotation flap (one or more of the followings):

- I Extending the curved incision from point 3 to the nearby columellar margin (4-5mm lengthening), further extending it up to 2/3rd of the distance at the columellar base gains another 3mm lengthening as described by Millard.
- II It may be extended further in the same curve but not beyond the philtral column.

Methods of vertical lengthening of advancement flap:
It was achieved sufficiently by

- I Release of muscle from dermis and mucosa
- II Dividing the muscle from the Skeletal attachment and its attachment to the alar base
- III Insertion of C-flap below the maxillary ala

IV Shifting point 3/ more laterally.

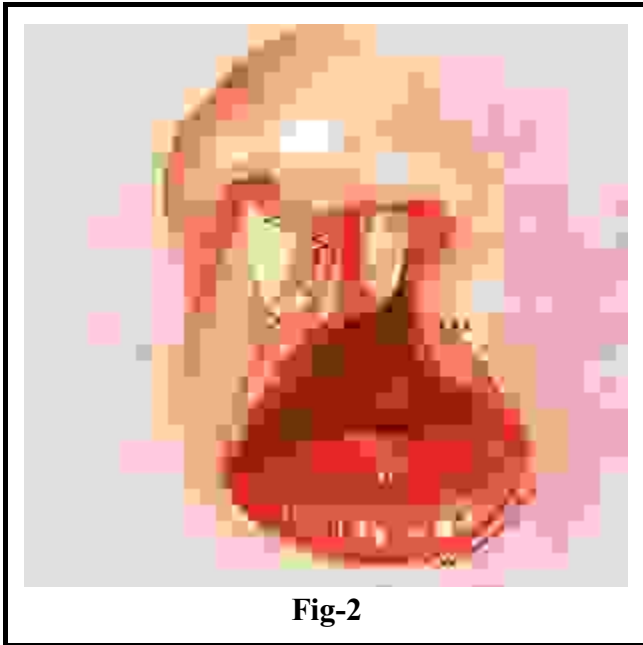


Fig-2

RECONSTRUCTION OF NASAL FLOOR:

Was achieved in cases of complete Cleft Lip by raising T-flap (inferior turbinate mucosa), B-flap & Cm-flap, and restoring them in nasal floor as shown in Fig. 03, 04, 05, 06.

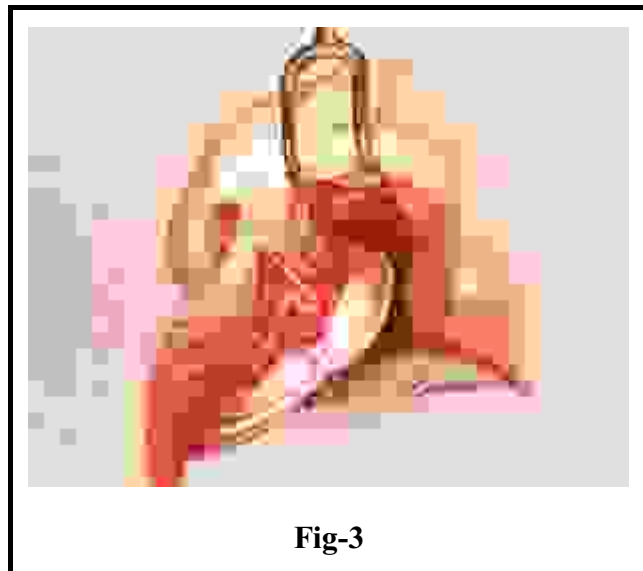

Fig-3

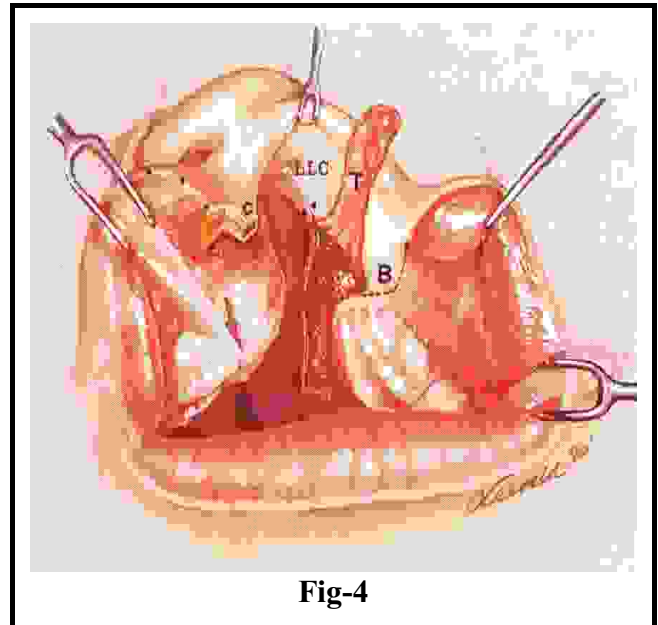


Fig-4

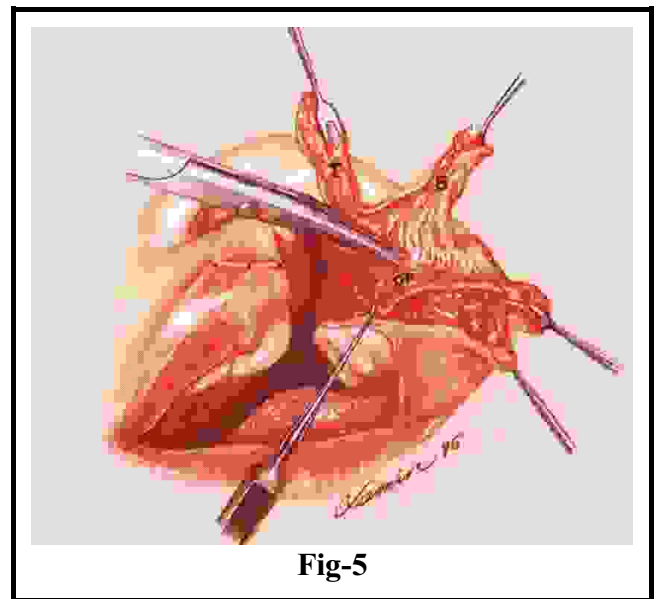


Fig-5

During raising of T-flap, fibrous band connecting the lower lateral cartilage to piriform opening was divided to free the cartilage. Correction of Nasal deformity was done during primary surgery. The cartilage including both its crura was undermined beneath the skin by blunt tipped scissors to free it from the skin. Lower lateral cartilage was raised by proline suture and fixed to the lower border of the upper lateral

cartilage near the dome. Transfixation cartilage sutures of the ala were applied to fix the cartilage in raised position and to give ala its normal anatomical shape. C-Flap was used either to lengthen the columella or in the nasal sill depending upon the situation.

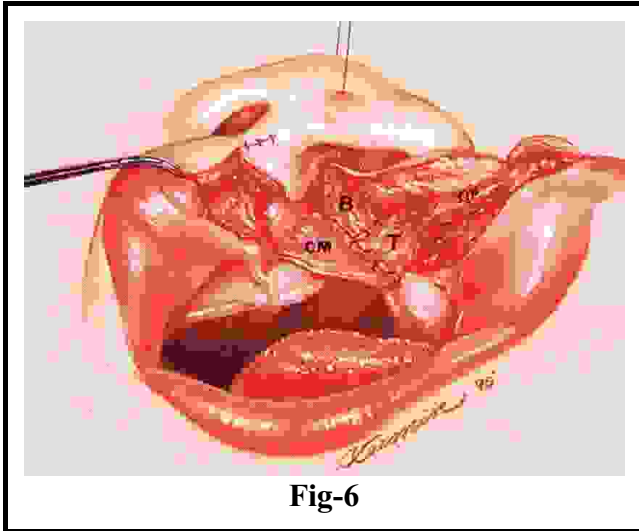


Fig-6

REPAIR OF VERMILION AT FREE BORDER OF LIP

On the medial cleft segment red line was incised at the deficient vermilion to open it. A triangular vermilion flap developed from the lateral cleft segment was inserted into the gap. This procedure balanced the vermilion width at the base of philtral column on both sides.

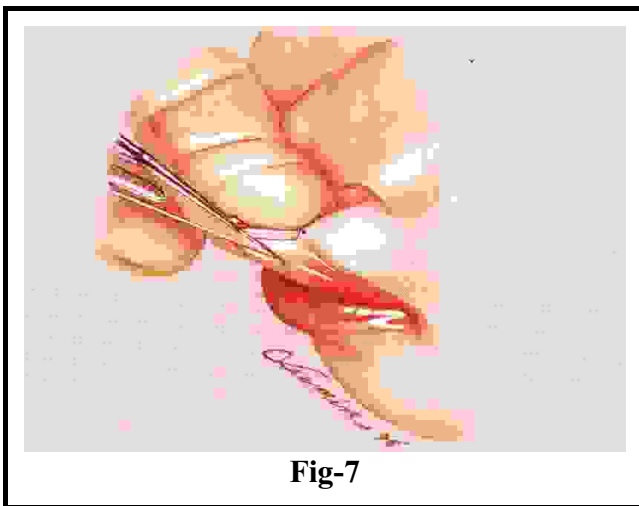


Fig-7

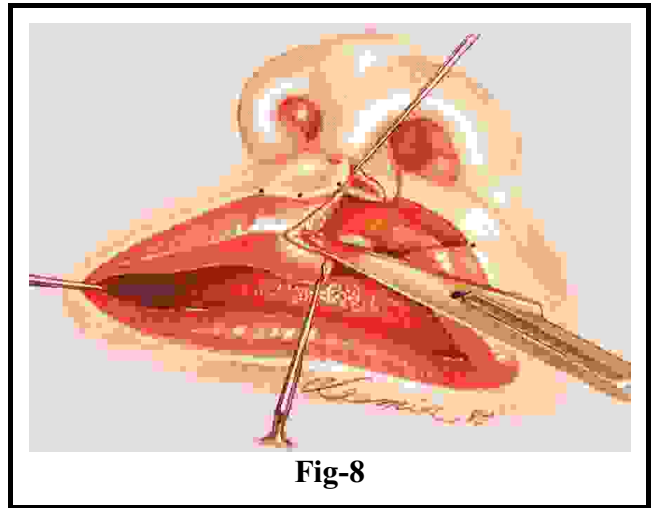


Fig-8

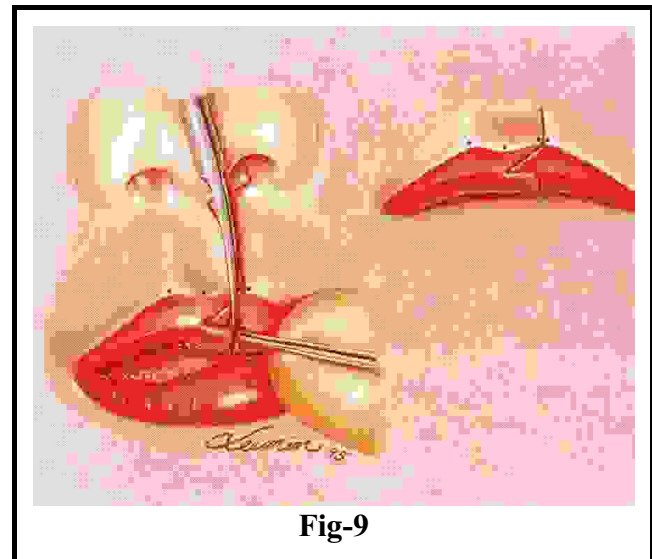


Fig-9

RECONSTRUCTION OF LIP

Was done in three layers, mucosa first, then muscle and ultimately the skin. Muscle was stitched with vicryl 5/0 starting from point 3-3^{-5,6,7}. Then traction was maintained downwards at this point to keep the cupid's bow in rotated position before remaining muscle sutures were applied superiorly.

Ala was realigned with vicryl suture passing it through both alar bases at myo-cutaneous level. Suture was passed from within outwards and then from without

inwards through the same point on both sides and then stitched. It rotated malpositioned ala to bring it medially. Before skin sutures were applied skin of medial lip segment was assessed for its adequate length by noting that point 2,3 & 3/ are lying on the same horizontal line. If short, further lengthening of medial Lip skin was achieved by inserting a small triangular skin flap from lateral segment into the medial lip segment just above the cupid's bow. Following measurements now must be equal.

VR (5A) = VL (5B)
 11 A = 11 B
 HR (6A) = HL (6B)

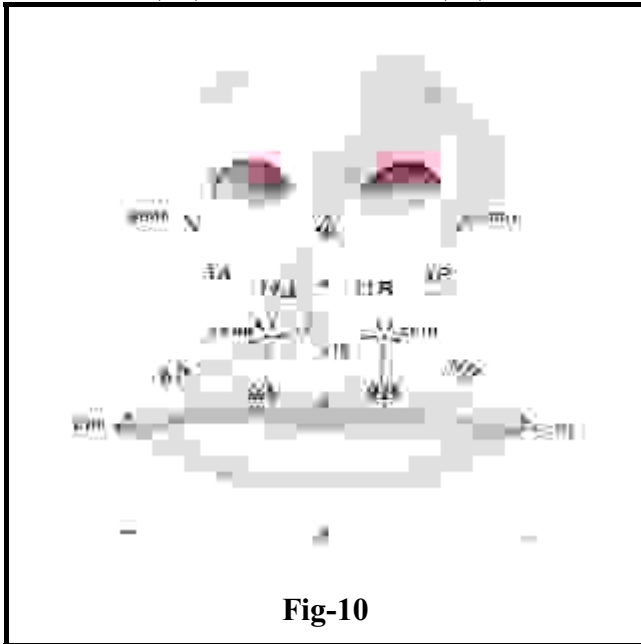


Fig-10

Skin was then approximated with prolene 6/0, reinforced by inverted sub-cuticular 5/0 Vicryl stitches. Vermilion was then repaired by insertion of lateral triangular flap into the gap created medially just below the cleft side of cupid bow and stitched under tension.


Wound was dressed after applying polyfax ointment locally. Stitches were removed on 5th day with or without sedation. Olive oil massage was advised for 3 times a day for 6 months from 10th day onwards. Cephalosporin was injected just before the surgery followed by two more doses at the interval of 12

hours.

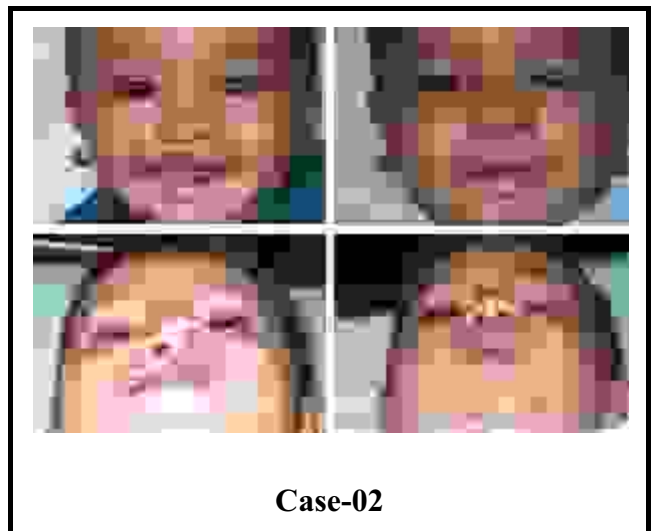
RESULTS

Age of patient varied from 3 months to 20 years Sex ratio was almost equal 75 % patients belonged to rural areas while 25% belonged to urban areas. No Anesthetic complications occurred per or Post Operatively. No Significant (post operative) complications were seen except wound dehiscense in two cases during early follow up. Skin Wound healed well in all other cases Vermilion restoration was good. Results during early follow up of alar reposition & Cartilage lift were satisfactory.

INCOMPLETE CLEFT LIP






Case-01



Case-02

COMPLETE CLEFT LIP



DISCUSSION

Cleft Lip is a common craniofacial anomaly, affecting the urban (25%) and rural community (75%). Three months after birth is a sufficient time period for manifestation and diagnosis of other associated congenital anomalies. Operation is thus advised at the age of 3 months when soft tissue structures are also well developed. Aims of operation must include aesthetic restoration in addition to anatomic and functional restoration of the lip.

Degree of soft tissue, cartilaginous & bony defects must be assessed pre operatively as mentioned by Afifi⁸; only then one will be able to treat it accordingly. Complete knowledge of anatomy of free border of lip along with the regional anatomy plays significant role to achieve good aesthetic results post-operatively. Vermilion is invariably deficient on the cleft side of cupid's bow. Millard's straight line closure does not correct it. It is only the Noordhoff's triangular vermilion flap technique which corrects this deficiency successfully and very effectively.

Lip is short in length and height on the cleft side. Poole noted that it was not width of cleft but its vertical height that must be balanced in repair. In Cleft Lip, tissues are tethered & clumped together. During tissue dissection, as muscle is released from dermis, mucosa & alar base, it is stretched and elongated. So there is practically no need of changing the incision lines before dissection.

To increase the vertical height of rotation flap, extension of curved incision is usually sufficient. There is no need of making the back cut for this purpose as it is difficult to repair it by lateral segment advancement as it will lead to a bigger and wider scar. Vertical lengthening of advancement flap can be easily obtained by freeing the muscle from skin and mucosa and by dividing the muscle attachment at the alar base. Salyer⁹ described that obicularis oris must be dissected from its bony attachment on the lateral lip segment. It should however be remembered as mentioned by A De Mey et. al that wide dissection of muscle with delicate function may be followed by

fibrosis and restricted regional growth. In normally shaped nostrils a simple excision of abnormal segment of muscle underlying the lip crease should be sufficient (no undermining). Trott¹⁰ also described the soft tissue undermining from anterior face of maxilla to achieve adequate mobilization for tension free lip repair. Afifi recommended mucosal incision just about the lingual-labial sulcus along both the medial & lateral lip segments to dissect the tethered tissue supra-periosteally thus increases the mobilization of both labial segments. In case further lengthening is required, it can be achieved by insertion of C-flap below the ala or by shifting point 3\ more laterally. It can also be achieved by horizontal incision below and around the ala (classical Millard's procedure). This is usually unnecessary as also described by Salyer & Afifi as it may lead to hypertrophic scar formation sometimes.

In Millard's classical repair of Unilateral Cleft Lip, there is notching at the free border of lip. As the scar contracts, this notching becomes more and more pronounced. The scar around the Ala is not imperceptible in majority of the cases.

It is now well established that the nose should be repaired at the time of primary unilateral cleft lip repair. This type of repair we do today is not new. Vilray Blair described it in detail in 1930. Trott described good results of cartilage realignment through open rhinoplasty during primary cleft lip repair. Division of fibrous band that fixes the lower lateral cartilage to the piriform aperture on Cleft side is an essential step to correct the position of the cartilage and lifting it upwards to the normal position, where it is fixed to the upper lateral cartilage to maintain its new position. Musgrave mentioned that repairs involving inadequate undermining & detachment of alar base leave fibrous bands between alar cartilage & maxilla and aberrant muscle fibres from orbicularis and the levator labii superioris alaeque nasi. These bands and muscles inevitably keep the alar cartilage tethered laterally and contribute to subsequent drift of the alar base laterally & superiorly. When the Noordhoff's technique is applied, releasing these bands and

muscles, overcorrection of ala base should be avoided as there is now no tendency for lateral drift of ala, otherwise a small nostril will result. Tsuyoshi Takato¹¹ is of the opinion that suturing of the lower lateral cartilage on the cleft side to the contralateral upper lateral cartilage & medial crura raise the dome and maintain the corrected height. Suspension to the ipsilateral upper later lateral cartilage and the septal angle is performed simultaneously. Alar transfixation sutures also help maintain its new position and gives the ala its normal appearance.

To avoid post-operative notching at free border of lip skin, muscle and mucosa should be stitched correctly.

- I The mucosa can be closed in straight line without tension, otherwise suture it without addition of a Z - Plasty.
- II Lower most suture of muscle approximation at point 3-3/ is very important, if missed it will lead to notching. Chul described that the single most important procedure in cleft lip repair is the precise repair of the dynamic structure in the upper lip i.e. the orbicularis oris muscle. The two different anatomical and functional portions should be repaired separately to allow each to fulfill its unique function. The deep muscle (intrinsic) component is constrictor while the superficial (extrinsic) component is retractor of mouth. De Mey et.al are of the opinion that separate suture of the intrinsic bundle will provide a better shape to the vermillion. Intrinsic portion of orbicularis oris is that which runs from commissure to commissure just beneath the vermillion.
- III Medial lip segment, if short should be lengthened further by adding a triangular skin flap from lateral segment to the medial segment just above the white roll. It does not disturb the philtral column. Point 2, 3, 3/ should be on same horizontal line.

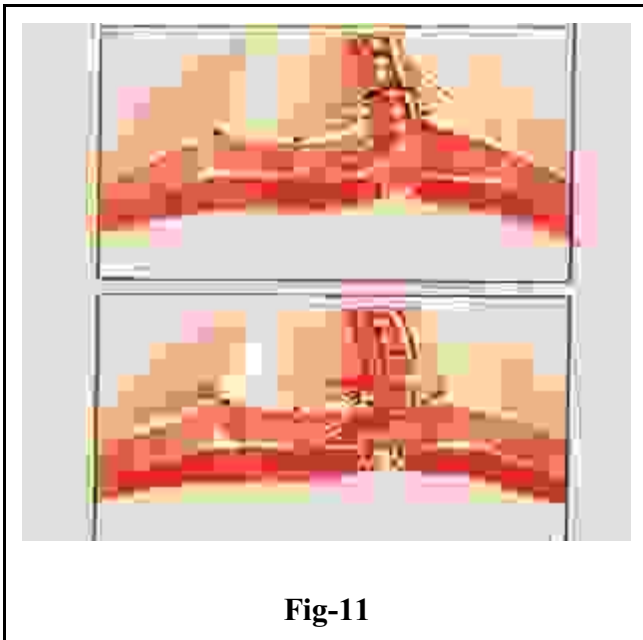


Fig-11

Alar realignment by vicryl 5/0 is essential as it rotates the ala and drifts it medially to the anatomical position especially if lower lateral cartilage has been freed from its attachment to the piriform aperture. Post-operatively as the scar tends to contract, gentle olive oil massage must be advised to counter balance this scar contraction for a period of 6 months.

Silicon nostril stent may be advised for 6 months to give the nostril its normal contour.

REFERENCES

- 1 Millard DR Jr. **Cleft Craft. Vol I. Boston:** Little Brown, 1980.
- 2 Noordhoff, S. **Atlas of unilateral cleft lip repair**, 1997 Noordhoff craniofacial foundation, Taipie.
- 3 Blair V. and J. Brown, **Mirault operation for single harelip.** Surg Gynecol obstet, 1930 51:P. 81
- 4 Poole RJr: **Analysis of anatomy & geometry of unilateral cleft lip.** Plast Reconstr Surg 24: 311, 1959.
- 5 A De Mey, I Van Hoof, G De Roy, M Lejour, **Anatomy of Orbicularis Oris Muscle in Cleft Lip;** Br J plast Surg 42:710-714, 1989
- 6 Chul Gyoo Park, Bha, **Importance of Accurate Repair of Orbicularis Oris Muscle in the Correction of Unilateral Cleft Lip,** Plast Reconstr Surg 96: 780-788, 1995
- 7 Musgrave Rh: **General aspects of Unilateral Cleft Lip repair** in Crabb WC, Rosentein SW, Bzoch KR (eds), **Cleft Lip and Palate Surgical, dental and speech aspects.** Boston, little brown, 1971, Ch. 11
- 8 Afifi G Y, Hardesty R A, **Bilateral Cleft Lip Repair.** In; Achauer B M, ed. **Plastic Surgery; Indications, Operations and Outcomes.** Saint Louis: Mosby, 2000.
- 9 Salyer: **Primary unilateral cleft lip / nose repair in salyer & bardach's atlas of craniofacial & cleft surgery.** Vol II. Cleft lip & palate surgery: 123-332, 1998
- 10 Trott JA: **Synchronous open Rhinoplasty in Primary Unilateral Cleft Lip Repair, Trott's Technique:** In Salyer & Bardach's atlas of craniofacial & cleft surgery. Vol II Cleft lip & palate surgery: 464-471, 1998
- 11 T Takato, Yyonchara, T Susami: **Early correction of the nose in unilateral cleft lip patients using an open method,** J oral maxillofac surg 53:28-33, 1995