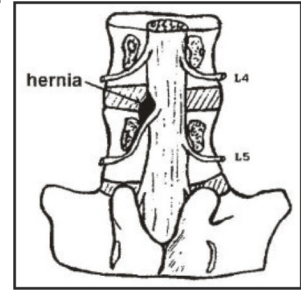


CASE REPORT

PROF-992

LITTRE'S HERNIA**DR. NAEEM SHAHID, FCPS (SURG)**

Department of Surgery
PAC Hospital Kamra,
Distt Attock.

DR KHALID IBRAHIM FCPS (SURG)

Department of Surgery
PAC Hospital Kamra,
Distt Attock.

Copyrights: 15 October, 2005.

INTRODUCTION

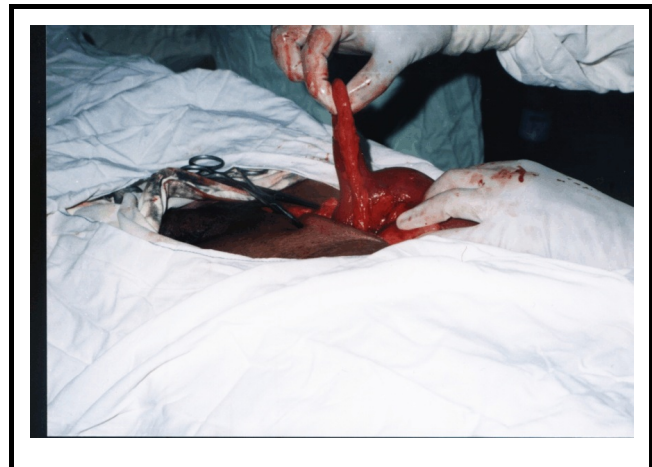[address:naeemsurg@hotmail.com](mailto:naeemsurg@hotmail.com). Meckel's diverticulum is the commonest congenital anomaly of the gastrointestinal tract, occurring in approximately 2% of the population. Most of the Meckel's diverticula are entirely asymptomatic, which are incidentally discovered during autopsy, exploratory laparotomy, or barium studies. The clinical presentation of a Meckel's diverticulum can be gastrointestinal bleeding, intestinal obstruction or diverticulitis. Intestinal obstruction may occur as a result of a volvulus, intussusception, or, very rarely, Littre's hernia (incarceration of the Meckel's diverticulum in an inguinal hernia).

CASE REPORT

A 60 years old male, presented with vomiting, central abdominal pain and swelling over the right inguinal area for the last ten days. There was history of absolute constipation for the last two days. There was no history of loose motions, fever, bleeding per rectum or any previous operative procedure. He was not a known hypertensive or diabetic.

On clinical examination, patient was tachycardiac (pulse 100 / min), BP 150/90 mm Hg and afebrile. Hydration was fair. Abdominal examination revealed irreducible, tender, locally hot, right inguinal hernia with absent bowel

sounds. Examination of other systems was unremarkable. Diagnosis of strangulated indirect right inguinal hernia was made. Emergency operation was planned after resuscitation of patient with intravenous fluids and antibiotics.



A longitudinal incision above and parallel to right inguinal ligament was made. Inguinal canal was opened, hernial sac identified and opened. Foul smelling fluid was mopped up and constriction ring over internal inguinal ring was divided. Hernial sac contained inflamed Meckel's diverticulum (Littre's Hernia) along with adjoining small gut [Fig-1]. Meckel's diverticulum was excised and gut repaired in two layers. Gut was returned

to the peritoneal cavity and hernial sac was closed at the highest point. Internal inguinal ring was closed after performing right orchidectomy. Darning was done with number 1 Prolene and wound was closed in layers without drainage. Patient made an uneventful recovery.

DISCUSSION

Meckel's diverticulum was first reported by Hildanus and then described in detail by Johann Friedrich Meckel¹. Meckel's diverticulum is the most common congenital anomaly of the gastrointestinal tract. It arises when the intestinal portion of vitelline or omphalomesenteric duct which connects fetal gut to the yolk sac fails to obliterate during the fifth to seventh week of gestation.

Meckel's diverticulum is present in 2% of the population. It is situated on the anti mesenteric border of the small intestine; commonly 60cm from the ileo-caecal valve (rarely up to 180 cm from the valve). Meckel's diverticulum is usually less than 12 cm long but can vary from 0.5 to 56 cm². Its diameter is normally up to 2 cm¹. In contrast to other diverticula of small intestine, Meckel's diverticulum is a true diverticulum as it possesses all the three coats of the intestinal wall and has its own blood supply. As cells lining the vitelline duct are pluripotent; in 60% of the cases, the mucosa contains heterotrophic epithelium, namely gastric (60%) followed by the pancreatic acini, others include Brunner's glands, pancreatic islets, colonic mucosa, endometriosis, and hepato-biliary tissues³. An equal incidence is found among men and women⁴.

A Meckel's diverticulum, like an appendix, may be present throughout life and never cause symptoms, or it may have diverse clinical presentation and even life-threatening difficulty. Meckel's diverticulum only reveals itself whenever a complication occurs; the lifetime incidence of which is approximately 4%³. More than half of cases who develop Meckel's diverticula related complications are younger than 10 years of age. The complications of Meckel's diverticulum are bleeding, intestinal obstruction, diverticulitis, enterolith, and tumours.

Intestinal obstruction caused by Meckel's diverticulum is

the most common presentation in adults³. It can result from several mechanisms;

1. Volvulus of the intestine around the fibrous band attaching the diverticulum to the umbilicus.
 2. Internal herniation around a band attaching the diverticulum to umbilicus or another viscus.
 3. Entrapment of intestine by a mesodiverticulum band.
 4. Mesodiverticular band causing direct ileal obstruction.
 5. Intussusception with the diverticulum acting as a lead point (common in children).
 6. Stricture secondary to chronic diverticulitis.
 7. Adhesive obstruction secondary to previous diverticulitis.
 8. Diverticulum may invert into the gut lumen causing an obturating obstruction.
 9. Axial volvulus of the diverticulum.
 10. Obstruction may occur in neonates due to prolapse or extrusion of ileum through the umbilicus via patent vitelline duct.
- OR
11. Littre's hernia^{1,2,3,5}.

A Littre's Hernia is an inguinal or femoral hernia that contains a Meckel's diverticulum in the hernial sac. Although Alexis Littre first described the condition in relation to a femoral hernia in 1770⁶, the relative distribution of Littre's hernia is as follows: inguinal 50%, femoral 20%, umbilical 20% and miscellaneous 10%. Littre's hernia of groin is more common in men and on the right side (as was the presentation in our case). The clinical findings are similar to those of Richter's hernia; when strangulation is present, pain, fever and manifestations of small bowel obstruction occurs late. Faecal fistulas may develop if the condition is unrecognized and strangulation leads to a local perforation within the sac⁷.

The preoperative diagnosis of Meckel's diverticulum is very difficult. In the absence of bleeding, Meckel's diverticula are rarely diagnosed prior to the surgical intervention. It requires a high index of suspicion and the clinical signs and symptoms to help focus the radiological

evaluation. Different modalities which are available are:

- a Technetium-99m Sodium Pertechnetate scan to identify ectopic gastric mucosa (90% accuracy in children but less than 50% in adults; sensitivity and specificity can be increased by the use of pentagastrin, glucagon or cimetidine¹, a negative scan at any age does not rule out the diverticulum.
- b Contrast studies as small bowel follow through to detect the presence of diverticulum, or presence of small bowel intussusception (75% accuracy³.
- c Bleeding scans and angiography.
- d Computerized tomographic scanning (too low a sensitivity to be of any clinical use).
- e Plain abdominal radiographs and ultrasonography are rarely of any help.

The treatment of intestinal obstruction caused by Meckel's diverticulum is surgical excision. When the diverticulum has a narrow base, it may be excised by placing clamps diagonally across the base, flush with the ileal wall. When the base of the diverticulum is broad, a 'V' excision of the diverticulum and adjacent ileal wall should be done⁸. Diverticulectomy can be performed using either a hand-sewn technique or a stapler. When an inverted Meckel's diverticulum is found to be irreducible, resection of the involved segment of the ileum is indicated, followed by an end-to-end ileoileostomy. Any associated offending bands if present may also have to be divided. In Littre's hernia, hernia has to be treated at its own merit. Laparoscopic diverticulectomy is also a safe technique⁹.

Management of the incidental Meckel's diverticulum at exploratory laparotomy is quite controversial. The majority of surgeons would remove an incidental Meckel's diverticulum in children less than 2 years of age¹. The treatment of incidental Meckel's diverticulum in adults patients is quite controversial¹⁰.

The guidelines for diverticulectomy are;

- 1 The presence of palpable nodules in the wall of

diverticulum¹¹.

- 2 Diverticula with a narrow base¹²;
- 3 A long diverticulum;
- 4 Findings at laparotomy suggesting prior diverticulitis, like scarring or adhesions;
- 5 The presence of a band attaching the Meckel's diverticulum to the umbilicus or another viscus;
- 6 Diverticula in men.

REFERENCE

1. Evers BM: Small Intestine. In: Townsend CM, Beauchamp RD, Evers BM, Mattox KL eds. **Sabiston Textbook of Surgery 17th ed.** Saunders 2004; 1366-1368.
2. Michael NM: **Diverticular disease of the small bowel.** In: Peter JM, Ronald AM eds. Oxford Textbook of Surgery ed. Oxford University Press 1994; 982-985.
3. Whang EE, Ashley SW, Zinner MJ: **Small Intestine.** In: Brunicaardi FC, Andersen D K, Billiar T R, Dunn DL, Hunter J G, et al eds. Schwartz's Principles of Surgery 8th ed. McGraw-Hill 2005; 1043-1045.
4. Albanese CT, Sydorak RM, Harrison MR: **Pediatric Surgery.** In: Way LW, Doherty GM eds. Current Surgical Diagnosis & Treatment 11th ed. McGraw- Hill 2003; 1330-1331.
5. Mutch MG, Linehan DC: **Small Intestine.** In: Doherty GM, Lowney JK, Mason JE, Reznik SI, Smith MA eds. The Washington Manual of Surgery 3rd ed. Lippincott Williams & Wilkins 2002; 237-239.
6. Bennett DH, Kingsnorth AN: Hernias, **Umbilicus and Abdominal wall.** In: Russell RSG, Williams NS, Bulstrode CJK eds. Bailey & Love's Short Practice of Surgery 24th ed. Arnold London 2004; 1273.
7. Kingsnorth A: **Adult Groin Hernias: Acute and Elective.** In: Lumley JSP, Craven JL eds. *SURGERY International.* The Medicine Publishing Company Ltd. 1999; 47:232-238.
8. Meckel's Diverticulectomy. In. Zollinger RM Jr., Zollinger RM Sr. eds. Zollinger's **Atlas of Surgical Operations 8th ed.** McGraw- Hill 2003; 114-115.
9. Sanders LE: **Laparoscopic treatment of Meckel's diverticulum: Obstruction and bleeding managed with minimal morbidity.** Surg Endosc 9:724-727, 1995.
10. Pinero A, Martinez-Barba E, Canteras M, et al: **Surgical management and complications of Meckel's diverticulum in 90 patients.** Eur J Surg 168:8-12, 2002.
11. Steele RJC: **Disorders of the Small Intestine and Vermiform Appendix.** In. Cuschieri SA, Steele RJC, Moosa AR eds. Essential Surgical Practice 4th ed. Arnold 2002; 567-568.
12. Brown SP: **Small Bowel and Related Structures.** In. Ellis BW, Brown SP eds. Hamilton Bailey's Emergency Surgery 13th ed. Arnold 2000; 394-395.

