



## β THALASSEMIA;

### A CASE REPORT OF ORAL AND MAXILLOFACIAL MANIFESTATION FROM POPULATION OF KARACHI PAKISTAN

1. BDS, MS Scholar Oral Surgery, Karachi Medical and Dental College, University of Karachi (Karachi Medical and Dental College)

2. BDS, MSc, FDSRCS, FFDRCSI, FCPS, FDS, RCPS Professor, Head Department of Oral Surgery, Head of Dentistry and Vice Principal Karachi Medical and Dental College.

#### Correspondence Address:

Dr. Syed Muhammad Ali  
Department of Oral Surgery  
Karachi Medical and Dental College  
alischolar14@gmail.com

#### Article received on:

02/08/2016

#### Accepted for publication:

15/12/2016

#### Received after proof reading:

14/02/2017

## INTRODUCTION

Thalassemia is an inherited, autosomal, single gene recessive blood disease which is characterized by reduced or absent amount of hemoglobin.<sup>1-3</sup> The disease is common in peoples living in Mediterranean geographical region.<sup>4</sup> It is also very common in low socio-economic groups and countries<sup>5</sup> and in families where consanguineous marriages are common.<sup>6,7</sup> Hemoglobin is composed of four protein chains, two α and two β globin chains arranged into a hetro-tetramer.<sup>8</sup> In thalassemia patients defects have in either the α or β globin chain causing production of abnormal red blood cells.<sup>2</sup>

β-thalassemia in patients occur in two ways. (1. Transfer of recessive gene from parents to offspring 2) Due to mutations in the HB β gene on autosomal chromosome No. 11. The severity of the disease depends on No. of mutation of genes present in patients. Mutations are characterized as either β<sup>0</sup> or β.<sup>+</sup>. According to the severity, β-thalassemia are classified into three type of β-thalassemia. 1) Thalassemia major, 2) Thalassemia intermediate, and 3). Thalassemia minor.<sup>12</sup>

In thalassemia due to lack of total or partial production of α or β globin results serious effects

**Dr. Syed Muhammad Ali<sup>1</sup>, Prof. Dr. Syed Mahmood Haider<sup>2</sup>**

**ABSTRACT:** Thalassemia is a single gene inherited blood diseases. Its causes abnormalities in in various human organ including oral and maxillofacial regions. A case report of 25 years old, β thalassemia patient from Karachi Pakistan. It is evident from this case report that if blood transfusion start regularly from early age and iron overload is controlled by proper drugs, then intensity of manifestation in oral and maxillofacial regions becomes less and thus increasing life span probability.

**Key words:** β-thalassemia, Oral and Maxillofacial manifestation.

**Article Citation:** Ali SM, Haider SM. β thalassemia; a case report of oral and maxillofacial manifestation from population of Karachi Pakistan. Professional Med J 2017;24(2):352-356. DOI: 10.17957/TPMJ/17.3556

on their bodies,<sup>2,3,9,11,13-16</sup> Beta thalassemia is also responsible of causing various manifestations and complications, resulting multisystem complications due to chronic anemia, iron overload, adverse effects of chelation, and infection due to transfusion. Thus, just a simple hemolytic disease 'anemia' change to a chronic disease with involving various organs with various degree of deformities.<sup>1,17-27</sup>

Anemia due to thalassemia causes body system more physiological activate and bone marrow to compensate blood deficiency.

In thalassemia major, involvement of the facial skeleton resulting in severe disfigurement has been described in several reports.<sup>17-19,23,25,33,28-36</sup> Under the influence of the disorder the typical facial appearance develops; high and bulging cheek bones, retraction of the upper lip, protrusion of the anterior teeth and spacing in other teeth, over-bite or open-bite, and varying degrees of malocclusion. The skeletal changes are the result of proliferation of the bone marrow in the facial skeleton.<sup>22</sup> The proliferated bone marrow is extensively used as an ancillary hematopoietic organ to compensate for the chronic hemolysis. Usually the mandible becomes less enlarged than the maxilla. The dense cortical plates of the

mandible apparently prevent the expansion. The bony changes may occur early in life and tend to persist, particularly in skull.<sup>16,25,32,36</sup> Furthermore tint of lemon color is observed in oral mucosa.

### CASE REPORT

A registered 25year old male  $\beta$  thalassemic patient coming at Husaini blood bank and Institute of Hematological diseases Karachi for blood transfusion and iron therapy was randomly selected for Clinical and Radiological Studies of Oral and Maxillofacial manifestation as case report. He is habitual of pan and betel nut chewing since childhood. His mother tongue is Sindhi. He belongs to a low income family and is not able to afford thalassemic treatment expenses. His family consist of 9 members. Mother and father are normal (carrier). One sister of 12 years and one brother of 11 years died in  $\beta$  - thalassemia. Rest of four members are phenotypically healthy (Carrier). Patient was regularly blood transfused from the age of 5years. From the last three years, he has been coming to Husaini blood bank and Institute of Hematological diseases Karachi for free blood transfusion and iron over loaded treatment and his blood transfusion motivation is internal. He has enlarged spleen but Spleenectomy was not carried out. He has complain of pain in his joints for last three months and also complain of bleeding gum during brushing and sensitive teeth to hot and cold.

On general examination, he looks under-built, under-nourished and short stature, with evident icterus, and yellow tinged finger nails. Intra oral examination showed intra oral pigmentation on hard palate and buccal mucosa. Spacing are not evident. Proclination of upper anterior teeth are prominent. Multiple decayed teeth with heavy deposition of calculus and plaque on upper and lower teeth with dark stains are prominent. Mamelons are not present and intra oral color of mucosa is pale yellow.

Extra oral examination findings, disclosed that color of skin is light muddy black. Frontal and

parietal bossing are present. Depressed nasal bridge is evident. Maxillary pragmatism is present. Radiographic findings(X- ray cephalometric lateral view) illustrated that class 2 skeletal patterns, Mandibular retrognathism, high angle in dental analysis, bimaxillary proclination in soft tissue analysis, incompetent lips, deep mento labial sulcus skeletal high angle case and increase lower facial height, widening of diploic space and salt and pepper appearance of skull are present.

X ray OPG findings disclose that all permanent teeth are presents. All 3<sup>rd</sup> molar are present and erupted. Periodontal recession of upper and low anterior teeth vertical bone lose. Short spiky roots and alteration of trabecular pattern is evident.

### DISCUSSION

Generally the findings recorded in this case confirm the work carried out by different worker throughout the world<sup>19,23,25,30,32</sup> Elhametal., (2002)<sup>19</sup> and Hashemipour *etal.* (2007)<sup>22</sup>, Bassimiti *et al.* (1996)<sup>29</sup> described mandible less enlarged than maxilla and it is also found in the present case report. Class 2 skeletal pattern was reported by Aminiet *al.* (2007)<sup>24</sup> Hattab & Patterns. (2013)<sup>27</sup> and in the present study the skeletal pattern class 2. Depressed nasal bridge, yellow tinge oral mucosa, bimaxillary proclination, maxillary prognathism are reported by Amini *et al.* (2007)<sup>20</sup> Hashemipouri *et al.* (2007)<sup>22</sup>, Babu & Amitha (2014).<sup>31</sup> Nagaraj *et al.* (2011).<sup>42</sup> And these all features are also present in present study confirm their results. Malnourished, underweight and short stature are very common in thalassemic patient Anonym (2012)<sup>37</sup> and it is also true and found in present study. Generally the skin color in thalassemic patient were reported pale yellow.<sup>1,10,12,16</sup> However skin muddy black is also reported [41]. In our case the skin color of patient is muddy black. Mamelons and space between teeth are generally found in thalassemic patient<sup>40,41</sup>, but these features are not found in this case. Short spiky roots and diploic space reported by Patil [2006]<sup>17</sup>, Hazza. *etal.* (2006)<sup>22</sup>, Rashin *etal.* (2010)<sup>23</sup>, Babu & Amitha (2014)<sup>40</sup> and Nagaraj *et al.* (2011).<sup>41</sup>

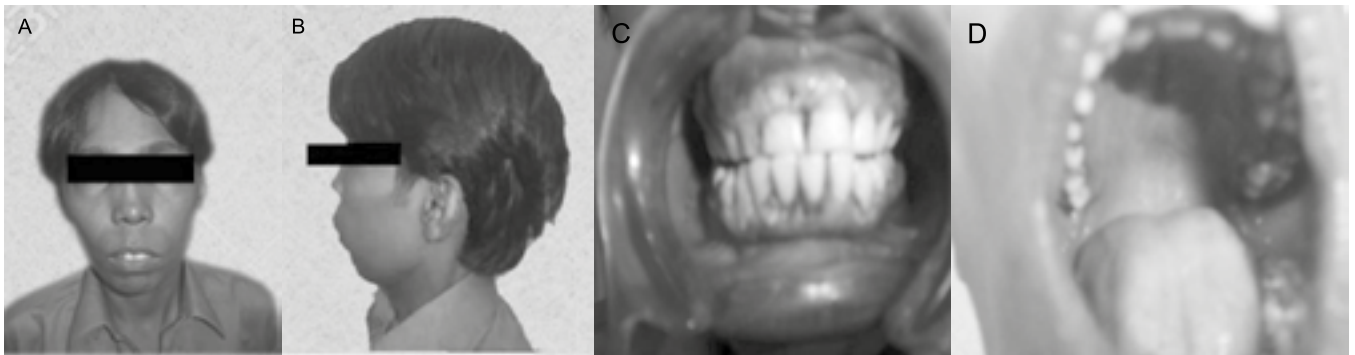

Figure-1.A Showing icterus in the eyes, Showing classical “Chipmunk facies” with depressed Cranial vault, frontal bossing, maxillary expansion, retracted upper lip and saddle nose. B. lateral view of patient shows maxillary prognathism and retrognathism of mandible. C. shows The gingival recession and gingivitis and generalized heavy deposition of plaque and calculus with heavy stains. D. Showing yellowish tinge at the junction of hard and soft palate

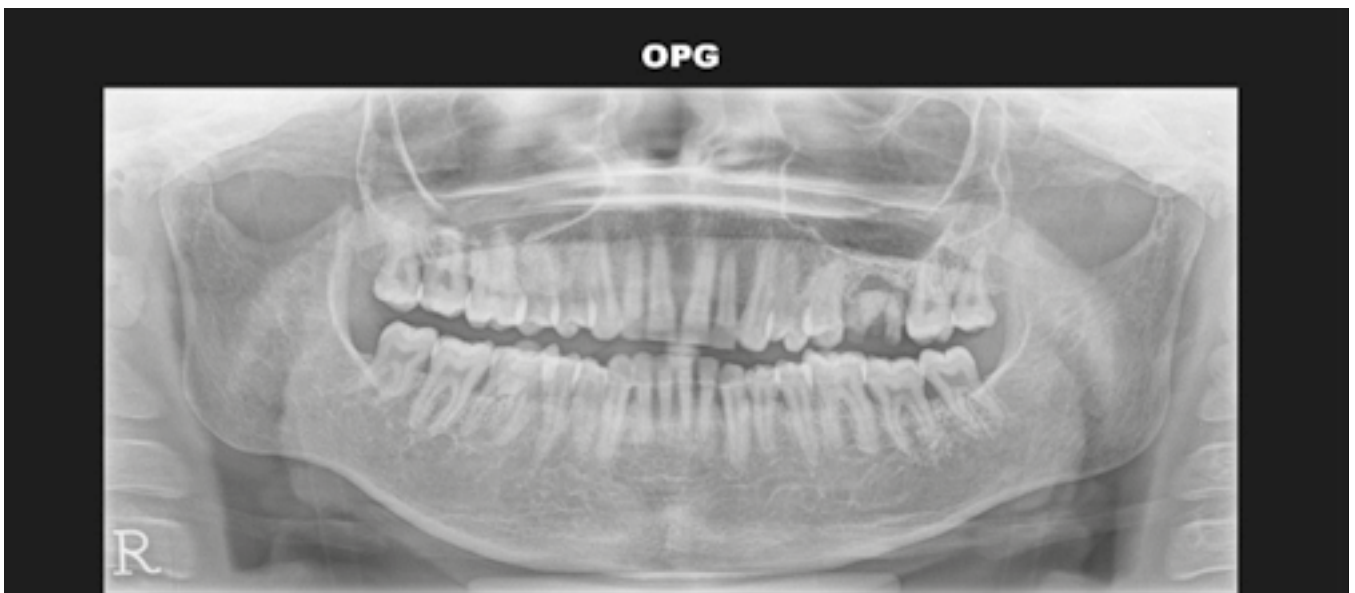


Figure-2. OPG showing presence of alteration of trabecular pattern and short spiky roots

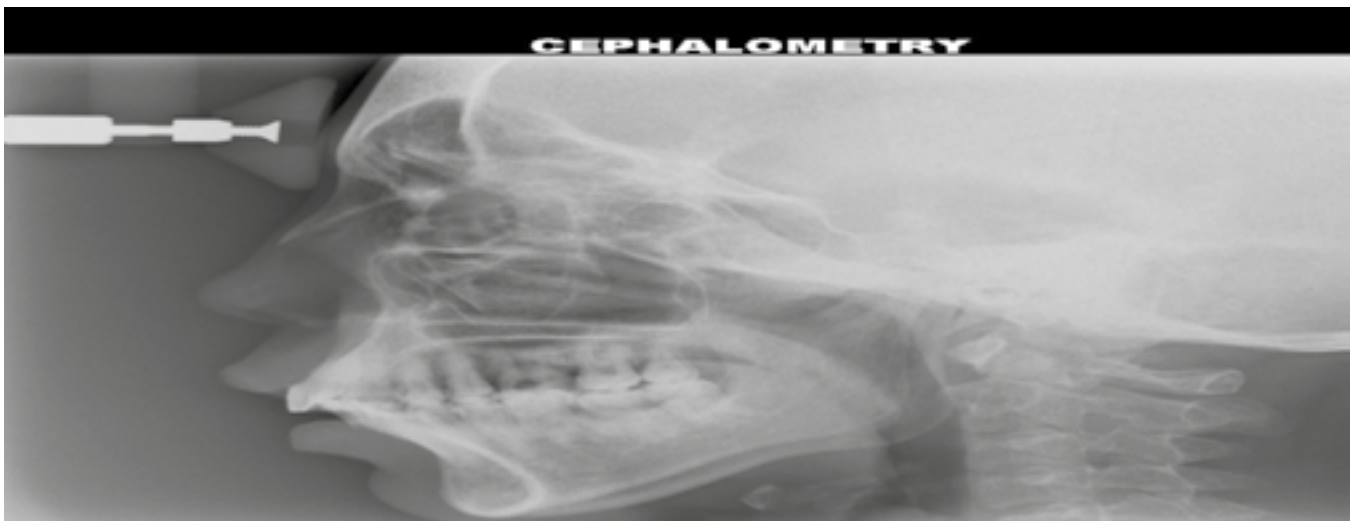


Figure-3. Lateral cephalogram showing, widening of diploic space and salt and pepper appearance of the skull.

## CONCLUSION

Findings found In this case report are generally agree with the previous work done in other parts of world. However in the present study teeth spaces among the teeth are not present. Manifestation intensity in oral and maxillofacial organs are comparatively low and this seems to be due to starting of early age blood transfusion and control on iron over load and thus the abnormalities are not so prominent, where as in the same family where blood transfusion was not started early and properly two members of the family died in thalassemia. In present study patient with minimum abnormalities and reaching the 25 years age is an achievement with the hope that if patient will continue blood transfusion regularly and continued treatment of over loading of iron then, he will have a long spin of life.

Copyright© 15 Dec, 2016.


## REFERENCES

- Rund, D. and E. Rachmilewitz. 2005. **Medical progress β-Thalassemia**. NEJM353 (11): 1135-1146.
- Verma, I. C., R. Saxena, and S. Kohli. 2011. **Past, present & future scenario of thalassaemic care & control in India**. Indian J Med Res134: 507-521.
- Flint, J., F.M. Harding, A. J., Boyce and J. B., Clegg. 1998. **The population genetics of haemoglobinopathies**. Bailliere;s Clin. Haematol.11 (1):1-15.
- Hussain, R. 2000. **Socio-demorphic correlates of in Muslim population of Ind**. J. BiosocialSci.32:433-444.
- Jaber, L., G. J. Halpern, and M. Shohat.1998. **The impact of consanguinity worldwide**. Community Genetics 1: 12-17
- Naidu L.D., S. M. Raju, and G, sumit. 2010. **Effect of consanguineous marriages on oral and cariofacial structure: A study on dental patients in north India**. Annals Essences of Dentistry 2(4): 199-203
- Thein, S. L., (2005). **Genetic modifiers of β -thalassamia**. Haematologia. 90: 649-660.
- S. Riazuddin and R. Galanello. 2000. **Identification of three rare β-thalassemia mutations in the Pakistani population**. Hemoglobin24(1):15-22.
- Raihan, S., G. Farooq, A., Salman and K., Mohammad. 2009. **Thalassemia Major**. Journal of the Pakistan Medical Association 59(6):388-90.
- Galanello, R., and R. Origa. 2010. **β-thalassemia Orphanet Journal of Rare Diseases** 2010, 5:11.
- Khan, S. A., S.A., Khattak, A. Jaleel, N.A. Anwar, H.S. Kashif. 2012. **β-thalassemia and its association with haematological parameters**. J Pak Med Assoc. 62 (1):40-3.
- Bejaoui, M and N. Guirat. 2013. **β-Thalassemia Major in a Developing Country: Epidemiological, Clinical and Evolutionary Aspects Mediterr**. J.Hemato. Infect. Dis. 5(1): e2013002.
- Kang, J. H. B. R. Park, K. S. Kim, D. Y. Kim, H. J. Huh, S. L. Chae, S. J. Shin. 2013. **β -Thalassemia Minor Is Associated with IgA Nephropathy**. Ann Lab Med 33(2): 153 – 155.
- Bunn.H.F.F.B.1984. **Hamoglobin Moleculare Genetics and clinical assessment**. W. B. Saunders Copampany.
- Bridge, K., 1998. **How do people get thalassemia? Information center for sickle cell and thalassemia disorder [cited 16/11/2007, available from [http://sickle.bwh.harvard.edu/tha\\_inheritance.html](http://sickle.bwh.harvard.edu/tha_inheritance.html)].**
- Patil, S. 2006, **Clinical and Radiological study of Oro-facial manifestation in Thalassemia**. Thesis of Master of Dental surgery in oral Medicine and surgery. Deptt. of Oral.
- Van dis M. L. and R. P., Langlias. 1986. **The thalassaemia: Oral manifestations and complications**. Oral surgery, Oral Medicine, Oral Pathology62:229-223.
- Higgs, D. R., S. L, Thein and W.G.Wood., 2001.**The molecular pathology of thalassemias**.
- Old, J.M., N.I.Oliveri and S.L., Thein. 2001. **Diagnosis and management of Thalassemia in: Weather all, D. J., B., Clegg, eds**. The thalassemia syndromes 4th ed. Oxford, England: Blackwell Sciene. 30-685.
- Weatherall, D. J., B., Clegg, eds 2005. **The thalassemia syndromes 4th ed**. Oxford, England: Blackwell Sciene. 30-685.
- Chakraborty and S.P. Basu. 1971. **Observations on radiological changes of bones in thalassemia syndrome**. J. Indian Medical Association 57:90-95.
- Logothetis, J., J. Economidou, M. Constantoulakis, O. Augoustaki, R.B. Lowe and M.
- Bilek. 1971. **Cephalo facial deformities in thalassemia major (Cooley's anemia): A corrective study among 138 cases**. American J. Diseases in children 121:300-306.



24. Elham, S. J., Abu Alhaji, N. H. Faiez and A. O. A., **Mohammad. 2002. Cephalometric measurement and facial deformities in subjects with β- thalassemia major European J. of Orthodontics**24:9-19.
25. Seyyedi, A. and H., Nabavizadeh. 2003. **Epidemiological study of the oral and maxillofacial changes in β-Thalassemia patients in Boyer Ahmad. BeheshtiUniv Dent J** 2003; 21 (4): 510-517.
26. Cunningham, M. I., E. A., Macklin, E.J., Neufield and A.R., Cohen.2004. **Complication of β-thalassemia major in North America. Blood**104: 34-39.
27. Hazza,A., A.M. G., and AL-Jamal.2006. **Radiographic features of the jaws and teeth in thalassaemia major Dentomaxillofacial Radiology.** 35 (4): 283-8.
28. Amini, F., A. Jafari, L. Eslamian and S Sharifzadeh 2007. **A cephalometric study on craniofacial morphology of Iranian children with beta-thalassemia major. Ali Asghar Hospital. J Dent TehranUniv. Med.Sci.**16 (2):16-24.
29. Mehdizadeh, M., M. Mojdeh, and Z.Gholamreza.2008. **Oro dental Complications in Patients with Major β--Thalassemia. Dent Res. J.5 (1): 17-20.**
30. Hashemipour M.S. and M. Ebrahimi. 2008. **Orofacialdisformation in thalassemia patients referred to Kerman SJB** 5(3): 185-193.
31. Rashi, T., M. Pankaj, S. Mamta, and A. Mahesh C I .2010. **Multiple transfused thalassemia major: Ocular manifestations in a hospital-based population Indian J Ophthalmol.** 58(2): 125–130.
32. Tejavathi,N., N. Umashree, R. D. Achut, S. N. Sharkaran. 2011. **β- thalassemia major: A case report. J. Inter. Oral Health**5:76-77
33. Hyder S.N., Kazmi U., and A.Malik. 2013. **Anechocardiographic evaluation of left ventricular function in patients with thalassemia major. J Pak Med Stud** 3 (1):10-15.
34. Anonym.2005. **Thalassemia.Com.PK.** Faith Group. Faith Foundation. Pakistan.
35. Poyton,H.G., and K.W. Davey. 1968. **Thalassemia: Changes visible in radiographs used in dentistry. Oral surgery, Oral medicine, Oral pathology** 25:564-756.
36. Well, F., I. T .Jackson, W A. Crookendale and J. Mckicchan 1987. **A case of thalassaemia major with gross dental and jaw deformities. British journal of oral and maxillofacial surgery**25:348-352.
37. Bassimiti,S., E. Yucel-Eroglu, and M. Akhtar.1996. **Effects of thalassemia major on component of the Oriiofacial complex British J. of Orthodontics** 23:157-162.
38. Abu Alhaja, E. S. J., M. F. N. Hattab, M.A. Al-Qamari.2002. **Cephalometric measurements and facial deformities in subject with β- Thalassemia major. Euro.J. Orthodon.**24:1-9.
39. Baig, S.M. A. Azhar, H. Hassan, J.M. Baig, M. Aslam and M.A. Ud Din.2006. **Prenatal diagnosis of β-thalassemia in Southern Punjab, Pakistan. PrenatDiagn**26 (10): 903-5.
40. Hattab, F., and N. Patterns.2013. **Of physical growth and dental development in jordanian children and adolescents with thalassemia major, Journal of Oral Science,** 55(1): 71-77.
41. Anonym.2012. **160 thalassemia cases diagnosed at Pakistan institute of medical sciences PIMS Islamabad in 4 years Pak. Med. Info. Forum.**
42. Anonym.2013. **6000 kids suffer from Thalassaemia. The Nation Islamabad Pakistan** dated 13-3-2013.

### AUTHORSHIP AND CONTRIBUTION DECLARATION

Sr. #	Author-s Full Name	Contribution to the paper	Author=s Signature
1	Dr. Syed Muhammad Ali	Resercher and Writer	
2	Prof. Dr. Syed Mahmood Haider	Supervisor and Main guidance	