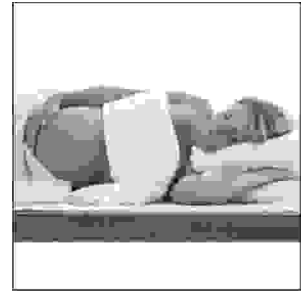


CASE REPORT

PROF-1045

EHLER DANLOS SYNDROME WITH PREGNANCY

**DR. NABEELA ATA**

Postgraduate Registrar,
Gynae Unit-III,
Nishtar Hospital, Multan.

DR. SAMEE AKHTAR

Professor of Gynaecology and Obstetrics,
Nishtar Medical College/Hospital, Multan.

INTRODUCTION

Ehlers Danlos syndrome is a group of disorders, which have common feature including easy bruising joint hypermobility skin that stretches easily and weakness of tissue¹. It is inherited in the genes that are passed from parents to off spring. They are categorized according to the form of genetic transmission into different types with many features differing between patients in any given type. In 2001, researches discovered a new form or Ehlers Danlos syndrome that is caused by an inherited abnormality in a protein other than collagen that also normally plays a role in binding together the cells of our tissue (including the skin, tendons, muscle and blood vessels). Abnormalities in this protein called tenascin, also lead to a form that tensacin could play a role in regulating the normal distribution of collage in connective time of the body².

CASE REPORT

Mrs. Asia Hameed, 32 years of age, G5 POA4 was admitted in labour room with gestational amenorrhoea of 20 weeks with the history of fall on the same day, as an emergency case on 13-5-2004. She was fully conscious when received, her vitals were stable, except the increased respiratory rate. Abdomen was soft, consistent with period of gestation, no marks of external injury was noted all over the body, except 3 bruises over her arm

and forearms. On investigation, her blood group was found to be A +ve, Hb 10.5% and platelets count 18200 lakhs. Rest of biochemical investigations were normal except her prolonged APTT and PT. Sonographic finding showed single active fetus of 20 weeks of fetal biometry. There is an episode of bleeding vaginally, which was mild. She had been consulted by cardiologist for increased respiratory rate. Her echocardiography was normal, but she was given Tab. Lasoride and digoxin but had only symptomatic relief. An expert opinion was taken by consultant physician as well, after thorough history and examination, she was diagnosed as a case of Ehler Dalson syndrome, on the basis of hypermobile joints, high arched palate, bruises, due to fragile blood vessels, proximal muscle weaken. The final management planned was to built up her Hb%, omit digoxin and lasoride, having one pint of blood in hand, termination is planned after counseling the patient.

As the blood arranged, at 26 week of gestation repairing initiated with prostaglandins. She did not start any uterine contraction, it was repeated again and after the failure of change in chemical status establishment of uterine contraction, her caesarean section was planned.

It was done on list, in the presence of senior anaesthetist and obstetrician. She delivered a baby girl of 0/10 A/S

weighing 1.5 kg. Bilateral tubal ligation was done. She did well in her postoperative period except dyspnoea, which resolved spontaneously.

DISCUSSION

The Ehlers Danlos syndrome is a group of genetic condition that have resulted from defects in a collagen molecule which would give strength and adhesion to the body's tissue¹. It has different types, namely classical type, hyper mobility type, vascular type, kyphoscoliosis type, dematospaxis type and lastly tenascin X deficient types. It is believed to affect 1 in 5000 people. The healing of both accidental and surgical wound is frequently very poor leaving dramatic scar, other problems often include prolapse of mitral valve, amemysmus, hernia and range of orthopedic and dental problems. The manner in which it affects patient in degree of severity is entirely unpredictable. A Dutch study was conducted in pregnancy with Ehler Danlos syndrome. The conclusion of that study was pregnancy well tolerated in a woman with Ehler Danlos syndrome, with favourable maternal and neonatal outcome⁴. In Ehlers Danlos syndrome type-IV it may be associated with severe maternal complication. Pre-conceptual counseling concerns specific possible complication and multi-disciplinary approach are recommended⁵. The study was conducted by department of Obstetrics and Gynaecology, Weslende Hospital, to assess the course and outcome of pregnancies with Enter Danlos syndrome with aim of developing guideline for

assessment of risk and counseling and for providing optimum medical and obstetrical care. The Ehlers Danlos syndrome are treated according to what particular manifestation present in a given individual skin protection is critical. Wound must be treated with great care and infection treated and prevented. Joint injury must be avoided; contact sports and activities involving joints impact should be avoided.

REFERENCES

1. Craing J, Haynes a, McClelland D. **Blood disorders**. In: Haslett c, Chinless E, Boon N, Colledge N. Davidson's Principles and practice of medicine. 19th ed. Edinburgh. Churchill Livingstone. 2002; 947.
2. Shipley M, Black CM, Compston J, O'Gradaigh D. **Rheumatology and bone diseases**. In: Kumar P. Clark M. Clinical Medicine. 5th ed. London. WB Saunders. 2002; 571, 585, 1311.
3. Hamel BCJ, Palas G, Engles CHAM. **Ehler – Danlos syndrome and type-III collagen abnormalities: a variable clinical spectrum**. Clin Genet 1998; 53: 440-46.
4. Lind, Jan and Wallenberg, Henk CS. **Pregnancy and Ehlers Danlos syndrome: a retrospective study in Dutr population**. Acta Obstetrician et Gynaecological Scandinavica 2002; 81: 293-300.
5. Letsky EA. **Coagulation defects in pregnancy and the puerperium**. In: Chamberlain G, Steer PJ. Turnbull's obstetrics. 3rd ed. London. Churchill Livingstone. 2001; 311-32.

A picture is a poem without words.

Horace

