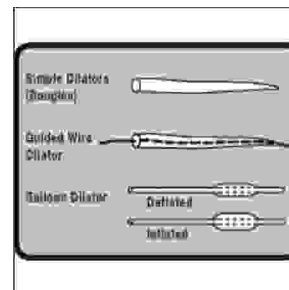


ORIGINAL

PROF-1031

# ESOPHAGEAL DILATATIONS



**DR. IFTIKHAR HUSSAIN KHAN, FRCS, FCPS**  
 Assistant professor Surgery  
 Nishtar Medical College/Hospital, Multan.

**DR. KHALID HUSSAIN QURESHI, FCPS**  
 Assistant professor Surgery  
 Nishtar Medical College/Hospital, Multan.

**DR. MUHAMMAD ALI, FCPS**  
 Associate professor Medicine  
 Nishtar Medical College/Hospital, Multan.

**ABSTRACT...** 508 esophageal dilatations were performed in our unit from January 2003 to May 2005. These dilatations were performed using Savary Gilliard dilator system. Instead of using image intensifier to confirm guide wire position, abdominal palpation was used for this purpose. 508 dilatations were performed in a total of 119 patients. Sixty three patients underwent more than one dilatation. 71 dilatations were performed under local anaesthesia using flexed scope 437 were performed under general anaesthesia using rigid scope. Our postoperative observation protocol is given which was developed to pick up iatrogenic esophageal tear at an early stage. Out of 508 dilatation performed, 18 perforations occurred. Eleven patients had a minor confined leak. They were managed conservatively and all survived. Seven patients had a major leak. Out of those, three died resulting in an overall 0.59% procedure related mortality, while mortality for major leak group was 43%. None of the patients undergoing dilatation under local anaesthetic had a perforation. Following the protocol, no significant iatrogenic esophageal injury was missed. We conclude that esophageal dilatation can safely be performed using Savary Gilliard dilator system. Correct positioning of guide wire can confidently be confirmed by abdominal palpation in a large majority of patients. Minor leaks can be managed conservatively with excellent outcome. A well functioning protocol to pick up any iatrogenic esophageal injury early is vital to keep a dilatation programme safe.

## INTRODUCTION

Esophageal dilatation may be required for variety of reasons. Many different types of dilators are in use<sup>4-10</sup>. In general, a dilator passed over a correctly placed guide wire is considered to be the safest<sup>4,5,6,13</sup>. We use Savary Gilliard system (Wilson-Cook Medical GI Endoscopy; Winston – Salem USA) in which serial bougies are passed over a 0.0038 inches diameter guide wire with floppy tip. Results of 508 consecutive dilatations

performed in our unit are presented.

## PURPOSE OF STUDY

To audit the results of esophageal dilatation programme at our unit, especially to evaluate safety of Savary Gilliard system using our modifications.

## MATERIAL AND METHOD

A study was conducted to analyze the results of all

esophageal dilatation done in our unit and at practice of one of the authors (IHK) from January 2003 to May 2005. Data was collected by reviewing case notes, searching hospital records and unit's data base and contacting patients where necessary. Data was analyzed using Microsoft Access-2000 software.

### Technique

Flexible or rigid esophagoscope is passed under suitable anaesthetic and stricture is visualized. A 0.0038 inch diameter steel guide wire with floppy spring tip is passed under direct vision across the stricture and into the stomach. Correct position of the wire is confirmed by palpating abdomen. A correctly placed guide wire is typically felt in the left upper abdomen going towards the right following greater curve of the stomach, especially when the patient is relaxed under General Anesthesia (GA). Where the procedure is being performed under Local Anesthesia (LA) using flexible gastroscope, wire can similarly be palpated by turning the patient over onto his back. Patient can also tell that he can feel the wire flipping in his stomach.

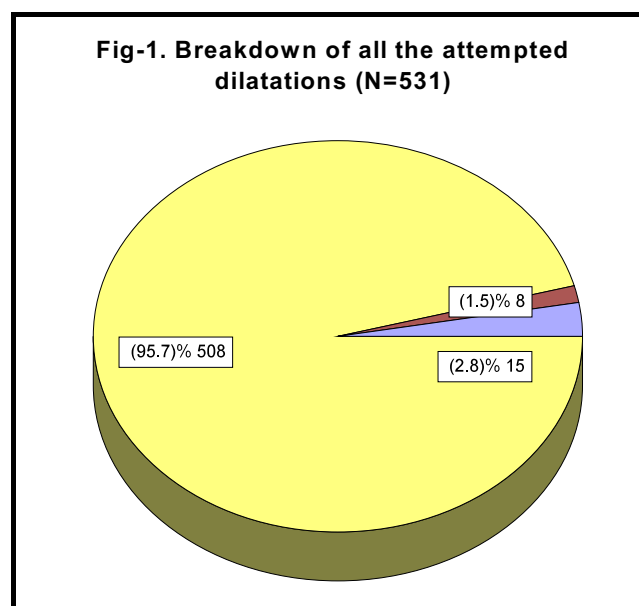
When guide wire cannot confidently be palpated in the abdomen, either a per-operative X-Ray of lower chest and upper abdomen is obtained to confirm the position or the procedure is repeated under image intensifier. When the guide wire is correctly in place, serially larger bougies are passed over the guide wire. With each bougie passed, tightness of the stricture is assessed. Care is taken not to apply too much force. After use, each bougie is wiped on a clean gauze. When light pink blood stained secretion is noted on the gauze, next sized dilator is not passed<sup>6,11,13</sup>.

After dilatation, patient is observed in ward for 6-8 hours. Junior medical staff is instructed to keep a very low threshold for esophageal tear. Any patient who shows hemodynamic instability, complains of the pain in the chest or back (pain in the throat is ignored unless there is surgical emphysema in the neck), creptus in the neck, pyrexia above 100 °F requiring more than one dose of antipyretics, hoarseness, major haemoptysis or decreased air entry on either side of the chest, is considered to have a perforation. Such patient is retained

in the hospital, he is started on 3<sup>rd</sup> generation cephalosporin plus metronedazol intravenously, I.V. fluids are continued, plain chest X-Ray is obtained and the patient is kept nil by mouth till consultant opinion is available<sup>14</sup>. If the consultant agrees with the possibility of a perforation, barium swallow is obtained and the patient is managed accordingly. In case patient's post operative course is uneventful, he is discharged 6-8 hours after the procedure i.e. as soon as he is fully recovered from the anaesthesia and has taken orally. Most patients requiring regular dilatations come fasting in the morning and go home early in the afternoon.

### RESULTS

A total of 531 dilatations were attempted during the study period. In 8(1.5%) cases, guide wire could not be passed. In 15(2.8%) cases guide wire did go down but could not reliably be palpated in the abdomen. In these cases, the procedure was repeated under image intensifier at a later date. In 508 cases, dilatation was carried out (Fig-1).



71(14%) dilatations were performed under LA±sedation using flexible gastroscope. 437(86%) dilatations were performed under short GA using rigid esophagoscope. All dilatations in children under 12 years of age were performed under GA. Age, sex and etiological distribution of the patients is given in the table-I. These 508 procedures were performed on a total of 119 patients.

63(53%) patients underwent more than one dilatation during the study period. Average number of dilatations per patient was 7.2 (range = 2-14). No perforation occurred in patients where procedure was done under LA. During post operative observation period, junior medical staff labeled 68 patients (13.4%) as “suspected to have esophageal perforation.”

In 23 cases (4.5%), consultant agreed with the suspicion and barium swallow was obtained. Presence of a leak was confirmed in 18 patients (3.5% of all the dilatations performed and 4.12% of all dilatations performed under GA. 11(2.2%) patients had a minor confined leak. They were treated conservatively with antibiotics, nil by mouth for two weeks and I.V fluids. Nasogastric tube could successfully be passed in 9 of these 11 patients. In these cases, nasogastric tube was used for drainage for the first 5 days and then for feeding. In the remaining two, I.V. nutrition was arranged. All of these 11 patients were well at the end of two weeks and were started on oral

diet. Seven (1.4%) patients had a major leak. Two of them had carcinoma of esophagus, one was managed conservatively with antibiotics, chest intubation, feeding jejunostomy and drainage gastrostomy. He died on eight postoperative day. Second underwent an emergency esophagectomy and made an uneventful recovery. Five patients suffering a major leak had corrosive strictures. They were all managed conservatively with antibiotics, chest intubation, drainage gastrostomy and feeding jejunostomy.

Two of them died on 3<sup>rd</sup> and 12<sup>th</sup> post operative day while 3 survived. Hence, out of 508 dilatations performed, three procedures lead to mortality (0.59%). In all the 18 patients sustaining an esophageal perforations, leak was seen at the level of stricture on barium study. In all these cases, except one (where leak was very large and nearly all the barium leaked into pleural space) barium could be seen entering the stomach.

Table-I. Age, sex & etiology wise distribution of patients undergoing esophageal dilatation

| Age group  | Total no of patients | No of patients |            |                  |    |        |          |                       |           |
|------------|----------------------|----------------|------------|------------------|----|--------|----------|-----------------------|-----------|
|            |                      | Sex wise       |            | Etiology wise    |    |        |          |                       |           |
|            |                      |                |            | Corrosive intake |    | Reflux | Achlasia | Anastomotic stricture | Malignant |
|            |                      | Suicide        | Accidental |                  |    |        |          |                       |           |
| <1 yrs     | -                    | -              | -          | -                | -  | -      | -        | -                     | -         |
| 1-2 yrs    | 17                   | Male           | 10         | -                | 10 | -      | -        | -                     | -         |
|            |                      | Female         | 7          | -                | 7  | -      | -        | -                     | -         |
| >2-8 yrs   | 48                   | Male           | 33         | -                | 28 | 2      | 1        | 2                     | -         |
|            |                      | Female         | 15         | -                | 12 | 2      | 1        | -                     | -         |
| >8-12 yrs  | 14                   | Male           | 10         | -                | 10 | -      | -        | -                     | -         |
|            |                      | Female         | 4          | -                | 3  | -      | 1        | -                     | -         |
| >12-45 yrs | 59                   | Male           | 17         | 6                | 3  | 3      | -        | 1                     | 4         |
|            |                      | Female         | 42         | 21               | 2  | 3      | 3        | 8                     | 5         |
| >45 yrs    | 31                   | Male           | 18         | -                | 2  | 3      | 3        | 2                     | 8         |
|            |                      | Female         | 13         | 2                | -  | 2      | 3        | 3                     | 3         |

**Table-II. Pre-discharge check list for esophageal dilatation patients**

1. **Vital Sign**  
Pulse \_\_\_\_\_/min  
Temp \_\_\_\_\_°F  
B P \_\_\_\_\_mm Hg
2. **Pain in the chest** = Yes / No
3. **Surgical emphysema in the neck** = Yes / No
4. **Major Haemoptysis** = Yes / No
5. **Bilateral good and equal air entry** =Yes / No
6. **Tolerance of oral intake**
7. **Chest X-Ray**  
Not done / Normal / suspicious or abnormal
8. **Follow –up arrangement**

## DISCUSSION

Corrosive ingestion is a common method of attempting suicide in south of Punjab especially in girls. Most of the survivors sustain significant injury to esophagus and/or stomach. Accidental intake of corrosive, especially in children, is also not uncommon. Almost all of them require dilatations, some on regular basis. Our institution is the major tertiary referral center for south Punjab, upper Sindh and adjacent areas of Baluchistan and NWFP. We therefore treat a large number of such patients in our unit. In addition, esophageal strictures due to other etiologies are also seen and treated on regular basis. We do not have access to flexible gastroscope in our unit. We therefore perform esophageal dilatations under short GA using rigid esophagoscope. Dilatations under LA using flexible gastroscope were performed by one of the authors (IHK) at his practice. A single image intensifier is shared between all the operating theaters and is usually not available at our time of need and convenience. We, therefore, do not use image intensifier to confirm position of the guide wire routinely. Image intensifier is only called if there is any doubt regarding correct positioning of the guide wire<sup>2,13</sup>, which is not very common (2.8% in our experience). This method of dilatation that evolved out of desperation has proved so simple, expeditious, safe and efficient that this is now our method of choice for esophageal dilatation. Sparing use of image intensifier saves a lot of expense and effort and helps in efficient use of resources. It is also important to

note that many patients require repeated dilatations<sup>7,12</sup> (53 % of our patients underwent repeated dilatation at an average of 7.2 dilatations each with a range of 2-14 dilatations over 29 month period). These are also the patients who, due to nature of their injury, may need to undergo repeated chest X-Rays and barium swallow examinations. Thus by default, they are prone to repeated radiation exposure. The issue of radiation becomes more significant when one notes that 79 times (15%) the procedure was done in children under 12 years of age. It is known that there is no threshold for the mutations and hence there is no such thing as a safe dose of radiation<sup>1</sup>. We are therefore of the opinion that when ever possible, unnecessary exposure to the radiation should be avoided. We believe that use of abdominal palpation instead of image intensifier to confirm correct position of the guide wire is safe and effective. It is our understanding that in at least 17 out of 18 patients who suffered esophageal tear, guide wire was in correct position and perforation was actually a split of esophageal stricture due to the error of judgment in selecting wrong size of dilator. This is because, in cases where guide wire position is wrong, the wire makes a false passage above the stricture. Dilators passed over this guide wire dilate the false passage, rupturing the esophagus while original lumen of esophagus remains closed at stricture level. In these cases, neither a nasogastric tube can be passed into the stomach nor will barium be seen flowing into the stomach.

Esophageal dilatation inherently carries a risk of esophageal perforation<sup>2,3,7,8,9,13</sup>. Survival and prognosis of these patients depend largely upon early recognition and prompt treatment of this complication in addition to the nature and extent of the disease. Therefore units which do esophageal work should have a system to pick up post dilatation esophageal injuries early<sup>14</sup>. We recommend a protocol of checklist (table-II) which should be completed before the patient is discharged home. Our junior medical staff is instructed to keep a very low threshold for suspecting esophageal injury. If any of the points 1-6 in table-II are unsatisfactory, patient goes for a plain chest X-Ray. If the doctor is still not satisfied or the chest X-Ray is abnormal, patient is retained in the hospital and protocol for the management of iatrogenic

esophageal injury started. Following this routine not a single significant esophageal injury was missed. In our series, we found a very good relationship between an experienced consultant's assessment regarding possibility and actual presence of iatrogenic esophageal injury (18 proven esophageal tears out of 23 suspected by consultant). We also noted the importance of segregating the patients into those having major leaks and those having minor and confined leaks. In our experience, patients with minor confined leaks respond well to conservative management with good survival (100% in our study). Patients having major leaks however had a very high mortality (43%). Encouraged by the result of our one patient sustaining a major leak after split of a malignant stricture who recovered after an emergency esophagectomy, we now consider every such patient for an emergency definitive procedure if possible. However, most of the corrosive injury patients are so poor from general fitness point of view that a major surgical procedure seems like a daunting task which may or may not produce result any better than achieved by our conservative regimen. Absence of any iatrogenic tear in patients under local anesthesia is encouraging. But this may be because of bias in patient selection as one tends to dilate most difficult strictures under GA. Moreover, an awake patient may himself impose a check on use of too big a dilator by complaining of pain.

## CONCLUSION

Esophageal dilatation can safely be performed using serial dilators passed over a properly placed guide wire (e.g. Savary Gilliard dilator system). Correct positioning of guide wire can be confirmed by digital palpation of abdomen and image intensifier is needed only in a small minority of cases. A well functioning protocol to pick up any iatrogenic injury to esophagus is mandatory to keep the dilatation programme safe. Minor and confined leaks can safely be managed conservatively. Esophageal dilation is more safely performed under L/A±sedation using a flexible gastroscopie than under G/A using a rigid scope.

## REFERENCES

1. Armstrong P. **Hazards of exposure to diagnostic radiation.** P.13. In Armstrong P, Wastie ML: Diagnostic Imaging, Blackwell, oxford, 1992.
2. Bailey AD, Goldner F. **Can clinicians accurately assess esophageal dilation without fluoroscopy?** *Gastrointest Endosc* 1990; 36:373.
3. Barkin JS, Taub S, Rogers AI. **The safety of combined endoscopy, biopsy and dilation in esophageal strictures.** *Am J Gastroenterol* 1981; 76:23.
4. Celestin LR, Cambell WB. **A new and safe system for esophageal dilatation.** *Lancet* 1981; 1:74.
5. Cox JGC, Winter RK, Maslin SC et al. **Ballon or bougie for dilatation of benign esophageal stricture? An interim report of a randomized controlled trail.** *Gut* 1988; 29:1741.
6. Dumon JF et al. **A new method of esophageal dilatation using Savory-Gillard bougies.** *Gastrointest Endosc* 1985; 31:379.
7. Earlam R, Cunha-Melo JR. **Benign oesophageal strictures: Historical and technical aspects of dilation.** *Br J Surg* 1981; 68:829.
8. Glick ME. **Clinical course of esophageal stricture managed by bougienage.** *Dig Dis Sci* 1982; 27:884.
9. Hine KR, Hawkey CJ, Atkinson M, Holmes GKT. **Comparison of the Eder-Puestow and Celestin techniques for dilating benign oesophageal strictures,** *Gut* 1984; 25:1100.
10. Lilly J, McCaffery TD. **Esophageal strictures dilation: a new method adapted to the fiberoptic esophagoscope.** *Am J Dig Dis* 1971; 16:1137.
11. Monnier P, Hsieh V, Savary M. **Endoscopic treatment of esophageal stenosis using Savary-Gilliard bougies: technical innovation.** *Acta Endoscopica* 1985; 15:119.
12. Patterson DJ, Graham DY, Lacey Smith J et al. **Natural history benign esophageal stricture treated by dilatation.** *Gastroenterology* 1983; 85:346.
13. Rice TW. **Dilatation of peptic stricture.** In Pearson FG et al (ed): *Esophageal Surgery*, Churchill Livingstone, Edinburgh, 1995; P294-302.
14. Tulman AB, Boyce HW Jr. **Complications of esophageal dilation and guidelines for their prevention.** *Gastrointest Endosc* 1981; 27:229.

