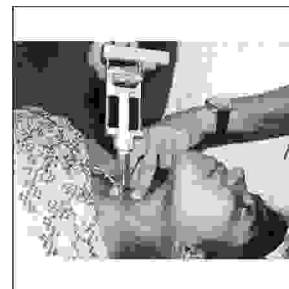


ORIGINAL

PROF-1055

FINE NEEDLE ASPIRATION CYTOLOGY; EVALUATION IN THE DIAGNOSIS OF LYMPHADENOPATHY IN CHILDREN



DR. ABDUL BARI
MBBS, DCH, MCPS, FCPS
Department of Paediatrics
Bolan Medical College Quetta

DR. AHSAL-UL-WADOOD
MBBS, M.Phil, Pathologist
Saleem Medical Complex Quetta

DR. KHAWAJA FAROOQ QASIM, MBBS, M.S
Department of Surgery
Bolan Medical College Quetta

Prof. Dr. Jamil Ahmed Mirza
Diploma America Board of Pathology (AP&CP)
Bolan Medical College Quetta

Prof. Dr. Khawaja Usman Masud,
MBBS, M.Phil

ABSTRACT... ehsanwadood@yahoo.co.in **Introduction:** Lymph nodes are frequently enlarged in children in a wide spectrum of diseases, some are of great concern while others are trivial from clinical or diagnostic point of view. **Objectives:** To evaluate the diagnostic role of fine needle aspiration cytology in lymphadenopathy in pediatric age group. **Period:** Jan 2001 to Aug 2005. **Material & Methods:** The material was obtained by FNA from children of the region, stained with H & E, Papaniculau, giemsa and Z.N Stain. History, physical examination and other pertinent clinicopathological parameters were noted before the FNA procedure. The biopsy material where available was subsequently correlated with FNA diagnosis. **Results:** A total number of 120 cases were included in the study. Out of these 64 were females and 56 were males. Out of non malignant cases the most common diagnosis in our cases was reactive lymphadenitis. **Conclusions:** Fine needle aspiration cytology is a reliable easy and economic technique of diagnosis. It should particularly be adopted in children to avoid unnecessary step of surgery and mental trauma as fairly accurate cytodiagnosis is possible especially when majority of the cases of lymphadenopathy are inflammatory in nature.

INTRODUCTION

Lymph nodes are frequently enlarged in children in a wide spectrum of diseases, some are of great concern while others are trivial from clinical or diagnostic point of

view.

In the past the assessment of the lymphadenopathy was made indirectly from the clinicopathological parameters

or biopsy, but with the resurgence of the FNA as diagnostic tool in the evaluation of lymphadenopathy, procedure of biopsy is avoided in most of the cases as FNA is fairly accurate in the diagnoses of lymphadenopathy¹.

FNA cytology remains the first line investigation in cases of lymphadenopathy. Besides initial diagnoses of lymphoma, it helps in detection of residual disease, recurrence and progression of low grade to high grade lymphoma and helps in the staging of disease. Various special ancillary techniques are now being performed on lymph node aspirates to diagnose lymphoma versus other malignancies and to decide the functional character of lymphoma and their clonal nature².

Some others works have also reported it as a technique of choice in investigating lymphadenopathy in children³. It is safe alternative excision biopsy and recommended as a first line investigation as compared to excision biopsy because it diagnosed 80% of T.B by FNA⁴.

FNAC is a well tolerated swifter to perform and report, less technically demanding. It allays anxiety and is particularly suitable in pediatric age group.

The diagnostic accuracy can be further increased if cytological findings are correlated with clinical findings and other simple investigations such as X- Rays, peripheral smear, ESR and Mantoux test. The appropriate use of FNA may obviate the need for an open biopsy.

MATERIAL AND METHODS

A total of 120 FNAs were performed during Jan,2001 to August,2005. Out of these 64 were females and 56 were males. First detail clinical history, physical examination and other clinicopathological parameters were noted. The procedure of FNA was done by two methods .

In the initial stages of the study it was done with suction by 20 ml disposable syringe with 22 to 23 gauge needle . Piston of the syringes was withdrawn up to 3ml to

create an air vacuum. Needle was rapidly moved back and forth 3-4 times to loosen up the target ,then the needle redirected to secure sample from more than one area of the lesion. Piston of the syringes was returned to normal before withdrawal. In most of the cases in the later years FNA was done only with needle without suction by syringe.

However FNA with suction was later on done only where swelling was cystic or due to abscess. After the aspiration , 5 slides were made ,3 were immediately fixed in 95% alcohol, two slides were air dried .The fixed slides were stained with H and E or pap stain .The air dried slides stained with giemsa and ZM stain . In cases , where fluid aspirated , slides were also made from the centrifuged deposit.

RESULTS

One- hundred twenty patients presenting with cervical lymphadenopathy were aspirated. Among the Non-malignant cases (51) cases showed reactive changes (44) were tuberculous (7) were of abscess and (2) cases were in -adequate.

Reactive Changes	51	(49.03%)
Tuberculosis	44	(42.3%)
Abscess	07	(6.73%)
Inadequate	02	(1.92%)

Non Hodgkin Lymphoma	05	(31.25%)
Hodgkin Lymphoma	04	(25%)
Leukemic Infiltration	03	(18.75%)
Metastatic Lymph node	02	(12.5%)
Inadequate	01	(6.25%)
False Negative	01	(6.25%)

In the malignant cases cytodiagnosis revealed (05) cases of Non-Hodgkin Lymphoma (04) Hodgkin's lymphoma (03) leukaemic infiltration and (02) Metastatic lymphnode and (1) case was in-adequate. One case was diagnosed as false negative, this was a case of leukemic infiltration wrongly interpreted as reactive lymphadenitis.

DISCUSSION

This study was carried out to evaluate the diagnostic role of fine needle aspiration in the diagnosis of lymphadenopathy in children. And also, to evaluate advantages and limitations of FNAC in this age group.

In the study a total of 120 aspirations were collected for cytological examination. 44 patients were diagnosed as tuberculous in this study, Forming the major group of patients . This proves that this infectious disease is still the major cause of lymphadenopathy in children . The diagnosis was based on the presence of epitheloid cells and Langhan's giant cells with or without caseation necrosis. In all positive cases cytological smears were stained for Acid Fast Bacilli, only 4% cases proved positive. Granulomate and necrosis are the most common elements found in our cases . Although granulomatous response is seen in a wide variety of infectious agents and non infectious process both benign and malignant⁵. However as tuberculosis is so common in our country every clinically relevant case of granulomatous lymphadenitis should be considered as tuberculous lymphadenitis unless proved otherwise . FNA is a reliable tool of diagnoses in cases of tuberculous lymphadenitis.

Correct diagnosis in 83% has been achieved cases by FNA in children⁶ .

Out of malignant lesions were metastatic carcinoma , the primary was nasopharyngeal carcinoma in one case and papillary carcinoma in other case .These were confirmed later on, on histopathology. Three cases diagnosed on histology as Hodgkin's lymphoma is not difficult when the aspirated smears show polymorphic cell population comprising lymphocytes, Plasma cells, histiocytes,

neutrophils and eosinophils with definite presence of Reed -Sternberg cells. FNAB is use full both for establishing a primary diagnosis and confirming recurrence in Hodgkin's disease. Therapy can be initiated negating the need for formal tissue biopsy⁷. The diagnosis of nodular sclerosis subtype of Hodgkin's disease is not possible as nodular pattern and fibrosis are appreciated only on histology. Five cases of non Hodgkin's lymphoma were diagnosed both on cytology and histology, which correlates well with the studies of other workers^{8,9}.

Surgical biopsy can be avoided if one uses the combined approach of fine needle aspiration cytology, cytomorphology and flow cytometry. It will help the pathologist to distinguish and diagnose metastating and lymphoproliferative disease. This approach would be of use particularly in differentiating benign reactive lymph node hyperplasia from lymphoma which comprises the bulk of lymph node biopsies¹¹ .

In the beginning when we started FNA in Quetta, the percentage of false negative was high , however with the passage of time as we gained experience this percentage decreased. In adequate smears were improved partly by getting more expertise and partly by repeating the procedure and doing FNA from multiple lymph nodes where available and because it was observed in some cases that cervical lymph nodes are most representative of the disease rather than axillary lymph node.

The false positive cases were absent in our study , which might be a reason of our high false negative in early stages of our experience.

Regarding the technical aspects although we started FNA with 22 gauge needle but later got satisfactory material with 23 gauge needle obviously causing less trauma to the patients .

Considering the results of our study , we are of the view that every case of lymphadenopathy should have FNAC

before going for surgical procedure.

CONCLUSION

It is concluded from this study that FNAC is a simple, safe, virtually painless and reliable method for obtaining cytologic material from the lymph nodes in inflammatory and neoplastic diseases. It provides good results even if performed unassisted by an imaging modality. It offers low cost, better diagnostic yield and a much-reduced risk of major complication. It should particularly be adopted in the evaluation of lymphadenopathy in pediatric age group. The appropriate use of FNA may obviate the need for an open biopsy.

REFERENCES

1. Chu E.W., Hoyer R.C. **The clinician and the cytopathologist evaluate fine needle aspiration cytology.** Acta cytologica.,1473; 21:413-17.
2. Dilip K. Das - **value and limitations of fine needle aspiration cytology in diagnosis and classification lymphoma- Diagn. Cytopathol.**1992; 21:240-249)
3. AMO Shonabi, O Akiode, BA Salamital. **A preliminary report in superficially accessible lesion in children,** vol 23.(3) 2004:221-223.
4. Ajmal Farooq, Imran Ameen. **Comparison of FNAC vs excision biopsy for suspected tuberculous cervical lymphadenopathy.** Annals King Edward med coll Sep 2003; 9(3):216-8).
5. Durt R. **Fine-needle aspiration cytology in a case with features of chronic granulomatous disease.** Diagn. Cytopathol, 1991;7:57-57.
6. Mohammad Hussain Nadeem Rizvi-**clinical and morphological evaluation of tuberculous peripheral lymphadenopathy-** J Coll physicians Surg Pak Dec,200313(12):694-6).
7. Moreland WS, Geisinger KR **Diagn Cytopathol.** 2002 May,26(5):278-82).
8. Gupta S.K Dutta T.K and Aikat M. et al. **Evaluation of fine needle aspiration biopsy technique in the diagnosis of tumour,** Indian j.Cancer,1975;12;257-67.
9. Carter T.R.,Feldman P.S and Innes D.J.et al. **The role of fine needle aspiration cytology in the diagnosis of lymphoma.** Acta. Cytologica.,1988;32:848-53.
10. Gupta S.K Chugh T.D., Sheikh Z.A, Al -Rubah N.A.R. **Cytodiagnosis of tuberculous lymphadenitis : A Correlative study with microbiologic examination.** Acta. Cytol.,1993;37:329-32.
11. Khattak MF, Nam MH, Saleem M, dawood MM, Ahmed M, malik A. **Diagnosis of lymphoproliferative disorder :A review of fine needle aspiration cytology and flow cytometry.** Pakistan journal of pathology. vol 5(1) 75-83)1994 Jan-June..