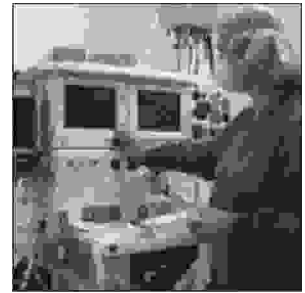

ORIGINAL

PROF-1051

COMPUTERIZED AXIAL TOMOGRAPHY; SEDATION VERSUS GENERAL ANAESTHESIA IN CHILDREN BELOW FIVE YEARS OF AGE



DR. AMRAN HAFIZ
FCPS (Anaesthesiology)
Department of Anaesthesiology
Combined Military Hospital Rawalpindi

DR. NAVEED MASOOD
FCPS (Anaesthesiology)
Department of Anaesthesiology
Combined Military Hospital Rawalpindi

DR. FAYYAZ HUSSAIN
FCPS (Anaesthesiology)
Department of Anaesthesiology
Combined Military Hospital Rawalpindi

Department of Radiology
Combined Military Hospital Rawalpindi

ABSTRACT... ranhafiz30@hotmail.com **Objectives:** to evaluate the clinical safety, effectiveness, efficacy and potential side effects of sedation in pediatric patients undergoing computerized tomography by intrarectal thiopentone and to compare this technique with general anaesthesia for computerized tomography in paediatric patients. **Study Design:** Interventional and analytical / comparative study. **Place and duration of study:** The study was carried out in Radiology department Combined Military Hospital Rawalpindi over a period of 1 year from Jan 2003 to Jan 2004. **Material and Methods:** Sixty children below 5 years of age were selected by nonprobability convenience sampling and divided into 2 groups A and B, each comprising of 30 children. Group A was sedated by thiopentone sodium that was administered rectally and group B received general anaesthesia with a uniform technique. **Results:** in group A quality of sedation was judged to be adequate in 26 out of 30 patients (86.6%). Another 2 were sedated but required mild restraint like reposition of the neck leaving 2 with inadequate sedation or an overall failure rate of 6.66%. In group B the success rate was 100% with no observation of any complication. **Conclusion:** rectally administered thiopental is a safe and effective sedative for paediatric patients requiring CT scanning in the presence of anaesthesiologist and the failure rate is very low. General anaesthesia makes CT scan more successful with minimal adverse events.

Key words: Children, Computerized Axial Tomography, General Anaesthesia, Sedation.

INTRODUCTION

Administration of general anaesthetics to children outside the operating room is one of the challenging aspects of clinical care. Increasingly, anaesthesiologists are abandoning their familiar environs and venturing into

other areas of the hospital. Each area has some unique anaesthetic considerations.

Computerized axial tomography and magnetic resonance imaging are diagnostic radiological procedures which are

easily performed in conscious, cooperative adults and older children but this is not the case in small children especially under five years of age. As movement interferes with effective computerized axial tomography and magnetic resonance imaging a challenging problem is provided by the patients who are unable to lay still. General anaesthesia undoubtedly allows magnetic resonance imaging and computerized axial tomography to be carried out in anxious children, but sedation is sometimes seen as an acceptable alternative.

Conscious sedation is impractical in a noisy environment and deep sedation is necessary^{1,2, 3}. Deep sedation involves a bolus of an oral, intravenous or rectal hypnotic, which may need to be topped up with an intravenous tranquilizer or opioid. Commonly used sedatives are chloral hydrate, midazolam, pethidine, pentazocine and thiopentone. During the scan the child is largely hidden and out of reach, often with depressed ventilation and impaired airway reflexes and without any airway maintenance device in place, a situation in which most anaesthesiologist would feel uncomfortable. The potential complications of deep sedation include hypoventilation, apnoea, air way obstruction, aspiration, hypotension, bradycardia and increased intracranial pressure. Sedation is less predictable and it is expected that there is a failure rate of 5-15%⁴⁻⁶. It has also been suggested that there are varying levels of deep sedation at the end of which there is an overlap with general anaesthesia⁶. In contrast to this, general anaesthesia starts with a rapid intravenous or gaseous induction followed by some method of securing the air-way. It is maintained for as long as necessary by using some combination of gases, volatile agents or intravenous drugs. Unlike sedation deepening the level of consciousness or dealing with respiratory depression or apnoea is simple, almost immediate and non disruptive to the scan. To choose sedation or general anaesthesia for children undergoing computerized axial tomography and magnetic resonance imaging is controversial.

MATERIALS AND METHODS

This interventional and analytical/comparative study was carried out in CMH Rawalpindi radiology department.⁶⁰

children under 5 years of age were selected by non probability convenient sampling and divided into two groups A and B each comprising of 30 children.

Group A was adequately sedated by thiopentone sodium which was administered rectally (table-I). Patients were accompanied by anaesthesiologist throughout the procedure and were monitored by pulse-oxymeters and cardiac monitors. 10% thiopentone was administered rectally with the help of a syringe and a cut off 8 french feeding tube. Group B received general anaesthesia with a uniform technique including inhalation induction with halothane, injection succinylecholine (1mg / kg) for relaxation. Once relaxed endo tracheal tube was passed and secured. General Anaesthesia was maintained with 50% oxygen, 50% nitrous and halothane by Jackson –Rees modification of Ayer's T-piece circuit. IPPV was continued till the patient started spontaneous breathing. As the procedure was completed patients were given 100% oxygen and were extubated as the airway reflexes returned. The following observations were made.

GROUP A

1. Time from the administration of intrarectal thiopentone to the onset of adequate sedation.
2. Adequacy of sedation was gauged by the onset of sleep, no response to verbal command and cessation of movements.
3. The time of termination of the sedation was also noted and also the total time elapsed between the onset of sedation and the termination of sedation.
4. The termination or the end point was considered when the child fulfilled the discharge criteria.(table-II)
5. Oxygen saturation was continuously monitored and the following observations were noted in this regard.
 - a. No. of patients in whom oxygen saturation fell below 90%
 - b. No. of patients in whom the fall in O₂ saturation below 90% responded to the following minor maneuvers.

- * Repositioning of the jaw to open the upper airway
 - * Oxygen supplementation via nasal canulae.
6. Sedation technique was considered a failure when the child kept on moving or crying that made the procedure impossible to carry out or if there was a fall in O₂ saturation even with above maneuvers.
 7. In the failure of sedation technique general anaesthesia was given.

GROUP B

1. The time from the start of inhalation of anaesthetic agent to the time when spontaneous ventilation returned.
2. The time of recovery was also noted down and the total time elapsed between inducing the patient and recovery was calculated. The end point of general anaesthesia was considered when the child fulfilled the discharge criteria (table-II).

Any complication during general anaesthesia was noted down like arrhythmias, bronchospasm, hypoventilation and laryngospasm.

The data design in the study is presented in tabular and graphic forms. A Performa was filled in for each child, the sample of which is presented in Annex I.

Values are expressed as mean +/- SD .Proportion are represented as numbers and percentages. Statistical analysis is done using paired T test and p values are calculated from two tailed probability pair of the t distribution table.

INCLUSION CRITERIA

1. Patients whom parents gave informed consent.
2. Children (male and female) up to 5 years of age undergoing computerized axial tomography.
3. Conscious children.

EXCLUSION CRITERIA

1. Potential air way obstruction (e.g. sleep apnoea)⁷, Respiratory centre abnormalities (e.g. brain stem tumor)⁷. Respiratory centre desensitization to CO₂ (e.g. chronically raised PaCO₂.)
2. Renal and hepatic dysfunctions leading to altered drug kinetics.
3. Condition, in which increased PaCO₂ would be detrimental, e.g. raised I.C.P.
4. Condition with high risk of pulmonary aspiration of gastric contents.
5. History of acute intermittent porphyrias.
6. Neoplastic lesion, inflammation, ulceration or bleeding of the lower bowel.

RESULTS

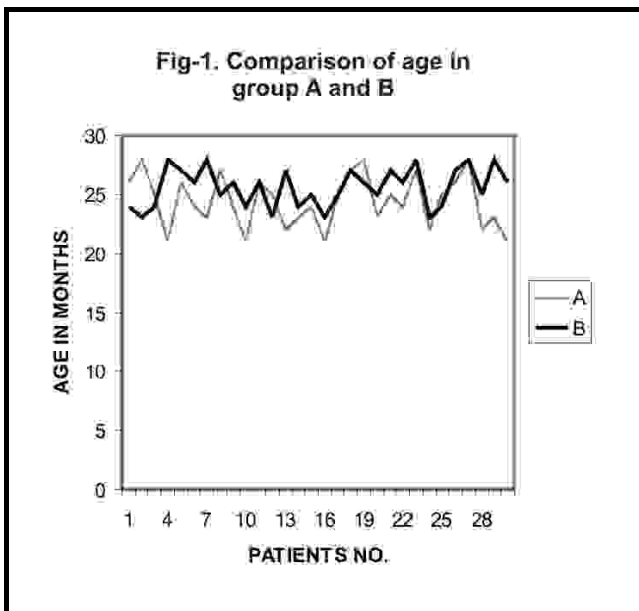
Total of 62 patients were enrolled in the study. Out of these 2 patients were excluded from the data analysis because they expelled the drug.30 patients were randomly assigned group A and B. Group A being the sedation arm while group B the general anaesthesia arm. Mean age (Fig-1) of group A was 24.4 months with a standard deviation 2.22 and standard error mean 0.40 while that of group B mean age was 25.6 months , standard deviation 1.67 and standard error mean 0.30 (p > 0.1).

The mean time (Fig-2) for the onset of adequate sedation to carry out CT scan in group A was 15.63 minutes. The standard deviation was 1.40 and the standard error mean was 0.40 The mean time for the preparation of patients by general Anaesthesia in group B was 7.3 minutes with standard deviation of 1.31 minutes and standard error 0.24 (p < 0.05).

The mean time for recovery (Figure3) in Group A was 84 minutes with standard deviation of 2.50 and standard error of mean 0.45 .The mean time for recovery in group B was 40.5 minutes. The standard deviation of 2.3 & standard error mean 0.43 (p<0.05).

A.	In infants below 6 months of age	50 mg/kg
B.	In infants b/w 6 and 12 months of age	35 mg/kg
C.	In infants b/w 12 months to 5 years of age	25 mg/kg

Infants	
•	Baseline vital signs and mental status
•	Active, able to sit upright or crawl appropriate for age
•	Recognizes, interacts with, or is consolable by parent/caregiver
•	Responsible parent or guardian present
Children	
•	Baseline vital signs and mental status
•	Able to follow command and verbalize appropriately
•	Demonstrates motor function appropriate for age
•	Able to take popsicle or liquids
•	Responsible parent or guardian present



In group A quality of sedation was judged to be fully adequate (Fig 4) in 26(86.66%) out of 30 patients. In 2 patients (6.66%) sedation was adequate but with mild

restraint, they had brief oxygen de-saturation that responded to repositioning. Total of 4 (13.3%) patients (Group A) had some side effects (Fig 5) out of these 2(6.66%) had minor side effects, (hiccups and hyper salivation) that required no intervention) and 2(6.66%) patients as described above had brief oxygen de-saturation that responded to reposition and oxygen supplementation. In 2 patients (6.66%) sedation was inadequate (total failure) and general anaesthesia was given (Fig 6). In group B quality of CT scan was obtained in all 30 (100%) patients with no incidence of any complications (Fig 6).

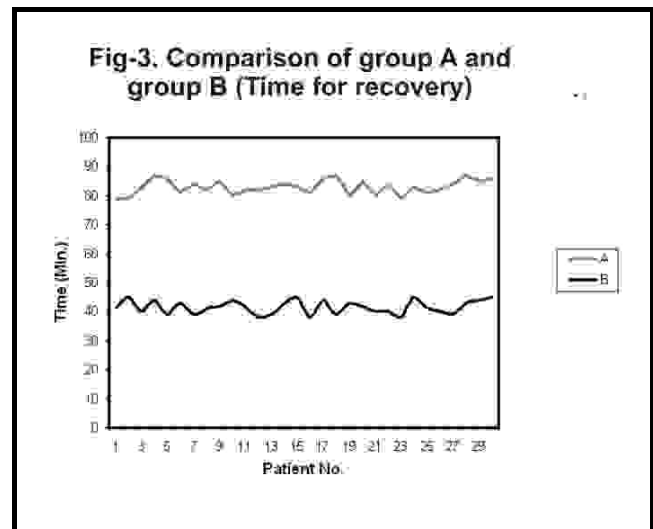
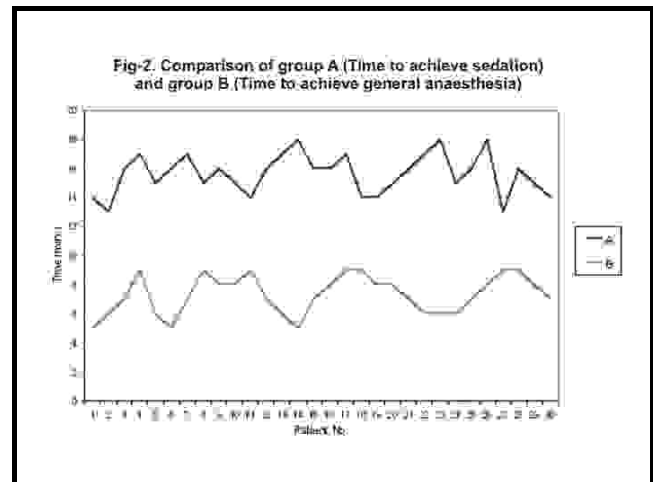


Fig-4. Adequacy of sedation in group A

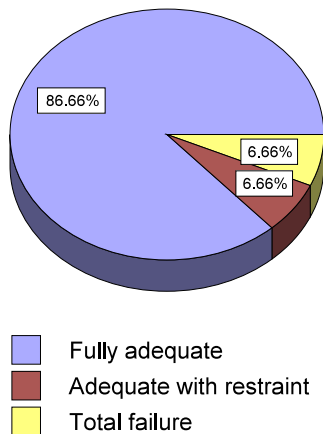
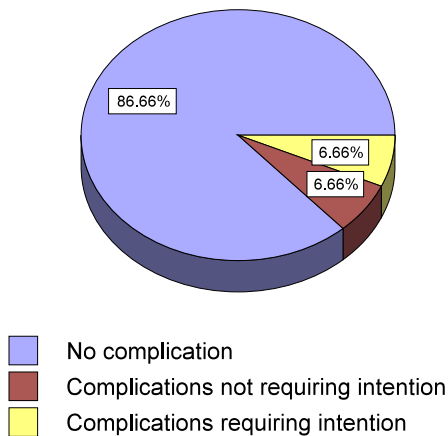
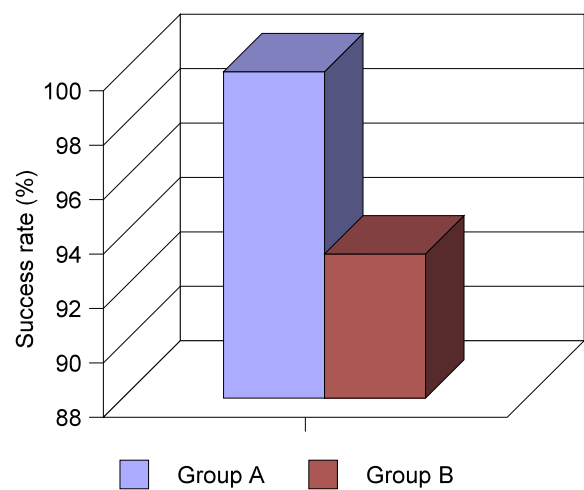


Fig-5. Complications in group A



or anxiety provoking procedure should be considered a candidate for PSA,⁸ which has two general benefits. First, it enables the child to tolerate the procedure by eliminating pain, discomfort, and anxiety second; it expedites imaging studies and other noninvasive procedures that require the patient to be motionless.⁹ In some cases, PSA has the added benefit of diminishing the patient's memory of the procedure.

Fig-6. Comparison of success rate in



Although computed tomography (CT) scanning is a painless procedure, it often requires sedation in small children who are usually frightened and will rarely lie motionless otherwise. Although some of these patients need intravenous access for various reasons, many are stable and could safely undergo the procedure without subjecting them to the added trauma of starting an intravenous line. Unfortunately, the sedatives available for use via other routes have serious drawbacks. There is no one standard therapy. The most common agents include chloral hydrate,¹⁰⁻¹² which has a variable duration sometimes lasting as long as several hours; intranasal or oral midazolam, which rarely renders the patient motionless enough for CT scanning; and intramuscular ketamine, which requires an injection and often causes bizarre random movements or twitching.

DISCUSSION

These days a growing number of physicians have started using procedural sedation and analgesia to help children to tolerate unpleasant therapeutic and diagnostic procedures. Over the last five years, the use of pharmacologic agents to manage the pain and anxiety associated with therapeutic and diagnostic procedures in children, referred to as procedural sedation and analgesia (PSA), has become standard practice in many medical centers, emergency departments, and ambulatory care settings. Any child undergoing a painful

The most frequently used barbiturates for PSA are pentobarbital (Nembutal), thiopental (Pentothal), and methohexetal. Pentobarbital is most commonly used when performing diagnostic imaging studies in children over 3 years of age. It can be administered orally, rectally intramuscularly, and intravenously. The IV route has the fastest effect, producing sedation within three to five minutes; duration of action is 15 to 45 minutes. Thiopental and methohexetal are ultra short acting barbiturates that have been safely used by the rectal route for diagnostic imaging studies.^{13,15} Methohexetal has less of a respiratory depressant and hypotensive effect than thiopental.

There is substantial experience¹⁶ using rectal thiopentone for pre-induction of anaesthesia in paediatric surgical patients, yet its use via this route for paediatric outpatient procedures has not been well described. Therefore, the aim of our study was to test the hypothesis that rectally administered thiopentone is a safe and effective sedative with sufficiently brief duration to make it the desired medication to use for rendering stable paediatric emergency department patients, motionless for CT scanning.

Two patients who were enrolled early in the study had to be excluded because they expelled the drug shortly after administration. Our experience with these patients led us to later hold our patients' buttocks together for a few minutes after administration of rectal thiopentone as is often done with other rectal medications including acetaminophen.

In 1993, Manulli and Davies¹² compared rectal Methohexetal to chloral hydrate in a retrospective chart review and found Methohexetal to be better suited to outpatient use. Finally, in their 1995 retrospective study, Bowers et al¹⁷ favorably evaluated the use of rectal barbiturate in 26 paediatric emergency department patients. Their patients, however, were undergoing painful procedures, and we believed that a situation such as CT scanning, calling for pure sedation rather than analgesia might be a more suitable use of rectal thiopental. We believe this report is the first prospective

study of paediatric emergency department patients sedated with rectal thiopental for nonpainful procedures.

Our 95% success rate is comparable to that of Glasier et al,¹⁸ who studied fasted and sleep-deprived children undergoing elective imaging and sedated with rectal pentothal. Their onset of sedation was slightly longer (12.2 minutes), but duration of sedation was very similar at 71.1 minutes. Elaine S Pomeranz¹⁹ also studied rectal methohexetal for CT imaging of paediatric patients with comparable success rate. His onset of actions was shorter but duration of action is similar that is 79 minutes.

Alp H⁵¹ evaluated the clinical safety, effectiveness, efficiency and potential side effects of rectally administered thiopentone sodium in children undergoing CT and MRI. Successful sedation and adequate imaging were obtained in 96.5% of patients. In 10% of patient's oxygen saturation transiently fall below 90% .The onset of sedation was after 15 min. of administration of drug. This concurs with our study.

Ten of our patients had some side effects of sedation (Table-III), all related to their airway. Hyper salivation, hiccups, cough, and oxygen de-saturation attributable to upper airway occlusion are not unique to rectal Methohexetal also, and in fact, are nonspecific effects occurring with any sedation that produces a somnolent state. All the patients with oxygen de-saturation (n=6) responded to head repositioning, although some also were briefly given supplemental oxygen with nasal cannula.

To decide between sedation and anaesthesia it will be helpful to compare how they meet the requirements for scanning. General Anaesthesia produces an immobile patient who will stay unconscious until the end of the procedure. Sedation is less predictable and it is accepted that there is a failure rate between 5% and 15%.⁴⁻⁶The induction of anaesthesia is relatively quick but sedation has a longer and more variable onset and offset⁵ during which the child must be observed. Sedation is often viewed as less dangerous than general anaesthesia. A comparison between sedation and

anaesthesia for upper gastrointestinal endoscopies in children showed a higher incidence of desaturation and arrhythmias in the sedation group. As well as Coté et al's collection of sedation disasters,²¹ there are many other reports of serious incidents,²²⁻²⁴ one mentioning nine deaths and 18 episodes of respiratory arrest occurring during sedations carried out by 129 radiologists.

Characteristics	Group A	Group B
No. of children	30	30
Technique applied	Sedation	General Anaesthesia
Mean age (months)	24.4	25.6
Mean time to sleep (min)	15.63	7.3
Mean time for recovery (min)	83	41.53
No. of patients with complications	4	0
Success rate (%)	93.3	100
Failure rate (%)	6.66	0

There has been much debate over appropriate drugs and their dosage, and those who sedate children will have their favorite regimens. It is important that the person administering the drugs is familiar with them, and that cocktails of more than two drugs are to be avoided because of the unpredictability of drug interactions and the increased incidence of important side effects. Minimum doses should be used to achieve the necessary level of sedation and yet it is preferable to give a reasonable bolus of drug rather than attempting to titrate the dose by small repeated increments over a prolonged period.

CONCLUSION

Sedation instead of general anaesthesia can ease the stress of many invasive and diagnostic procedures. But we should not underestimate the risks. By being aware of possible complications, knowing how to respond, we can protect our patients from problems and ensure a

smooth recovery. Our study concludes that rectally administered thiopental is a safe and effective sedative for paediatric patients requiring CT scanning in the presence of anaesthesiologist. Sedation practice involves pre-sedation assessment and optimal selection of patients, careful monitoring and support from dedicated staff, and adherence to recovery and discharge criteria. General anaesthesia definitely makes CT scan more successful with minimal adverse events. More studies are required regarding safety of sedation in our setup.

REFERENCES

- Maxwell LG, Yaster M. **The myth of conscious sedation.** Arch Paediatr Adolesc Med 1996;150:665-667.
- Sury MRJ, Hatch DJ, Deeley T, Dicks-Mireaux C, Chong WK. **Development of a nurse-led sedation service for paediatric magnetic resonance imaging.** Lancet 1999; 353:1667-1671.
- The Royal College of Anaesthetist and The Royal College of Radiologists. Sedation and anaesthesia in radiology.** Report of a joint working party;1992.
- Malviya S, Voepel-Lewis T, Tait AR. **Adverse events and risk factors associated with the sedation of children by nonanaesthesiologists (Abstract).** Anesth Analg 1997; 85:1207-1213.
- Squires RH, Morriss F, Schluterman S, Drews B, Galyen L, Brown KO. **Efficacy, safety, and cost of intravenous sedation versus general anaesthesia in children undergoing endoscopic procedures.** Gastrointest Endosc 1995; 41:99-104.
- Hollman GA, Elderbrook MK, Van Den Lagenberg B. **Results of a pediatric sedation program on head MRI scan success rates and procedure duration times.** Clin Pediatr 1995; 34:300-305.
- Shepherd JK, Hall-Craggs MA, Finn JP, Bingham RM. **Sedation in Children scanned with high field magnetic resonance: the experience at the Hospital for Sick Children, Great Ormond street.** Br J Radiol 1990;63:794-797.
- Sacchetti A, Schafermeyer R, Geradi M, et al. **Pediatric analgesia and sedation.** Ann Emerg Med 1994; 23:237.

9. American Society of Anaesthesiologists Task Force on Sedation and Analgesia by Non-Anaesthesiologists. **Practice guidelines for sedation and analgesia by non-anaesthesiologists.** *Anaesthesiology* 1996; 84:459.
10. Binder LS, Leake LA. **Chloral hydrate for emergent pediatric procedural sedation: a new look at an old drug.** *Am J Emerg Med* 1991; 9:530-534.
11. Pereira JK, Burrows PE, Richards HM, Chuang SH, Babyn PS. **Comparison of sedation regimens for pediatric outpatient CT.** *Pediatr Radiol* 1993;23:341-344.
12. Manulli MA, Davies L. **Rectal methohexital for sedation of children during imaging procedures.** *AJR Am J Roentgenol* 1993; 160:577-580.
13. Rockoff MA, Goudsouzian NG. **Seizures induced by methohexital.** *Anaesthesiology* 1981; 54:333-335.
14. Allen EM, Male CG. **Methohexital is not contraindicated in epileptics (letter).** *Anesthesiology* 1982; 56:240-241.
15. Orallo MO, Eather KF. **Sodium methohexital as a rectal agent in paediatric anesthesia.** *Anesth Analg* 1965; 1:97-103.
16. Audenaert SM, Montgomery CL, Thompson DE, Sutherland J. **A prospective study of rectal methohexital: efficacy and side effects in 648 cases.** *Anesth Analg* 1965; 81:957-961.
17. Bowers RM, Gossett CW, Hobbs D. **Rectally administered methohexital for pediatric sedation in the emergency department (Abstract).** *Acad Emerg Med* 1995; 5:428.
18. Glasier CM, Stark JE, Brown R, James CA, Allison JW. **Rectal thiopental sodium for sedation of paediatric patients undergoing MRI and other imaging studies.** *AJNR Am J Neuroradiol* 1995; 16:111-114.
19. Elaine S. **Rectal Methohexital Sedation for Computed Tomography Imaging of Stable Paediatric Emergency Department.** *Paediatrics* Apr 2000.
20. Guler I,Orbak Z,Kara Kelleoglu C,Tan H. **Efficacy and safety of rectal thiopental: sedation for children undergoing computed tomography and magnetic resonance imaging.***Paediatr Int* 1999;41(5):538-41.
21. Coté CJ, Alderfer RJ, Notterman DA, Fanta KB. **Sedation disasters: adverse drug reports in pediatrics [abstract].** *Anesthesiology* 1995; 83:A1183.
22. Nahata MC, Clotz MA, Krogg EA. **Adverse effects of meperidine, promethazine, and chlorpromazine for sedation in paediatric patients.** *Clin Paediatr* 1985; 24:558-560.
23. D'Agostino J, Terndrup TE. **Comparative review of the adverse effects of sedatives used in children undergoing outpatient procedures.** *Drug Saf* 1996; 14:146-157.
24. Graft KJ, Kennedy RM, and Jaffe DM. **Conscious sedation for pediatric orthopaedic emergencies.** *Pediatr Emerg Care* 1996; 12:31-35.