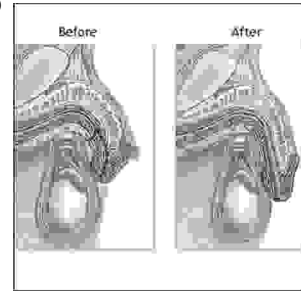


ORIGINAL

PROF-1305

HYPOSPADIAS REPAIR



DR. MUMTAZ RASOOL, FCPS

Senior Registrar, Urology,
Bahawal Victoria Hospital, Bahawalpur.

DR ABID HAMEED SHEIKH, MS

Assistant Professor, Paediatric Surgery,
Quaid-e-Azam Medical College, Bahawalpur.

DR. SHAFQAT ALI TABASSUM, FCPS

Associate Professor of Urology,
Quaid-e-Azam Medical College, Bahawalpur.

Dr. Mohammad Mughis Amin, FCPS

Assistant Professor & Head of Plastic Surgery,
Quaid-e-Azam Medical College, Bahawalpur.

ABSTRACT... Place of Study: The Departments of Urology, Paediatric Surgery and Plastic Surgery, Quaid-e-Azam Medical College, Bahawal Victoria Hospital, Bahawalpur. **Duration of Study:** Jan 1999 to Dec 2004. **Design of Study:** Prospective. **Materials&Methods:** Patients admitted with hypospadias in these departments were included in this study except patients with multiple failed repairs previously. Standard procedures were practiced for every type of defect i.e. MAGPI and Mathieu's repair for coronal hypospadias, Snodgrass urethroplasty for proximal and distal penile hypospadias. **Results:** The age range observed during this study was 1.5 to 25 years while 64% of patients were less than 10 years of age. The type of defect was coronal in 25%, penile in 60%, penoscrotal and perineal in 15% of the patients. Initial success rate was 78% and overall success rate was 92%. Complications observed were fistula formation 7% , stenosis of anastomotic site 7% and dehiscence of repair 3%. **Conclusion:** Thorough evaluation of urethral and penile malformation brings best outcome of surgery for hypospadias. Hypospadias repair should be offered to the child before school going age so as to prevent psychological impacts of genital malformations.

Key words: Hypospadias, Coronal, Penoscrotal, Urethroplasty.

INTRODUCTION

Hypospadias is the abnormal opening of external urethral meatus in male child at birth, and can be any where along the ventral side of shaft of the penis or perineum. The more proximal the meatus more likely chances of development of ventral curvature of penis (chordae)¹. It is therefore unsurprising that normal aesthetic appearance after hypospadias surgery is essential for satisfactory sexual act and urinary function.

Basic aim of hypospadias surgery is the correction of chordae, reconstruction of urethra and sufficient ventral penile skin coverage with minimal complication. Hypospadias surgery is one of the most challenging surgical interventions that still need further refinements for increased success rate².

Incidence and associated anomalies

The incidence of hypospadias has been calculated as 1:300 live male births³. The most common anomalies

associated with hypospadias are undescended testis and inguinal hernia⁴.

Surgical Goals

The surgical goal in patients with hypospadias is to construct a straight penis with meatus as close as possible to normal site to allow a forward directed stream and normal coitus. It is the inalienable right of every boy to be pointer instead of a sitter by the time he starts school and to write his name legibly in the snow.

History of surgical methods

There have probably been over 200 reported original methods of urethral reconstruction and they continue as modifications of modifications.

The first account of hypospadias surgery was written by Heliodorus and Antyllus (100 to 200 AD) which consisted of amputation of shaft distal to the existing meatus. Mettauer 1842 suggested multiple incisions for liberation of chordae while Bouisson 1861 suggested transverse incision at greatest curvature. The transverse incision was added by central flap tube covered with penile flaps by Duplay 1874. This technique later modified by Denis Browne in 1950 and by Marberge 1981. Scrotal tissue to obtain skin coverage and burying penis was used⁵.

Multistage repair consisted of chordae release first and ventral cover by dorsal skin flaps were also introduced. Denis Brown 1953 promoted buried strip principle of hypospadias repair. A ventral strip of skins was covered by mobilized skin flaps brought in midline with beeds and stops. The channel epithelialized around a stenting catheter left in place for 3-6 weeks. Vander Meulen 1964 modified unsatisfactory results of Denis Brown with the help of rotated dorsal skin flaps with accentric suture line. He allowed patient to void through the repair with dramatic "fistula Less" results. Later on double breasting of skin flaps was introduced by Durham Smith 1973 after Byars 1955. One stage repair of hypospadias became popular after success in removing chordae tissue completely. Urethral tube first constructed by Russel 1950, later in 1961 Broadbent modified the method. In 1954 Mc Cormack reported full thickness tube graft

urethroplasty, as first procedure and proximal anastomosis later. This technique converted to single step procedure by Devine and Horton 1955, Hodgson 1975 described vascularized tube grafts.

One stage hypospadias repair has withstood test of time which allows completion of reconstruction in one stage, allowing use of healthy unscarred skin. Main impediment to the success of one stage repair was inadequate chordae release which has nearly been eliminated by introduction of artificial erection technique introduced by Giffes and Mc Loughlin in 1974⁶.

Present study

This study was conducted at the Departments of Urology, Paediatric Surgery and Plastic Surgery, Bahawal Victoria Hospital / Quaid-e-Azam Medical College, Bahawalpur. This prospective study was purposed to evaluate outcome of repair for hypospadias in patients presenting for this congenital anomaly. For any type of hypospadias with or without chordae, standardized procedures were performed and results were observed. Post operative patients were discharged on 10th – 14th day. Follow up was initially fortnightly and then at 3 monthly intervals. Minimum follow up period was 18 months and maximum 36 months for these particular study patients, when results were formulated. Period of study = July 99 to December 2004

Total number of cases = 100

Age: Age of the patients in this study was 1.5 years to 25 years.		
Age	No of pts	%age
1.5-10 year	64	64%
11-20 year	26	26%
21-25 year	10	10%

Aim of any type of repair is a seven step operative technique for one stage hypospadias repair, as follows;

1. Outlining the skin incision and flap mobilization
2. Artificial erection, harvesting parametatal foreskin.
3. Glans splitting and wing creation.
4. One stage urethroplasty with parametatal foreskin flap
5. Meatal glanuloplasty.
6. Creation of Byar's flaps of skin.
7. Skin closure.

Type of Hypospadias was as follows		
Type of defect	No of pts	%age
Coronal	25	25%
Distal penile	40	40%
Proximal penile	20	20%
Penoscrotal	10	10%
Perineal	05	05%

Procedures performed for these types of Hypospadias, noted in our study were as follows;	
Type	Name of procedure
Coronal	MAGPI/Matheu's
Distal penile	Snoddgras with double breasting of skin flaps
Proximal penile	Two stage i. Chordae release ii. Snoddgras & double breasting of skin flaps
Penoscrotal & perineal	Three stage repair i. Chordae release ii. Original opening left open for urinary diversion and distal tube formed by Snoddgras & double breasting of skin flap technique. iii. Closure of srotal fistula after 06 months

Results obtained were as follows			
Type	Results		Total
	Good	with complication	
Coronal	22	3	25
Distal penile	34	6	40
Proximal penile	16	4	20
Penoscrotal & perineal	11	4	15

COMPLICATIONS

Immediate post operative complications were hematoma formation, skin discoloration, wound infection and repair disruption. Fistula formation, stenosis of meatus and anastomotic site and complete tube stenosis were late complications noted in our study

Type of defect	Complication			%age
	Complete dehiscence	Fistula	Stenosis	
Coronal	-	-	3	12%
Distal penile	-	3	3	15%
Proximal penile	1	2	1	20%
Penoscrotal & perineal	2	2	-	27%

Secondary procedures were required in complete disruption of repair, 03 months time lapse was observed before 2nd repair was done. In fistula formation excellent results were observed after secondary procedure with a time lapse of almost 03 – 06 months. In stenosis, majority patients settled with regular, gentle Bougie dilatations.

DISCUSSION

Hypospadias repair must be accomplished by the time; boy reaches school or may be by the age of 02 years. The awareness of possible psychogenic impact of genital

malformations in childhood recommends an early correction of hypospadias, if possible in first year of life⁷. The age at which patients presented to us was between 1 ½ yr to 25 years. Studies conducted internationally has got age range between 06 months and 26 years⁸⁻¹³. The age factor neither effects the selection of separative procedure nor the outcome. Although as the child grows older the impact of genital malformations effects the social behavior and self esteem¹⁴.

A thorough evaluation of both urethral and penile malformations is mandatory for the choice of best surgical treatment in patients with hypospadias. The site and size of urethral meatus, presence of chordae and velamentous distal urethra must be carefully assessed. In distal (glanular or coronal) hypospadias the meatal advancement with glanuloplasty is the treatment of choice. In proximal hypospadias with chordae the transverse preputial flap according to Duckett's technique allows one stage hypospadias repair⁷. As is the case in every congenital tubular malformation urethral congenital malformation like hypospadias can occur in the entire length of anterior urethra i.e. in the fusion process of urethral folds from the glands coronal region up to Penoscrotal region. The commonest site being the distal penile and coronal areas where during development glanular folds and urethral folds unite to form a single continuous channel. In this particular study the site of native meatus in patients with hypospadias was coronal 25%, distal penile 40%, proximal penile 20%, Penoscrotal 10%, perineal 5%. The meatal position noted in different studies was, glanular in 13% to 83% patients, mid shaft in 16% to 60%, proximal penile or penoscrotal 8.5% to 40.7% and perineal in up to 5% of the patients^{8,9,15,16,17,18}. Congenital malformation ratio is not significantly varied between races or countries as is apparent with the comparison of statistics in this study and literature available in international journals.

The type of repair used is mostly preference of individual surgeon and its failure rate. That is why more than 200 procedures are known for hypospadias repair. It means that no single procedure is 100% successful, universally acceptable and suitable to all surgeons. The two stage

procedures initially started are now left with plastic surgeons who usually have broader interest than Urologists or Pediatric surgeons^{16,17,18}.

Mostly one stage repair procedure is preferred now a days. This technique has created success rate of over 91%¹⁹. The current concept of understanding chordae and emphasis upon preserving urethral plate have brought hypospadias surgery over the last decade near it's ultimate goal of a reconstructed penis that is functionally and cosmetically normal⁸. In 1994, Warren Snodgrass primarily reported successful preservation of urethral plate, called tabularized incised plate urethroplasty. For the complete chordae release i.e. fibrous tethering bend dorsally associated with hypospadias anomaly, requires intra operative artificial erection which is usually achieved with intra corporal saline injection after applying a tourniquet at penile base. A new trial of a pharmacological erection, induced by 14 microgram alprostadil intra cavernously achieves erection within one minute with 84% excellent results¹⁹. Pharmacological erection involves whole penis while artificial erection with saline leaves base below tourniquet flaccid. Pharmacological erection is effective and reliable with no significant complications. Saline injected artificial erection should be performed with moderate force since over filling is unphysiological and may falsely induce chordae^{16,17,19}.

In our study only physiological saline was used after applying tourniquet at base. Adequate chordae release with straightening of penis was achieved before urethral repair was started. We found chordae in 58% of patients presented to us for hypospadias repair.

For the selection of repair procedure in our study, site of native meatus and presence of chordae were noted along with laxity of penile skin for adequate flap coverage. Since the introduction of tabularize incised urethral plate urethroplasty, it is being assessed in primary as well as in failed previous repair, and so results have been found satisfactory^{8,10,12,14,20,21,22,23}. We used procedures which are described in their complete reliance according to book as mentioned in procedural

details of our study.

For urinary drainage, we used indwelling Foley's catheter for 07-14 days. It has produced more satisfactory results and patient compliance than the urethral stents. Urethral stents were found painful for patients and hesitancy while micturating through it, usually got dislodged and resulted in disruption of repair. Different studies have practiced bladder drainage from 07-10 days similar to our study^{8,9,24}. While a study of comparison between balloon stents and simple stents into urinary bladder claim equal advantage in hypospadias repair^{16,25,26}. This study does not comment on use of urethral stents. Suprapubic urinary diversion proximal to repair site for 04-11 days for secondary repair or fistula repair after hypospadias surgery^{27,28} was found beneficial in protecting repair site. In another study, comparing repair with in dwelling stents and no stents, the complication rates in stented patients were 4.6% while non stented patients had 18.9% complication rate²⁹.

Dressing used after repair in our study was sandwiched dressing with mild compression in distal penile hypospadias repair while in proximal penile hypospadias repair we used encircling gauze dressing over a tulle gauze. Both dressing were removed 24 to 48 hours after surgery. Dressing following the hypospadias surgery has the benefit of gentle compression for hemostasis immobilization of wound and formation of hemostatic seal. Potential disadvantage of dressing include ischemia, infection and pain during removal. In a comparative study of dressed and non dressed hypospadias repair, no gross difference was observed in outcome. This study concludes that success rate of hypospadias repair, that preserves the urethral plate is independent of dressing used. Dressing may not be indicated for all hypospadias repairs^{30,31}.

The complications observed during this study period were early post operative, and late, noted on follow up visit. Complications noted were fistula formation 07%, Meatal stenosis and urethral stricture of anastomotic site 07%, flap necrosis 2%, diverticula formations 1%, residual chordae 3%, and wound dehiscence 03%. Initial

success rate was counted by patients who remained with out complications and overall success rate was counted after correction of complications successfully. Initial success rate of our study was 78% and over all success rate was 92%. These results are very much comparable to the literature available nationally and internationally.

The fistula formation 5%- 20%, Meatal stenosis 1.1% to 22.7%, stricture formation 0% to 10%, diverticula 0.6% to 4%, flap necrosis 1-2%, graft loss up to 10%, wound dehiscence 1.3%-6% have been noted in various studies^{8,9,16,17,18,19,29,32-37}. Management of these complications has improved over all success rate of hypospadias surgery. Two stage repairs of hypospadias have higher complications.

Single stage repair has now been widely practiced and have promising results in proximal penile, midshaft and distal as well as coronal hypospadias especially when urethral plate conservation technique is used. Since the introduction of Snodgrass urethral plate dorsal incision technique, results have been exceptionally good in primary as well as secondary repairs of hypospadias^{10,20,33}. Onlay flap or double faced tabularized flaps have high complication rate and if urethral plate is not dissected, have higher rate of recurrent chordae. MAGPI repair has excellent results in Meatal recession after hypospadias surgery, which is found in majority of patients on long term follow up¹¹. Mathieu's flap repair has excellent results in secondary repair of fistulas where urethral plate is not intact while Snodgrass repair is best with urethral plate intact fistulas after hypospadias repair^{23,33,38}. Penoscrotal and Perineal hypospadias repairs have highest complication rate (50%) and Island flap technique show best results in single stage^{18,22,39,40-42}. Fistula formation has been the commonest complication in all type of repairs and notorious is penoscrotal and perineal hypospadias repairs^{39,40}.

Fistula repair types are

- I. Simple closure
- II. Local rotation flap
- III. Tube graft reconstruction

Waiting period must not be less than 6 months before repair. Simple closure has more failure rates. Careful pre surgical assessment of patient, inversion of urethral mucosa avoidance of any overlapping suture line and urinary diversion proximal to repair, usage of thin absorbable suture are main criteria for satisfactory fistula repair^{28,39,43}.

Hypospadias cripples term was floated for patients with remaining functional complications after previous hypospadias repairs and increased complication rates⁴⁴. Stricture at anastomotic site of native meatus and neo urethra continues to be a significant complication of all hypospadias repairs. Initial therapy is OIU or dilatation but many cases may require open urethroplasty⁴⁵. We have achieved 90% success in managing stricture with dilatations only.

Criteria for success of any hypospadias repair is glanular meatus, single forward directed stream, unimpeded voiding, absence of penile chordae, good cosmesis, no need for secondary procedure³⁰. An objective based scoring system for hypospadias repair "Hypospadias Objective Scoring Evaluation", system has been defined⁴⁶. This scoring system includes meatal location meatal shape, urinary stream, straightness of erection, presence and complexity of any urethral fistula. Surgeons, nurses, parents of child independently assess each patient.

Follow up period has remained very important to assess the functional, structural and cosmetic outcome of any type of repair for any type of hypospadias. In our study follow up period was up to 36 months. International literature shows different studies with follow up period ranging from one month to 180 months^{8,9,10,22,42,44,45}.

CONCLUSION

A thorough evaluation of both urethral and penile malformation is mandatory for the choice of best surgical treatment of patients with hypospadias. The site, size of meatus, presence of chordae and velamentous distal urethra must be carefully assessed. So far, no single procedure has proved 100% successful. That is why

more than 300 procedures are recognized for hypospadias repair. One procedure repeatedly practiced can ultimately produce satisfactory results in one hand in achieving the ultimate goal of reconstructed penis that is functionally and cosmetically normal in hypospadias surgery. In distal glanular or coronal hypospadias, the meatal advancement with glanuloplasty is treatment of choice. In mid shaft or proximal penile, Snodgrass technique with urethral plate conservation produces best results. In more proximal, penoscrotal, perineal hypospadias Duckett's technique has so far produces best results if practiced repeatedly. Hypospadias repair should be offered to the child before school going age, if possible before first year of life, so as to prevent psychological impacts of genital malformations.

REFERENCES

1. Duckett JW: **Successful hypospadias repair contemp** Urol 1992; 4:42-55.
2. Sommer JT; Stephen; FD: **Dorsal urethral Diverticulum of fossa navicularis, symptoms, diagnosis and treatment.** J. Urol 1980; 124:94-98.
3. Avellan L: **The incidence of hyporpadias in Sweden.** Scand J plast Reconstr surg 1975; 9: 129-138.
4. Khuri FJ, Hardy BE, Churchill BM: **Urologic anomalies associated with hypospadias.** Urol clin North Am 1981; 8: 565-571.
5. Culp OS, Mc Roberts JW: Hypospadias: In Alken CE, Dix V, Good win WE, et al Eds: **Encyclopedia of Urology.** New York, Springer-Verlag, 1968, PP 11307-11344.
6. Duckett JW: Foreward: **Symposium on hypospadias,** Urol clin North Am 1981; 8: 371-377.
7. Bianchi M: **Correction of hypospadias.** Arch Ital Urol Androl. 1998 Dec; 70 (5): 219-22.
8. Tonvichien L, Niramis R: **Tubularized incised plate urethroplasty in hypospadias repair. Experience at Queen Sirikit National Institute of Child Health.** J Med Assoc Thai 2003 Aug; 86 suppl 3: S522-30.
9. Sauvage P, Becmeur F, Zango I, Moog R, Kauffmann I: **Original dorsal plasty of the glans in distal hypospadias.** Prog Urol. 2003 Sep; 13 (4): 660-9.

10. Imamoglu MA, Bakirtas H: **Comparison of two methods. Mathieu and Snodgrass in hypospadias repair.** Urol. Int. 2003; 71 (3): 251-4.
11. Marte A, Di Iorio G, Depasquale M: **MAGPI, procedure in meatal regression after hypospadias repair.** Eur J Pediatr Surg. 2001 Aug; 11 (4): 259-62.
12. Hayashi Y, Kajima Y, Mizuno K, Nakane A, Tozawa K, Sasaki S, Kohri K: **Tubularized incised plate urethroplasty for secondary hypospadias surgery.** Int J Urol. 2001 Aug; 8 (8): 444-8.
13. Retik AB, Borer JG: **Primary and re operative hypospadias repair with Snodgrass technique.** World J Urol. 1998; 16 (3): 186-91.
14. Andersen B, Mitchell M: **Recent advances in hypospadias: current surgical technique and research in incidence and etiology.** Curr. Urol Rep. 2001 Apr; 2 (2): 122-6.
15. Anikwe RM, Kamal BA, Hegazi MM, Hashish M, El Darawani H, Taha SA: **Anterior hypospadias. Is repair necessary with urination in a sitting or squatting position.** Saudi Med J. 2000 Apr; 21 (4): 364-7.
16. Guralnick ML, al Shammari A, Williot PE, Leonard MP: **Outcome of hypospadias repair using the tubularized incised plate urethroplasty.** Can. J. Urol. 2000 Apr; 7 (2): 986 - 91.
17. Cartellan M, Labbie A, Lince L, Gosalbez R: **Versatility of Snodgrass technique for correction of different types of hypospadias.** Arch Esp Urol. 2000 Sep; 53 (7): 625-8.
18. Barroso U Jr, Jednak R, Spencer Barthold J, Gonzalez R: **Further experience with double onlay preputial flap for hypospadias repair.** J Urol. 2000 Sep; 164 (3 pts 2): 998-1001.
19. Kogan BA: **Intra operative pharmacological erection as an aid to pediatric hypospadias repair.** J Urol. 2000 Dec; 164 (6): 2058-61.
20. Barrack SM, Hamdun SH: **Tabularized incised plate urethroplasty for distal hypospadias.** East Afr Med J. 2001 Jun; 78 (6): 327-9.
21. De-Filippo RE, Bauer SB: **New surgical technique in Pediatric urology.** Curr Opin Urol. 2001 Nov; 11 (6): 591-6.
22. Demirebilek S, Kanmaz T, Aydin G, Yucesan S: **Outcomes of one stage techniques for proximal hypospadias repair urology.** 2001 Aug; 58 (2): 267-70.
23. Boddy SA, Samuel M: **Mathieu and 'V' incision Sutured (MAVIS) results in a natural glanular meatus.** J Paediatr Surg. 2000 Mar; 35 (3): 494-6.
24. Jiang R, Chen JH, Li HW, Chen TL: **Folding and everting distal end of graft flap to reduce orifice stenosis following onlay urethroplasty.** Asian J Androl, 2003 Jun; 5 (2): 159-61.
25. Van Kote G: **Balloon Stent, simple and efficient drainage in hypospadias repair.** Prog Urol. 2001 Dec; 11 (6): 1340-1.
26. Ghareeb FM, Azooz MA: **Hypospadias repair using a modified Foley's Catheter (hole end catheter)** Tech Urol. 2001 Sep; 7 (3): 241-5.
27. Elbakry A: **Management of urethrocutaneous fistula after hypospadias repair, 10 year experience.** BJU Int. 2001 Oct; 88 (6): 590-5.
28. Latifoglu O, Yavuzer R, Unal S, Cavasoglu T, Atabay K: **Surgical treatment of urethral fistula following hypospadias repair.** Ann. Plast Surg. 2000 Apr; 44 (4): 381-6.
29. Bouson H, Smiley D, Reinberg Y, Gonzalez R: **Distal hypospadias repair without stents. Is it better?** J Urol. 1994 Apr; 151(4):1059-60.
30. Van Savage. JG, Palanca LG, Slauch enhoupt BL: **A prospective randomized trial of dressing versus no dressing for hypospadias repair.** J Urol. 2000 Sep; 164 (3 pt 2): 981-3.
31. Oh Sumi N: **Post operative compressive penile dressing using fibrin seal (Tisseal) and tulle gauze for hypospadias repair.** Plast Reconstr Surg. 1998 May; 101 (6): 1737-8.
32. Price RD, Lambe GF, Jones RP: **Two stage hypospadias repair, audit in a district general hospital.** Br J Plast Surg. 2003 Dec; 56 (8): 752-8.
33. Yang SS, Chen SC, Hsieh CH, Chen YT: **Re operative Snodgrass procedure** J Urol. 2001 Dec; 166 (6): 2342-5.
34. Kass EJ, Chung AK: **Glanuloplasty and in situ tubularization of urethral plate, long term follow up.** J

- Urol. 2000 Sep; 164 (3pts 2) 991-3.
35. Holland AJ, Smith GH, Cass DT: **Clinical review of Snodgrass hypospadias repair.** Aust NZJ Surg. 2000 Aug; 70 (8): 597-600.
 36. Dayanc M, Tan MO, Gakalp A, Yilirim I, Peker AF: **Tubularized incised plate urethroplasty for distal mid penile hypospadias.** Eur Urol. 2000 Jan; 37 (1): 102-5.
 37. Snodgrass W, Koyle M, Manzoni G, Harwitz R, Caldamone A, EhrlickR: **Tabularized incised plate hypospadias repair in proximal hypospadias.** J Urol. 1998 Jun; 159 (6): 2129-31.
 38. Ravasse P, Petit. T: **Mathieu's urethroplasty in surgery for hypospadias post operative complications.** Ann Urol (Paris): 2000 Aug; 34 (4): 271-3.
 39. Aragona F, Cisternno A, Passerini GlazelG: **Reconstructive surgery in complex hypospadias therapeutic indications and technical consideration in 93 cases.** Arch Esp Urol. 1994 Dec; 47 (10): 1011-5.
 40. Powel CR, Mcaleer I, Alagiri M, Kaplan GW: **Comparison of flaps versus grafts in proximal hypospadias surgery.** J Urol. 2000 Apr; 163 (4): 1286-8.
 41. Hohen feliner R: **One stage hypospadias repair.** Eur Urol. 2000 Oct; 38 (4): 483.
 42. Sugita Y, Tanikaze S, Yoshino K, Yamamichi F: **Severe hypospadias repair with meatal based para coronal skin flap. The modified Koyanagi repair.** J Urol. 2001 Sep; 166 (3): 1051-3.
 43. Hayashi Y, Magami M, Kojima Y, MogamiT, Sasaki S, Azemoto M, Maru Yama T, Tatsusa H, Tsugaya M, KohriK: **Results of closure of urethra cutaneous fistula after hypospadias repair.** Int J Urol. 1998 Mar; 5 (2): 167-9.
 44. Vander Werff JF, Vander Meulen JC. **Treatment modalities for hypospadias cripples.** Plast Reconstr Surg. 2000 Feb; 105 (2): 600-8.
 45. Duel BP, Barth old TS, Gonzalez R: **Management of urethral stricture after hypospadias repair.** J Urol. 1998 Jul; 160 (1): 170-1.
 46. Holland AJ, Smith GH, Ross FI, CassD: **HOSE; An objective scoring system for evaluating the results of hypospadias surgery.** BJU-Int. 2001 Aug; 88 (3): 255-8.