



Shaft of humerus fracture managed by anteromedial plating through anterolateral approach.

Masroor Ahmed¹, Muhammad Bux², Naveed Ahmed³, Mukesh Kumar⁴, Muhammad Ishtiyaque⁵, Ghulam Hussain⁶

1. MBBS, MRCS, FCPS
Assistant Professor Orthopedic Surgery
United Medical & Dental College.
2. MBBS, FCPS
Assistant Professor Orthopedic Surgery
Shaheed Nuhatarma Benazir Bhutto Medical College Lyari Karachi.
3. MBBS, FCPS
Assistant Professor Orthopedic Surgery
Khairpur Medical College.
4. MBBS, MRCS, FCPS
Consultant Orthopedic Surgeon
Awadh General Hospital Karachi.
5. MBBS, MS (Orthopedic Surgery)
Consultant Orthopedic Surgeon
Sindh Government Qatar Hospital Karachi.
6. MBBS, FCPS
Consultant Orthopedic Surgeon
KVSS Site Hospital Karachi.

Correspondence Address:

Dr. Masroor Ahmed
Department of Orthopedic Surgery
United Medical & Dental College.
mbsurgeon14@gmail.com

Article received on:

09/05/2020

Accepted for publication:

31/10/2020

ABSTRACT... Objective: To assess the use of anteromedial plating in the shaft of humerus fractures concerning the union of fracture and to assess the frequency of complications associated with this approach. **Study Design:** Cross Sectional study. **Setting:** United Medical and Dental College, Shaheed Muhatarma Benazir Bhutto Medical College Lyari and Khairpur Medical College. **Period:** 15 January 2016 to 15 January 2019. **Material & Methods:** All the patients aged 18 years or over presenting with the shaft of humerus fracture were included in the study. The anterolateral approach was used to expose the fracture, and the plate was applied on the anteromedial surface of the humerus. Rodriguez Merchan criteria assessed the functional outcome. All the data was recorded on designated Performa and entered and analyzed by SPSS version 20. **Results:** Two hundred twenty-five patients of both sexes were included in the study. The mean age of the patients in the study was 38.06 ± 11.51 . The mean union time of fracture in our study was 11.76 ± 2.72 weeks. Functional outcome was assessed using Rodriguez Merchan criteria excellent functional outcome was achieved in 165(73.3%) of the cases and good functional outcome in 58 (25.8%) of cases. A fair outcome was achieved in 2 (0.9%) cases. **Conclusion:** Anteromedial plating is the viable option for treating shaft of humerus fractures as it is associated with a high union rate and low or no complications.

Key words: Anterolateral Approach, Anteromedial Plating, Humerus, Radial Nerve Injury, Union.

Article Citation: Soomro A, Siddiqui MA, Perchani A, Raza H, Kamlesh, Luhana S. Efficacy of General Anesthesia as compared to Spinal Anesthesia for patients undergoing Ventral Abdominal Hernia Repair, a Randomized Controlled Trial. Professional Med J 2021; 28(6):881-885.
<https://doi.org/10.29309/TPMJ/2021.28.06.4778>

INTRODUCTION

The shaft of humerus fractures in adults accounts for about 3% of such injuries.¹ The majority of the fractures involve the middle third of the humerus shaft, constituting about 60% of the total.² The main aim of treating the shaft of humerus fractures is to achieve acceptable alignment, the union of fracture, and bring the patient back to the optimum functioning level of function.³ Conservative measures can manage these types of injuries but are associated with joints stiffness due to prolonged immobilization, nonunion, or pseudo-arthritis at the fracture site.⁴

Surgical options for treating shaft of humerus fractures include intramedullary nailing or plates and screws after open reduction and internal fixation.^{1,5} Both options have their pros and cons,

intramedullary nailing being the biologic fixation. Even without exposing the fracture site, it may cause rotator cuff injuries, tendinopathies and may lead to delayed union or non-union.^{6,7} Plate and screws are the rigid construct, but exposing the shaft of humerus and stripping of soft tissues and periosteum may lead to infection, loss of vascularity to bone leading to nonunion even are associated with iatrogenic nerve injury despite all these are associated with good clinical outcome.⁸

Usually, the plate and screw construct is applied on the anterolateral or posterior surfaces of humerus⁹, but when placed on these two surfaces, the radial nerve injury rate is around 5.1%.¹⁰ Similarly, a study conducted by Akan et al¹¹ showed that applying an anteromedial plate was associated with very low chances of

iatrogenic injury of radial nerve that was prevalent with other application sites, i.e., posterior surface and the anterolateral surface of the humerus.

The purpose of this research was to assess the use of anteromedial plating in the shaft of humerus fractures concerning the union of fracture and to assess the frequency of complications associated with this approach.

MATERIAL & METHODS

This cross sectional study was carried out at United Medical and Dental College, Shaheed Muhatarma Benazir Bhutto Medical College Lyari and Khairpur Medical College from 15 January 2016 to 15 January 2019. Ethical approval was obtained from the ethical review committee (UMDC/Ethic/2016/1/1/245) before the study. Non probability consecutive sampling technique was used for sample collection. All the patients aged 18 years or over presenting with the shaft of humerus fracture were included in the study. Patients with open fractures, pathological fracture, polytrauma patients, or patients with intraarticular fracture elbow joint or proximal humerus were excluded from the study. The patient was assessed clinically and radiologically and informed written consent was obtained before inclusion into the study. The x-rays, i.e., AP and lateral of the affected humerus with joint above and joint below, were obtained to assess the fracture pattern. All the fractures were classified according to AO classification. The anterolateral approach was used to expose the fracture, and the plate was applied on the anteromedial surface of the humerus. The patient was evaluated clinically and radiologically after every two weeks, and the union was assessed at six weeks and onwards. Rodriguez Merchan criteria assessed functional outcome after six months of surgery. Rodriguez Merchan criteria contain different variables: the range of movement at shoulder and elbow joint, pain, and disability. All the data was recorded on designated Performa and entered and analyzed by SPSS version 20.

RESULTS

Two hundred twenty-five patients of both sexes were included in the study, 146 (64.9%) were

male, and 79 (35.1%) were female. The patients' mean age in the study was 38.06 ± 11.51 , with a minimum range of 19 and a maximum age range of 67. 137(60.9%) of cases sustained fracture shaft of the humerus as a result of a road traffic accident while 55(24.4%) and 33(14.7%) of cases were as a result of fall and assault, respectively. The right side was involved in 138(61.3%) cases, whereas the left side was 87(38.7%) cases. Fractures were classified according to AO classification, and according to AO classification, 102 (45.3%) were of type 12A3, while 57(25.3%), 46(20.4%), and 20(8.9%) were of type 12A2, 12A1, and 12B2 respectively. The mean operative time was 54.29 ± 7.0 minutes. The mean union time of fracture in our study was 11.76 ± 2.72 weeks. The functional outcome was assessed using Rodriguez Merchan criteria. The excellent functional outcome was achieved in 165(73.3%) cases and good functional outcome in 58 (25.8%) cases. The fair outcome was achieved in 2 (0.9%) of cases, as shown in Table-I. Stratification of data with gender and functional outcome out of 146 male patients' excellent outcomes was achieved in 107 cases, whereas good and fair outcomes in 37 and 2 cases respectively. While out of 79 female patients' excellent outcome was achieved in 58 and good outcome in 21 cases as shown in Table-II. Evaluation of data concerning functional outcome and type of fracture 46 patients was of AO type 12A1, out of which excellent outcome was achieved in 37 cases and good was achieved in 9 cases. 102 cases were of AO type 12A3 out of these excellent outcomes was achieved in 78 cases; good and fair outcomes were achieved in 23 and 1 cases, respectively. Out of the 57 cases of AO type 12A2, the excellent outcome was achieved in 37 cases, whereas good and fair outcome was achieved in 19 and 1 cases, respectively. Out of 20 cases of AO type 12B2, the excellent outcome was achieved in 13 cases and good in 7 cases, as shown in Table-III. The majority of the cases in the study were without complication. 217 patients showed no complication; the superficial infection was observed in 6 (2.7%) cases, 2 (0.9%) patients developed radial nerve injury as depicted in Table-IV.

| Total No. | 225 | |
|---|--------------|-------------|
| Age | 38.06±11.51 | |
| Gender | Male | 146 (64.9%) |
| | Female | 79 (35.1) |
| Mode of Injury | RTA | 137 (60.9%) |
| | Fall | 55 (24.4%) |
| | Assault | 33 (14.7%) |
| Affected Side | Right | 138 (61.3%) |
| | Left | 87 (38.7%) |
| Type of fracture (According to AO classification) | 12A1 | 46 (20.4%) |
| | 12A2 | 57 (25.3%) |
| | 12A3 | 102 (45.3%) |
| | 12B1 | 20 (8.9%) |
| Operative time (minutes) | 54.29±7.00 | |
| Union time (weeks) | 11.76 ± 2.72 | |
| Functional outcome (Rodriguez Merchan Criteria) | Excellent | 165 (73.3%) |
| | Good | 58 (25.8%) |
| | Fair | 2 (0.9%) |
| | Poor | 0 |

Table-I. Descriptive Statistics.

| Functional Outcome | Excellent | Good | Fair | Poor | Total |
|--------------------|-------------|------------|----------|------|-------|
| Male | 107 (73.3%) | 37 (25.3%) | 2 (1.4%) | 0 | 146 |
| Female | 58 (73.4%) | 21 (26.6%) | 0 | 0 | 79 |
| Total | 165 (73.3%) | 58 (25.8%) | 2 (0.9%) | 0 | 225 |

Table-II. Stratification of functional outcome with gender.

| | Functional Outcome | | | | | Total |
|--|--------------------|-----------|------|------|------|-------|
| | 12A1 | Excellent | Good | Fair | Poor | |
| Fracture type (according to AO classification) | 12A1 | 37 | 9 | 0 | 0 | 46 |
| | 12A2 | 37 | 19 | 1 | 0 | 57 |
| | 12A3 | 78 | 23 | 1 | 0 | 102 |
| | 12B2 | 13 | 7 | 1 | 0 | 20 |
| Total | | 165 | 58 | 2 | 0 | 225 |

Table-III. Stratification of functional outcome concerning the type of fracture.

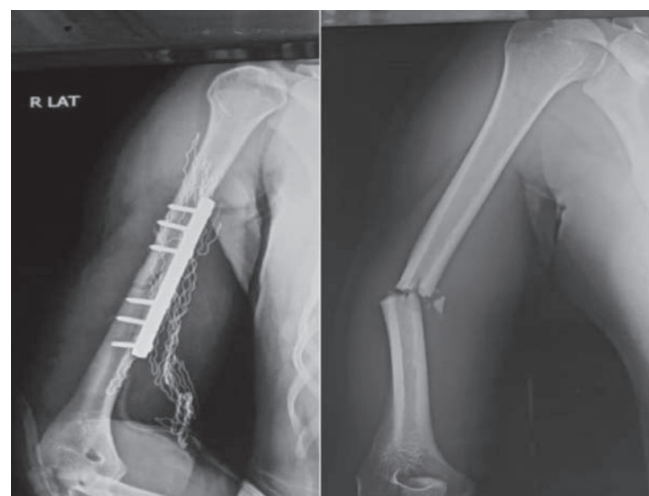


Figure-1. Pre-operative and postoperative radiograph of fracture shaft of humerus fixed by anteromedial plating.

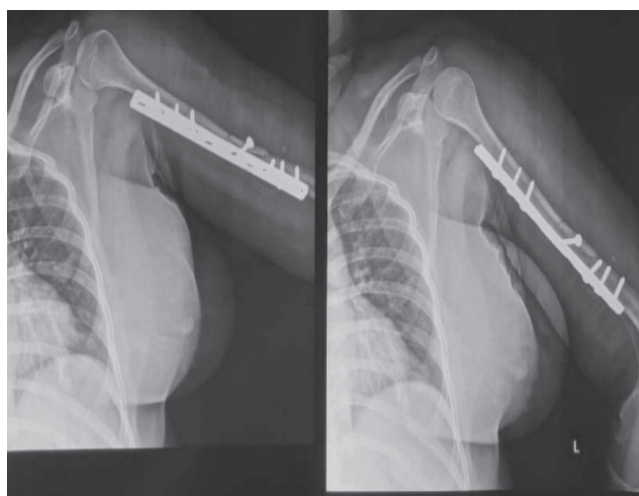


Figure-2. Postoperative picture of shaft of humerus fracture fixed by anteromedial plating.

| | Frequency | Percent |
|-----------------------|-----------|---------|
| no complication | 217 | 96.4 |
| Superficial infection | 6 | 2.7 |
| radial nerve injury | 2 | .9 |
| Total | 225 | 100.0 |

Table-IV. Postoperative complication.

DISCUSSION

The union is not the only factor to achieve in treating the shaft of humerus fractures. Still, the other factors, such as good functional outcome and the preservation of the adjacent neurovascular structures, are of utmost importance. Plates and screws are treated as the ideal fixation device despite the recent advances in the implants.¹² Humerus has been approached through different approaches, and each of them has its advantages and disadvantages.¹³ Concerning the shape and structure of humerus, the anterior and anterior-medial surface of humerus is flat, allowing accurate seating of plate compared to the lateral surface, which contains the attachment of deltoid muscle limits proper seating of plate over it.¹⁴ There has always been discussion regarding the treatment of shaft of humerus fracture, whether it should be managed by the MIPPO technique or open reduction and internal fixation. No difference in outcome with respect to the union has been observed in both except that the MIPPO technique has been associated with exposure to radiation.¹⁵ Plating, whether placed on the anterolateral surface or anteromedial surface, both have shown the same results.¹⁶ Anteromedial plating is relatively safe in terms of radial nerve injury, as Senthil¹⁷ showed no such complication in any of the cases. The union was achieved in all cases in the study for up to 12 weeks. Similarly, another study with the plating on the anteromedial surface showed that the union was achieved in all cases within 16 weeks.¹⁸ Dayez, in his study on medial plating of shaft of humerus, fractures excellent results in terms of no iatrogenic radial nerve injury, infection, or implant failures.¹⁹ These results in terms of no or lower percent of radial nerve injuries were reported by several different authors.^{3,20}

In our study, we found that males were more affected than females, and the right side was involved more than the left side. The majority

of the fractures were of type 12A3. Union in our study was achieved in all cases, around 12 weeks ranging over a minimum of 8 weeks and a maximum of 18 weeks. Excellent and good outcome in our study was achieved in 99.1% of cases, and 0.9% of cases satisfactory outcome was achieved. No significant complications were observed in our study. The superficial infection was observed in 6 patients, but that didn't require any surgical intervention and were successfully managed by oral antibiotics. 2 patients developed signs of radial nerve injury that were most likely a result of increased pressure over the nerve while retraction by the assistant, that was managed by the wait and watch policy and both the cases resolved with full recovery by eight weeks.

CONCLUSION

Anteromedial plating of humerus shaft fractures provides stabile fixation, direct visualization, and plate placement on the bone surface protects the radial nerve from iatrogenic injury. We conclude that Anteromedial plating for the shaft of humerus fracture is a safe and easy procedure associated with little or no complications.







Copyright© 31 Oct, 2020.

REFERENCES

1. Zhao JG, Wang J, Wang C, Kan SL. **Intramedullary nail versus plate fixation for humeral shaft fractures: A systematic review of overlapping meta-analyses. Medicine (Baltimore).** 2015 Mar; 94(11):e599. doi: 10.1097/MD.0000000000000599.
2. Egol AK, Koval JK, Zuckerman DJ. **Handbook of Fractures, 4th edn.** 2010; Wolters Kluwer Lippincot Williams and Wilkin, New York. Page 203.
3. Kirin I, Jurisic D, Grebic D, Nadalin S. **The advantages of humeral anteromedial plate osteosynthesis in the middle third shaft fractures.** Middleast J Med. 2011; 123(3-4): 83-7.
4. Cole PA, Wijdicks CA. **The operative treatment of diaphyseal humeral shaft fractures.** Hand Clin 2007; 23:437-48, VI.

5. Kurup, H.; Hossain, M.; Andrew, J.G. **Dynamic compression plating versus locked intramedullary nailing for humeral shaft fractures in adults.** *Cochrane Database Syst. Rev.* 2011. [CrossRef] [PubMed].
6. Riemer BL, Foglesong ME, Burke CJ 3rd, Butterfield SL. **Complications of Seidel intramedullary nailing of narrow diameter humeral diaphyseal fractures.** *Orthopedics* 1994; 17:19-29.
7. Stannard JP, Harris HW, McGwin G Jr., Volgas DA, Alonso JE. **Intramedullary nailing of humeral shaft fractures with a locking flexible nail.** *J Bone Joint Surg Am* 2003; 85-A: 2103-10.
8. Livani B, Belangero W, Medina G, Pimenta C, Zogiab R, Mongon M, et al. **Anterior plating as a surgical alternative in the treatment of humeral shaft nonunion.** *Intl Orthopaedics (SICOT).* 2010 Oct; 34(7):1025-31
9. Stuby FM, Höntzsch D. **Humerus shaft fractures.** *Z Orthop Unfall.* 2009 May-Jun; 147(3):375-86; quiz 387-90. doi: 10.1055/s-0029-1185702.
10. Paris H, Tropiano P, Clouet D'Orval B, Chaudet H, Poitout DG. **Fractures of shaft of humerus; systematic plate fixation. Anatomic and functional results in 156 cases and a review of literature.** *Rev Chir Orthop Reparatrice Appar Mot.* 2000 Jun; 86(4):346-59.
11. Akan B, Armangil M, Basarir K, Acar H, Bilgin S, Demirtas M. **Clinical evaluation of an anteromedial approach for plate fixation of the proximal humeral shaft.** *Eur J Orthop Surg Traumatol* 2012; 22:289-93. doi: 10.1007/s00590-011-0843-5.
12. Zheng J, Jun-Lin Z, Xiao-Hong W, Lei Shan, Yang Liu. **Biomechanical study of fixation strength of anteromedial plating for humeral shaft fractures, Chin. M. J** 2016; 15 Vol. 129:1850-5.
13. Mills WJ, Hanel DP, Smith DG. **Lateral approach to the humeral shaft: An alternative approach for fracture treatment.** *J Orthop Trauma* 1996; 10:81-6.
14. Oh, C.W., Byun, Y.S., Oh, J.K., Kim, J.J., Jeon, I.H., Lee, J.H. and Park, K.H. **Plating of humeral shaft fractures: Comparison of standard conventional plating versus minimally invasive plating.** *Orthopaedics & Traumatology: Surgery & Research,* 2012;98; 54-60. <http://dx.doi.org/10.1016/j.otsr.2011.09.016>.
15. Hun Lu, Junwei Xu, Baisheng Fu, Jinlei D, Yongliang Y, Guodong Wang, Maoyuan X, Qinghu L, Tong-Chuan H, Fu Wang, Dong Sheng Z.: **Evaluation of the surgical treatment of humeral shaft fractures and comparison between surgical fixation methods Medial approach to treat humeral mid-shaft fractures: A retrospective study.** *J. Orthop. Surg. Res* 2016; 11: 32.
16. Senthil L, Jambu N, Chittranjan BS. **Anteromedial plating of humerus - An easier and effective approach.** *Open J Orthop* 2015; 5:305-10.
17. Kumar B.S, Soraganvi P, Satyarup D. **Treatment of middle third humeral shaft fractures with anteromedial plate osteosynthesis through an anterolateral approach- Malays Orthop. J** 2016; Mar., 10 (1): 38-43.
18. Dayez J. **Internal screwed plate for recent fractures of the humeral diaphysis in adults.** *Rev Chir Orthop Reparatrice Appar Mot* 1999; 85:238-44.
19. Rommens PM, Endrizzi DP, Blum J, White RR. **Humerus shaft. In: Rudi TP, Murphy WM, Eds. AA AO principles of fracture management.** Stuttgart and New York: Thieme 2000; pp. 291-305.
20. Lu S, Wu J, Xu S, Fu B, Dong J, Yang Y, et al. **Medial approach to treat humeral mid-shaft fractures: A retrospective study.** *J Orthop Surg Res* 2016; 11:32.

AUTHORSHIP AND CONTRIBUTION DECLARATION

| Sr. # | Author(s) Full Name | Contribution to the paper | Author(s) Signature |
|-------|---------------------|--|---|
| 1 | Masroor Ahmed | Concept design, collection and assembly of data, drafting of article, final approval and guarantor of article. |  |
| 2 | Muhammad Bux | Collection and assembly of data, Drafting of article. |  |
| 3 | Naveed Ahmed | Collection and assembly of data, Critical revision of the article for intellectual content. |  |
| 4 | Mukesh Kumar | Critical revision of the article for intellectual content. |  |
| 5 | M. Ishtiyaque | Analysis and interpretation of data. |  |
| 6 | Ghulam Hussain | Analysis and interpretation of data. |  |