



1. MBBS, FCPS (Orthopaedics),
MRCS, AO Fellow (Spine)
Spine Fellow at Ghurki
Trust Teaching Hospital
Senior Registrar Orthopaedics
Saidu Medical College Swat.
2. MBBS, FCPS (Orthopaedics)
Assistant Professor Orthopaedic
Unit "A" Medical Teaching Institution
Lady Reading Hospital Peshawar.
3. MBBS, MPH, PGR FCPS
(Orthopaedics)
Ghurki Trust Teaching Hospital,
Lahore.
4. MBBS, FCPS (Orthopaedics)
Senior Registrar
Department of Orthopedics and
Spine Surgery Ghurki Trust
Teaching Hospital, Lahore.
5. MBBS, FCPS (Orthopaedics)
Assistant Professor
Department of Orthopedics and
Spine Surgery Ghurki
Trust Teaching Hospital, Lahore.
6. MBBS, MSc Ortho, FRCS, FCPS
Head of Department
Ghurki Trust Teaching Hospital,
Lahore

Correspondence Address:

Dr. Waqar Alam
MBBS, FCPS (Orthopaedics),
MRCS, AO Fellow (Spine)
Spine Fellow at Ghurki
Trust Teaching Hospital
Senior Registrar Orthopaedics
Saidu Medical College Swat
waqaryousafzai@yahoo.com

Article received on:

20/10/2016

Accepted for publication:

15/12/2016

Received after proof reading:

18/01/2017

INTRODUCTION

Causes of morbidity and mortality in the developing and developed countries are still mainly due to injuries.¹ The incidence of spine injuries are 8 to 246 cases/million while the prevalence is 236 to 1,298 p/million worldwide.² Each year a large number of Pakistani population sustain spinal injuries.³ Studies on spinal injuries have been published in Pakistan but the exact incidence of spinal injuries in Pakistan is still unknown.^{4,5,6} The spine is considered to be stable when the normal anatomical relationship between the vertebrae is maintained within the physiological load without pain, deformity, discomfort or neurological deterioration.⁷ Unstable vertebral burst fractures are 2 or three column fractures according to the Three Column Concept of Denis⁸ and all vertebral

UNSTABLE FRACTURE OF THORACOLUMBAR SPINE; OUTCOME OF TRANS PEDICULAR SCREWS FIXATION

Dr. Waqar Alam¹, Dr. Faaz Ali Shah², Dr. Ashfaq Ahmed³, Dr. Qazi Muhammad Amin⁴,
Dr. Ijaz Ahmed⁵, Prof. Dr. Amer Aziz⁶

ABSTRACT... Objectives: To evaluate the functional outcome of unstable thoracolumbar fractures fixed with pedicular screws and rods. **Study Design:** Descriptive case series. **Setting:** Department of Orthopedics and Spine surgery Ghurki Trust Teaching Hospital Lahore. **Period:** February 2013 to October 2015. **Material & Methods:** Patients of either gender or all ages with thoracolumbar fractures fulfilling the inclusion criteria were fixed with pedicular screws and rods under general anesthesia. Post operatively patients were reviewed monthly for one year and results were analyzed according to modified McNab criteria as excellent, good, fair and poor at final follow up. **Results:** A total of 281 patients including 193(68.68%) males and 88(31.32%) females with mean age 28.32 years (range 18 to 60 years) were included in our study. Majority (91 patients) had fractures of L1 followed by L2 (73 patients) fracture and D12 (67 patients) fracture. Pre operatively 95(33.81%) were neurologically graded as Frankle grade D, 73 (25.98%) grade C while 49(17.44%) were graded as Frankle grade E. Post operatively final follow up at one year yielded excellent clinical outcome in majority (91.46%, n=257) while good and fair outcomes were reported in 6.41%(18 patients), and 2.14%(6 patients) respectively according to modified McNab criteria. No post op neurological deterioration, mortality or other major complication was reported in the study. **Conclusion:** Pedicular screw and rod fixation for unstable thoracolumbar fractures gave excellent functional results in majority of patient as it reduces complications of recumbency and helps in early mobilization. We recommend it as a first line treatment for such fractures.

Key words: Thoracolumbar fractures, pedicular screw, short segment fixation

Article Citation: Alam W, Shah FA, Ahmed A, Amin QM, Ahmed I, Aziz A. Unstable fracture of thoracolumbar spine; Outcome of trans pedicular screws fixation. Professional Med J 2017;24(1):200-204. DOI: 10.17957/TPMJ/17.3685

fractures with more than 50% loss of vertebral height, more than 20 degrees angulation or more than 50% spinal canal compromise need surgical intervention.⁹ A uniform consensus has not yet been developed for the standard treatment of unstable burst fractures or fracture dislocation.¹⁰ The aim of the treatment of unstable thoracolumbar injuries is to optimally decompress the spinal canal and stabilize the spine over a minimum possible segment.¹¹ The spine is approached from anterior, posterior or combine approach for stabilization.^{12,13,14} However, posterior approach is less extensive and commonly used.¹⁵ The introduction of pedicular screw for spine fixation has enabled the surgeon to perform rigid, stable and short segment spine instrumentation thus allowing early post-operative mobilization of the

patients.^{16,17} The aim of this study was to evaluate the post op clinical outcome of transpedicular screw and rod fixation in unstable thoracolumbar fractures by using Mc Nab’s criteria.

Materials and Methods

This study was conducted at department of orthopedics and Spine surgery Ghurki Trust Teaching Hospital Lahore from February 2013 to October 2015. All patients with unstable fractures of dorsolumbar spine (neurological deficit, kyphosis of more than 20 degree, vertebral collapse more than 50% of body height, canal compromise more than 50%) from D7 to L4 and single level fractured vertebrae were included in this study. Poly trauma patients requiring other interventions for thoracic, abdominal, neurosurgical and orthopaedic injuries were excluded from the study. All patients were admitted through emergency or OPD. Anteroposterior and lateral views radiographs were taken to properly evaluate the fractured

vertebrae and their levels. MRI was done in all cases. Informed consent was taken. The study protocols were approved by Ethical Review Board of the respective hospitals. All patients were operated under general anesthesia in prone position using midline posterior approach within 24 hours of their arrival to the hospital. Pedicles were identified and screws were passed and rods were adjusted.

In doubtful cases screening was done with image intensifier. Posterior decompression was done. Wound was closed in layers over radivec drain. All patients were mobilized postoperatively as soon as they could tolerate the pain. All results were analyzed according to modified McNabcriteria (Table-I). Frequency and percentages were calculated for categorical variables. Data was analyzed using SPSS (Version 19). Data presented in graphs and tables.

Grade	Definition
Excellent	Complete resolution of all symptoms and free of pain; no restriction of mobility; able to return to normal work and activities
Good	Marked reduction of pain with the patient generally satisfied, returning to work or usual daytime activities, and taking analgesics seldom or not at all
Fair	Some improved functional capacity; still handicapped and/or unemployed
Poor	Continued objective symptoms of root involvement; additional operative intervention needed at index level, irrespective of repeated operations or length of postop follow up

Table-I. Clinical outcome according to Modified McNab’s Criteria

RESULTS

In our study there were 281 patients out of which 193(68.68%) were males and remaining 88(31.32%) were females. Mean age was 28.32 years, ranging from 18 to 60 years of age. The cause of injury was fall from height in 168 patients and road traffic accident in 113 patients. All patients had unstable fractures and were due for fixation. Mean operative time was 2.5 hours ranging from 1.5 to 4 hours. All patients were operated at the time of presentation in emergency within 24 hours. The mean hospital stay was 6 days ranging from 4 to 15 days. All patients were followed for 12 months. Majority (91 patients) had fractures of L1 while 73 patients had fractures of L2 and the frequency of other vertebral fractures are shown in Figure-1.

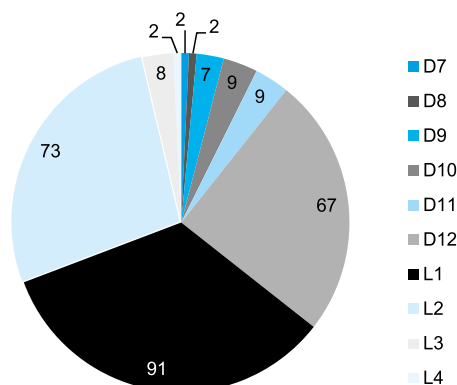


Figure-1. Showing frequencies of vertebral fractures at various levels.

Preoperative the neurological status of all of our patients were assessed according to Frankle grading and shown in Table-II.

Grade	Number of patients	Percentage
A	23	8.19%
B	41	14.6%
C	73	25.98%
D	95	33.81%
E	49	17.44%

Table-II. Preoperative Frankle grading

Post operatively at final follow up at one year clinical outcome was evaluated according to McNab's criteria the results are excellent in 257(91.46%), good in 18(6.41%), fair in 6(2.14%) while no poor results were reported. No post op neurological deterioration, mortality or other major complication was reported in the study. No revision surgery or implant removal was done.

DISCUSSION

Spinal trauma is a serious and debilitating mechanism for patients throughout world. Fall from height and road traffic accidents are the main causes of spinal trauma.¹⁸ In developing countries fall from height is the main cause of spinal trauma.¹⁹ In our study the main mechanisms for trauma were falls from height and road traffic accidents.

Spinal fractures need fixation when these fractures are unstable. The aim of fixation is early restoration of anatomy, neurological restoration and firm and stable fixation for early rehabilitation.²⁰ Various techniques are used for surgical intervention where necessary.

Unstable spinal fractures could either be fixed with anterior, posterior or both anterior and posterior instrumentation. In our series we used pedicular screws and rods for fixation of unstable spine fractures. There are certain advantages of posterior screw fixation with rods. It is easy and spine surgeons are more familiar with this approach. It also preserve the motion segment. The established disadvantage is difficulty in restoring anterior column from posterior which later on result in deformity later on, pain, instability and neurology in some cases.^{21,22} In a series by Khan AA et al²³ and in our series no post-operative neurological deterioration has been observed.

Treatment for fractures of dorsolumbar spine could be either conservative or operative. Disadvantages of conservative treatment are deterioration in neurological status (17%), progressive kyphotic deformity (20%), persistent backaches, decubitus ulcer and deep venous thrombosis.^{24,25,26,27,28} These complications can be avoided by early mobilization and decreased hospital stay by early surgery. Hegde and Shetty²⁹ treated 33 cases of thoraco-lumbar spine fractures with posterior decompression and pedicular screw instrumentation. During post-operative period and follow-up following complications were noted: Urinary tract infection (5), bed sores (3), superficial wound infection (1) and deep wound infection (1), implant prominence (1) and implant failure (1) They concluded that pedicular screw and rods for fracture fixation are a very rigid fixation with high percentage of fusion, low percentage of hardware failure, short segment immobilization and maintenance of curvature of spine. But the surgical technique has a very steep learning curve, exposure to radiation from image intensifier, chance of injury to nerve roots, cord and blood vessels are there.

Hwang and Hur³⁰ treated 46 consecutive patients with thoracolumbar burst fracture were with pedicular screw fixation with or without posterolateral fusion and the clinical outcomes were evaluated using the modified McNab criteria at the final follow-up. They concluded that posterior pedicle screw fixation alone yielded satisfactory results that are equivalent to those of supplemented with posterolateral fusion. Moreover fusion takes longer operation time, increased blood loss and increased hospital stay and permanent motion loss in a spine. To avoid complications of pedicular screw placement, it require image intensifier, technical expertise and experience and has a steep learning curve. The results in our short series of 281 cases have been encouraging. Large sample size with longer follow up are require come to categorical conclusion.

CONCLUSION

Pedicular screws and rods fixation for unstable thoracolumbar fractures gave excellent functional

results in majority of patients. The procedure has minimum complications and helps to mobilize the patient early. We recommend it as a first line treatment for unstable thoracolumbar fractures.


Copyright© 15 Dec, 2016.

REFERENCES

- Juanita A Haagsma^{1,60}, Nicholas Graetz¹, Ian Bolliger¹, Mohsen Naghavi¹, Hideki Higashi¹, Erin C Mullany¹, et al **The global burden of injury: incidence, mortality, disability-adjusted life years and time trends from the Global Burden of Disease study 2013.** *InjPrev*; 2015-20.
- Furlan JC¹, Sakakibara BM, Miller WC, Krassioukov AV. **Global incidence and prevalence of traumatic spinal cord injury.** *Can J Neurol Sci.* 2013; 40(4):456-64.
- Khan KM, Bhatti A, Khan MA. **Posterior Spinal Fixation with Pedicle Screws and Rods System in Thoracolumbar Spinal Fractures.** *JCPSP.* 2012; 22 (12): 778-782.
- Raja IA, Vohra AH, Ahmed M. World J M. **Neurotrauma in Pakistan.** *World J Surg* 2001; 25:1230-7.
- Rathore MF, Rashid P, Butt AW, Malik AA, Gill ZA, Haig AJ. **Epidemiology of spinal cord injuries in the 2005 Pakistan earthquake.** *Spinal Cord* 2007; 45:658-63.
- Qureshi MA, Saleem M, Khan A, Raza A, Butt IA, Khan AS, et al. **Spinal surgery in earthquake victims.** *Pak Armed Forces Med J* 2006; 56:382.
- Mirza SK, Bellabara C, Chapman JR. **Principles of spine trauma care.** In: Bucholz RW,
- Heckman JD, editors. **Rockwood and Green's fractures in adults.** 6th edition. New York: Lippincott Williams & Wilkins; 2006:p. 1402-33.
- Kim HS, Park SK, Joy H, Ryu JK, Kim SW, Ju CI. **Bone cement augmentation of short segment fixation for unstable burst fracture in severe osteoporosis.** *J Korean Neurosurg Soc* 2008; 44:8-14.
- Liao JC, Fan KF, Chen WJ, Chen LH. **Posterior instrumentation with transpedicular calcium sulphate graft for thoracolumbar burst fracture.** *IntOrthop* 2009; 33:1669-75.
- Yue JJ, Sossan A, Selgrath C, Deutsch LS, Wilkens K, Testaiuti M, et al. **The treatment of unstable thoracic spine fractures with transpedicular screw instrumentation: a 3-year consecutive series.** *Spine.* 2002; 27(24):2782-7.
- Sasso RC, Renkens K, Hanson D, Reilly T, McGuire RA Jr, Best NM. **Unstable thoracolumbar burst fractures: anterior-only versus short-segment posterior fixation.** *J Spinal Disord Tech.* 2006; 19(4):242-8.
- Danisa OA, Shaffrey CI, Jane JA, Whitehill R, Wang GJ, Szabo TA, et al. **Surgical approaches for the correction of unstable thoracolumbar burst fractures: a retrospective analysis of treatment outcomes.** *J Neurosurg* 1995; 83:977-83.
- Shafiq K, Iqbal M, Hameed A, Mian JM. **Role of transpedicular fixation in thoracolumbar spinal injuries.** *NeuroSurg* 1998; 1:21-7.
- Sar C, Bilen FE. Flexion was more painful than extension. **Thoracolumbar flexion- distraction injuries combined with vertebral body fractures.** *Am J Orthop* 2002; 31:147-51.
- Wesley AC, William TH. Injuries to thoracic and lumbar spine. In: **Wilkins RH, Rengachary SS, editors. Neurosurgery.** 2nd ed. New York: McGraw-Hill; 1996.p 2987-95.
- Jeffrey WP, Joel RL, Eldin EK, Robert WG. **Successful Short-Segment Instrumentation and Fusion for Thoracolumbar Spine Fractures A Consecutive 4 1/2-Year Series.** *Spine* 2000; 25:1157-69.
- Shafiq K, Ahmed M, Rehman A, Abrar S, Mian JM. **Management of unstable lower thoracic and lumbar spine with transpedicular fixation.** *Ann KE Med Coll* 1999; 5:3 03-7.
- Khan I, Nadeem M, Rabbani ZH. **Thoracolumbar junction injuries and their management with pedicle screws.** *J Ayub Med Coll Abbottabad* 2007; 19:7-10.
- Chiu WT, Lin HC, Lam C, Chu SF, Chiang YH, Tsai SH. Review paper. **Epidemiology of traumatic spinal cord injury: comparisons between developed and developing countries.** *Asia Pac J Public Health* 2010; 22:9-18.
- Lee YS, Sung JK. **Long term follow up results of short segment posterior screw fixation for thoracolumbar burst fractures.** *J Korean Neurosurg Soc* 2005; 37:416-21.
- McCormack T, Karaikovie E, Gaines RW. **The load shearing classification of spine fractures.** *Spine.* 1994; 19:1741-44.
- Kim KS, Oh SH, Huh JS, Noh JS, Chung BS. **Dorsal short segment fixation for thoracolumbar junction fractures.** *J Korean Neurosurg Soc.* 2006; 40:249-55.
- Khan AA, Khanzada K, Ayub S, Ali M. **Surgical outcome of transpedicular fixation in thoracolumbar fractures.**

- J Ayub MedColl Abbottabad.2008; 20(4):104-107.
25. Denis F, Armstrong GW, Searls K, Matta L. **Acute thoracolumbar burst fractures in the absence of neurologic deficit: A comparison between operative and nonoperative treatment.** ClinOrthopRelat Res. 1984; 189: 142-49.
 26. Willén J, Lindahl S, Nordwall A. **Unstable thoracolumbar fractures: A comparative clinical study of conservative treatment and Harrington instrumentation.** Spine 1985; 10: 111-22.
 27. Gertzbein SD, McMichael D, Tile M. **Harrington instrumentation as a method of fixation in fractures of the spine.** J Bone Joint Surg Br. 1982; 64: 526-29.
 28. Bradford DS, McBride GG. **Surgical management of thoracolumbar spine fractures with incomplete neurologic deficits.** ClinOrthopRelat Res. 1987; 218: 201-16.
 29. HegdeA,Babu R, Shetty A. **Management of unstable thoracolumbar fractures with pedicular screw instrumentation: A series of 30 cases.** JClinDiagn Res.2013; 7(11):2563-2566.
 30. Hwang JK, Hur JW, Lee JW, Kwon KY, Lee HK. **Comparison of posterior fixation alone and supplementation with posterolateral fusion in thoracolumbar burst fractures.** J Korean Neurosurg soc.2012; 52(4):346-352.

AUTHORSHIP AND CONTRIBUTION DECLARATION

Sr. #	Author-s Full Name	Contribution to the paper	Author=s Signature
1	Dr. Waqar Alam	Conception and design,	
2	Dr. Faaiz Ali Shah	Data collection	
3	Dr. Ashfaq Ahmed	Data collection	
4	Dr. Qazi Muhammad Amin	Data analysis	
5	Dr. Ijaz Ahmed	Data drafting	
6	Prof. Dr. Amer Aziz	Final proof	
		Final approval	