



# PILONODAL SINUS; MANAGEMENT OF PILONODAL SINUS WITH Z PLASTY TECHNIQUE: A STUDY OF 7 YEARS.

Abdul Hakeem Jamali<sup>1</sup>, Ali Akbar Ghumro<sup>2</sup>, Altaf Hussain Ghumro<sup>3</sup>

1. MBBS, MS  
Associate Professor  
Department of Surgery  
PUMHSW, Nawabshah.
2. MBBS, FCPS  
Professor  
Department of Surgery  
PUMHSW, Nawabshah.
3. MBBS, MS  
Senior Registrar  
Department of Surgery  
PUMHSW, Nawabshah.

**Correspondence Address:**  
Dr. Altaf Hussain Ghumro  
Senior Registrar  
Department of Surgery  
PUMHSW, Nawabshah.  
altafkhadim@yahoo.com

**Article received on:**  
20/11/2017

**Accepted for publication:**  
15/05/2018

**Received after proof reading:**  
00/00/2018

**ABSTRACT... Objectives:** Pilonidal sinus is chronic inflammatory condition that usually affect young adult population, despite the current medical advances in the field of medical sciences. The acceptable management of pilonidal sinus is still lacking. This study evaluates the outcome of pilonidal sinus after excision of the whole tract then its closure with a Z plasty technique which is a simple cleft lip repair like method which provides a quick and comfortable remedy. **Design:** A seven years retrospective study. **Setting:** Surgical Department of Peoples Medical College Hospital (later University) and at Private Medical Center at Nawabshah. **Period:** January 2010 to March 2017. **Methodology:** A total of 55 patients suffering from pilonidal sinus were admitted at both sites from the outdoor department. All the data were collected from the admitted record and proforma. All required investigations were done. Excision of sinus followed by Z plasty closure were done in a single stage with drain put by separate stab on one side of the wound. **Results:** Out of total 55 patients 41 (74.5%) patients recovered smoothly while 6 (10%) patients developed major wound disruption, 3 (5.45%) patients developed minor wound disruption and 5 (9.09%) developed wound dehiscence. **Conclusion:** Primary closure of pilonidal sinus with Z plasty technique is technically a simple closure method which provides a comfortable closure with minimum results of wound disruption and dehiscence. Healing is rapid due to comfortable approximation of the wound flaps and thus avoids the problem created in simple closure technique. It can be applicable with every type of patients from heavy build to thin build type.

**Key words:** Pilonidal Sinus, Primary Closure, Z Plasty, Natal cleft, Flap.

**Article Citation:** Jamali AH, Ghumro AA, Ghumro AH. Pilonodal sinus; management of pilonodal sinus with z plasty technique: a study of 7 years. Professional Med J 2018; 25(9):1296-1300. DOI:10.29309/TPMJ/18.4526

## INTRODUCTION

Pilonidal sinus is a tract or small channel that occurs between the buttocks and is an infective tract under the skin. It is often also referred as pilonidal cyst, pilonidal abscess or sacrococcygeal fistula. It is near or on the natal cleft that often contains hairs, skin debris, pussy material as its name indicate, nests of hair (pilus= hair, nidus= nest). it get famous in world war as jeep driver disease because it was common in jeep drivers. Rarely it do occur in interdigital clefts, axilla and even in umbilicus. Classically it is common in 3<sup>rd</sup> decade of life between 20 and 30 years of age. Males are commonly affected more than females as it is rare to see females to be affected probably due to less hairy style and due to posture.<sup>1,2</sup>

It is an acquired condition related to tough and sharp nature of hairs, large buttocks deep natal

cleft, and obesity. There are different modalities of operative treatment ranging from conservative, daily dressings, use of antibiotics, to complex surgical procedures including excision with primary closure with different ways. One can excise whole sinus tract through midline or slightly lateral incision sparing normal neighboring tissue. Defect can be closed by primary closure with Z plasty or raising local flaps or even leaving it as such for secondary intention healing.<sup>3</sup>

## MATERIAL AND METHODS

This study was conducted at private as well public set up at Nawabshah city. The Hospital selected was Surgical Unit 1 of Peoples Medical College (Later University) and at Private medical center. This study was conducted from Jan 2010 till March 2017 more than seven years. Patients were selected from outdoor department with

basic investigations done and made sure to be fit for anesthesia.

**Surgical Procedure**

Written consent on the proforma with full detail understanding of the procedure was narrated to the patients with lengthy duration of healing procedure and every 15 days of shaving the buttock hairs to avoid fresh intrusion of the hairs into the wound was told clearly. Part was shaved and all patients were operated either in G.A or under spinal anesthesia with jack knife position, Sinus was explored by an elliptical incision upto the depth of pre-sacral fascia with 1 cm of healthy margin also taken. Packing the area with hot normal saline for hemostasis for 4-5 minutes and bleeders cauterized, subcutaneous flaps raised after diathermising and separating the underlying tissues with cutting mode of diathermy. A releasing horizontal upper cut was made to right upper flap and left lower flap to facilitate the closure of the wound with vicryl 0 (polyglactin) material in subcutaneous level. Skin closure edge to edge was achieved with zero (0) silk material and stapler. Active redivec drain was put in the subcutaneous space. Patient was put on 3<sup>rd</sup> generation cephalosporin and metronidazole for 2-3 days postoperatively as an indoor patient and discharged usually on 3<sup>rd</sup> to 4<sup>th</sup> day called for to examine the wound. Stitches usually were removed on 10<sup>th</sup> to 14<sup>th</sup> postoperative day.

**RESULTS**

A total of 55 cases were included in this study of whom 49 (89%) were male and only 6 (11%) were female. The mean age was 27 years. Majority of the patient, 54 (98%) has no history of any surgical intervention except 1 (1.8%) where incision drainage was attempted. No any case of recurrence of pilonidal sinus was included neither presented to us.

Majority of the patients 40 (72%) has multiple discharging opening, while only 15 (27.2%) patients presented with a nodule or sinus tract. H/O passing hairs with foul smell discharge was present in 30 (54.5%) cases. No any patient in the series has a systemic illness like diabetes mellitus, tuberculosis. Postoperatively in this procedure

41 (74.5%). Patients recovered smoothly, their stitches were removed after 10-14 days while 6 (10.9%) patients developed major wound disruption which required repeated dressings and later on resuturing were done while 3 (5.45%) patients developed minor wound disruption and 5 (9.09%) developed wound dehiscence but not complete wound disruption. Complete healing of the wound took 4 to 6 weeks in smoothly and in later group it took about 8 to 12 weeks. Majority of the patients were discharged on 3<sup>rd</sup> postoperative day and then called for follow up in outdoor department. Mean hospital stay was 3.4 days.

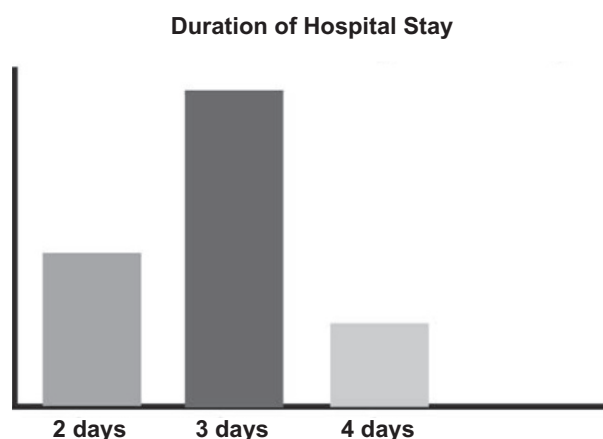
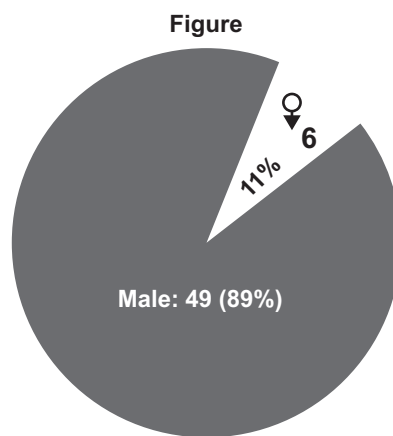


Table of complications	
Normal Health	41 (74.5%)
Major wound disruption	6 (10%)
Wound dehiscence	5 (9.9%)
Minor wound disruption	3 (5.45%)

## DISCUSSION

This is a retrospective study of more than 07 years in a tertiary care hospital. Pilonidal sinus is an acquired condition whose exact cause is not clear.

The condition can present as minor skin nodule to infective tract with discharging sinuses and history of passing dead hairs with foul smell discharge. It may be symptomatic or totally asymptomatic, usually the disease affect young adults male population with hairy skin which usually get break due to postural pressures, the area become weak and pierce the weak skin in the cleft and start injuring the area continuously and acquire the depth of sinus and making the nest of hairs.<sup>3,4</sup>

As shown in the results, most of our patients have not been operated previously and has presented 1<sup>st</sup> time in O.P.D. females are less affected probably due to their less hairy skin, postural habits, and shyness to visit male doctors.<sup>4,5</sup>

Treatment of pilonidal sinus has remained controversial. Different modalities are available for different types of patients ranging from conservative to wide excisional flap methods closure. Most conservative surgical treatment is a relatively simple procedure of laying it open and allow to heal it by secondary intentions which requires long care and time. It may take six months that can be carried out as an outdoor procedure. Another option is pit picking procedure relatively simple outdoor patient option described by Moshe Cips that can be performed as an outdoor procedure creating pit or holes in the tract and sucking out all pus, debris and hairs, washing it, claimed to carry good results.<sup>6</sup> Another option is excision of cyst, sinus or tract, and then either we pack it and carrying out daily dressing may again require long time to heal even some time, two years are required to fill the gap and heal properly.<sup>6,7</sup> Closure method is either by simple approximation after raising the local flaps which usually is not possible in obese patient due to wide gap after excision of tissue. There is a wide gap remained which can't be approximated with local flap method so one can move towards Z

platy technique where one can get free flaps for easy closure just like cleft up procedure. This flap procedure helps rapid recovery with low incidence of disruption especially in obese and even in thin and moderate build patients where simole closure fails to achieve the results.

The search for new technologies as well as for minimally invasive techniques is going on. The technique developed by Meneiro is quite interesting in the treatment of pilonidal sinus claiming to be less painful with low morbidity rate and carrying good healing score by using fistuloscope under direct vision. It is possible to remove and destroy all the infected tissues and granulation areas leaving a small opening for drainage like pit picking technique mentioned above. However, it also takes atleast 01 month to heal.<sup>8,9,10</sup>

As above mentioned the ideal treatment of P,S is not available in each procedure. Here are a lot of queries and controversies present. Ideal surgery should be simple, safe with low morbidity and low incidence of disruption, low recurrence associated with minimum pain and wound problems. Wound disruption and poor healing are contributed by some authors due to ratio of collagen1/111 which yields poor healing results.<sup>11,12,13</sup> An alternative minimally invasive technique is to treat pilonidal sinus with fibrin glue which is less painful than above methods of excisional technique and can be performed under local anesthesia or general anesthesia does not require any dressings or packings and allowed to return to normal activities within 1-2 days. Its long term results are similar to other invasive procedures. Fibrin glue has also shown to be better than more invasive alternatives in the treatment of pilonidal disease, effective in children where a quick return to normal activities are required.<sup>14,15</sup> Another minimally invasive surgical technique used and developed in israel by Moshe Cips et al 2008 is similar to pit picking technique described by Bascon in 1980. In this procedure Biopsy punches are taken by which sinus is cored out and remove the diseased tissue, debris, hairs and leaving only small holes for healing. Patients can resume their activity after one or two days, both

procedures have been successfully combined by L. bano in Rome (Italy)<sup>16,17</sup> Some less commonly used procedures such as pilonidal injection, cryosurgery and electrocauterization are usually not practiced.<sup>18,19,20,21</sup>

Thus aim of the treatment in P.S disease is healing of wound as early as possible either by open method or by primary closure with minimum risk of recurrence and disruption of wound. In open method, long time is required for healing due to which patient loses confidence, lost costly hours, to return for normal activity. Looking to all these objective we have adopted the above procedure which provide sufficient flaps to close easily without any tension as compared to simple closure where sometimes in above situation it is not possible to accommodate the space. Z plasty make the flaps to settle down comfortably without tension. Total 14 (25%) patients developed healing problems which however were managed by dressings. Patients were followed in OPD at 2, 4, 6 monthly interval. However all the patients were advised to cut their buttocks hairs every fortnightly to avoid recurrence with hygienic care maintenance. While the recovery rate is positive for most of the patients. Some may suffer from long term effects like continued postoperative pain.

## CONCLUSION

In the end of article, it is concluded that this procedure of simple closure with Z plasty provides easy way of treating the patients of pilonidal sinus with modification especially in long tracts, and in moderate build or obese patients. It clears the narrow space of wound closure in simple closure technique and associated with low recurrence and low complications rate. It is applicable to any type of pilonidal sinus even in recurrent type.

Copyright© 15 May, 2018.

## REFERENCES

1. Mc Callum I, King PM, Bruce J (2007), **Healing by primary versus secondary intention after surgical treatment by pilonidal sinus.** Cochrane database surgical syst Rev-4(4)- CD 006213.
2. Bascom J. **Pilonidal sinus; experience with kerydekin flap.** BrJ surg.1998;85(6):874.
3. Doll D, Friederichs J, Buleisteix AL, Dusel W, Fued F, Petersen S. **Surgery for asymptomatic pilonidal sinus disease.** Int J Colorectal dis. 2008;23(29):839-44.
4. Bascom J. **Pilonidal disease: Origin from follicles of hairs and results of follicle removal as treatment, surgery.** 1980; 87(5), 567-72.s.
5. Mc Calum IJ, Kung PM, Bruice J. **Healing by primary closure versus open healing after surgery for pilonidal sinus; Systemic review and meta analysis.** BMJ, 2008; 336(7649); 868-71.
6. Karydalin G, **Easy and successful treatment of pilonidal sinus after explanation of Pilonidal sinus.** Aust NZJ Surg 1992; 62:385-9.
7. Surrel JA (1994) **Pilonidal disease.** Surg Cal Clinics of North America 74:1309-1315.
8. Corant T, Ribb J, Mahtene H, Gustafson UM, Caraff W (2011) **sinus excision and primary closure versus laying open in pilonidal disease: A prospective randomized trial.** Dis colon rectum 54:300-305.
9. Soli C, Halin Ioser D, Dindo D, Clavien PA, Helzer F (2008) **A novel approach for treatment of Saccrococcygeal pilonidal sinus less is more.** Int. J Colorectal Dis 23: 177-180.
10. Aman Z, Hadi A, Ahmed J, Akbar Khan S, Ozair Shah Fetal (2011) **Comparison of wide open excision and Karydekus procedure for pilonidal sinus disease.** Journal of surgery Pakistan (international) 16.136-139.
11. Al Jaber JM, (2001) **excision and simple primary closure of chronic pilonidal sinus** Eur J Surg167:133-135.
12. Khweji HT, Bryan S, Weaver PC, **Treatment of natal cleft sinus: A Prospective Clinical and economic evaluation.** BMJ. 1992;304: 1282-3.
13. Menden CRS, Ferreins M.LS de, Seppengaig A, Luma ML. **Endoscopic Pilonidal sinus treatment. (E.P.S.7): a minimally invasive approach.** J colorectal (Rio J) 35. Jan/ Mar 2015.s.
14. Milito G, Gortese F, Casciani CU, **Rhombi flap procedure for pilonidal sinus results from 67 cases.** Int J colorectal dis 1998; 13:113-5.
15. Menn F. **Pilonidal sinus excision. Primary lateral closure with wound drainage.** J Surg Pak 2005, 10(2):18-20.
16. Shams A Nadeem, Azharuddin, **Excision with primary closure of pilonidal sinus,** Pakistan J of Surgery 2006 vol 22(27) 82-85.

17. Muhammad HA, Kedry I, Ddly S. **Comparison between three therapeutic modalities for non complicated Pilonidal Sinus disease; surgeon.** 2005; 3:73-7.
18. Hameed KK. **Outcome of surgery for chronic natal cleft Pilonidal Sinus. A randomized trial of open compared with closed technique.** Med forum monthly 2001;12:20-23.
19. Hodges RM. **Pilonidal sinus.** Beston Med Surg J 1880, 103; 4654-6.
20. Ahmed S, Pervez N, Baloch N. **Primary closure of Pilonidal Sinus: Our experience P.** J.S.2010; 26:36-40.
21. Duchaten J, De Mel, J. Boston H. **Allegret W pilonidal sinus excision merciplization- phenolization.** Acte Chir Beig.1985:85,325-328.
22. Shafik A. **Electro cauterization in the treatment of Pilonidal Sinus.** Int Surg.1996:81: 83-84.



“

*You're not sorry you did it,  
you're sorry I found out.*

– Unknown –

”

**AUTHORSHIP AND CONTRIBUTION DECLARATION**

Sr. #	Author-s Full Name	Contribution to the paper	Author=s Signature
1	Abdul Hakeem Jamali	Introduction Data Collection.	
2	Ali Akbar Ghumro	Data collection, Data analysis, Discussion.	
3	Altat Hussain Ghumro	Review of literature, References, Results.	