



Hearing assessment and status of tympanic membrane pre and post-operated tympanoplasty in cases of CSOM (Chronic Suppurative Otitis Media).

Tahir Hussain Khan¹, Humaira Tahir², Imran Ali³, Sohail Abdul Malik⁴

1. MBBS, DLO
ENT Surgeon
Social Security Landhi Hospital
Karachi.
2. MBBS, FCPS
Consultant Gynecologist
Social Security Landhi Hospital
Karachi.
3. MBBS, FCPS
Consultant Anesthetist
Social Security Landhi Hospital
Karachi.
4. MBBS, DLO, FCPS
Professor of ENT
Indus Medical College, Tendo
Mohammad Khan, Hyderabad,

Correspondence Address:

Dr. Tahir Hussain Khan
ENT Surgeon Sindh Employee's
Social Security Landhi Hospital
Karachi.
tahirhussainkhan99@gmail.com

Article received on:

05/03/2020

Accepted for publication:

25/05/2020

ABSTRACT... Objectives: To compare assessment of hearing by PTA and status of tympanic membrane by oto-endoscope, pre-operative and post-operative tympanoplasty. **Study Design:** Retrospective/ Comparative study. **Setting:** Social Security Landhi Hospital Karachi and Al-Tibri medical College & Hospital, Karachi. **Period:** July 2017 to June 2018. **Material & Methods:** 76 patients were included for this study with both genders who had dry tympanic membrane perforations. Age ranged between 18 to 40 years. Two groups were made, A (pre-operative) and B (post-operative). In group-A, tympanic membrane perforations were examined. 45 patients had small size (25%) perforations, 15 medium size (50%) and 16 subtotal (75%). Hearing assessment was done by Pure tone Audiometry (PTA). After 1, 2 and 3 months post-tympanoplasty, grafted tympanic membrane was examined and pre-operated status of tympanic membrane was compared with post-operated status of tympanic membrane. PTA was done after 3 months and it was compared it with pre-operated PTA. **Results:** Examination of tympanic membrane before tympanoplasty was performed, perforations were noted in all patients with different sizes in their tympanic membrane. PTA (pure tone audiometry) was advised before tympanoplasty to all patients. Weber test was performed on 1st post-operated day, it was lateralized towards operated ear which indicate the safety of inner ear. Post-operated 1, 2 and 3 months, tympanic membrane was examined with oto-endoscope. Intact grafted tympanic membrane was seen in 70 patients after 1 months. After 2 months, 72 patients had intact grafted tympanic membrane and after 3 months, 73 patients out of 76 patients had intact grafted tympanic membrane. PTA was also advised after 3 months of tympanoplasty and it was compared with pre-operated pure tone audiometry (PTA). Air conduction (AC) was decreased 15.39dB after tympanoplasty. AB-gap reduction 13.95dB was seen in 73 patients which showed hearing improvement. P value is < 0.001 significant. **Conclusion:** Tympanoplasty is a good and safe procedure for hearing improvement by reduction of AB-gap as well as provide protection of middle ear mucosa from infections due to closure of perforations of tympanic membranes.

Key words: AB-gap, Pure Tone Audiometry, Grafted Tympanic Membrane and Oto-Endoscope.

Article Citation: Khan TH, Tahir H, Ali I, Malik SA. Hearing assessment and status of tympanic membrane pre and post-operated tympanoplasty in cases of CSOM. Professional Med J 2020; 27(12):2581-2585.
<https://doi.org/10.29309/TPMJ/2020.27.12.4624>

INTRODUCTION

Chronic suppurative otitis media defined as persistent middle ear infection in the presence of tympanic membrane perforation, continuous or recurrent ear discharge among the patients with conductive hearing loss. Whenever disease not cured with medical treatment, considering repair of perforated tympanic membrane (tympanoplasty). Partial or total sensory neural hearing loss after tympanoplasty has been reported. Conductive hearing loss can treated with surgery but sensory neural hearing loss is permanent and treated only

with Hearing Aid.¹

Poor living environment, overcrowding, bad hygiene and mal nutrition have been reported for wide spread prevalence of chronic otitis media in under developed countries. Histopathologically ally chronic otitis media is an inflammatory process of muco-periosteal lining of middle ear cleft, mucus membrane of middle ear is edematous, sub mucosal fibrosis and infiltration of inflammatory cells. The mucosal edema can lead to formation of aural polyp, protruded into

external auditory canal. Ulceration and granulation formation lead to persistent otorrhea.²

Sufficient area of contact between graft and tympanic membrane remnant is basic requirement for successful closure of perforated tympanic membrane. Graft failure rate is higher in anterior and large perforations. Tympanoplasty is standard procedure for repair of perforated tympanic membranes. Bilateral tympanic membrane perforations can be repaired on same day, it is quick and more comfortable procedure.³

Tympanic membrane is responsible for air bone sound vibration of ossicular chain. Various graft materials like temporalis fascia, cartilage, dura mater, fat, vein and skin are used for repair of tympanic membrane.⁴

Eavey was the first Otologist who repaired small tympanic membrane perforation with cartilage graft, Rourke T followed same technique to close perforated tympanic membrane with the help of rigid oto-endoscope.⁵

Success of tympanoplasty can be monitored with subjective and objective. Subjective includes improvement in hearing, absence of ear discharge and absence of tinnitus. Objective includes healing of perforations seen (intact grafted tympanic membrane) and improvement of hearing threshold demonstrated by PTA.⁶

MATERIAL & METHODS

76 patients were take part in this study randomly from Social Security Landhi Hospital Karachi and Al-Tibri Medical College & Hospital Karachi. Duration of Study was 1 year (12 months) from July 2017 to June 2018. Two groups made group-A and group-B. Group-A was pre-operative and Group-B was post-operated group. Tympanoplasty performed in two different hospitals 1- Social Security, Landhi Hospital, Karachi. 2-Al-Tibri Medical College & Hospital, old thana Malir, Karachi.

Pure tone audiometry (PTA) advised pre-operatively to each patients. Examination of tympanic membrane done with oto-endoscope.

Small size perforation in 45 patients, medium size perforation in 15 patients and large sized perforation of tympanic membranes seen in 16 patients. Tympanoplasty performed in all 76 patients. On very next day of tympanoplasty, weber test performed and it was lateralized towards operated ear which indicated the safety of vestibulo-cochlear system. Examined the grafted tympanic membrane after 1, 2 and 3 months of post-tympanoplasty and noted the integrity of tympanic membrane. 3 months post-tympanoplasty PTA advised and compared it with pre-operative PTA. In PTA air conduction (AC), bone conduction (BC) and air bone gap (AB-gap) measured.

RESULTS

For study purpose, Oto-endoscopic examination of grafted tympanic membrane done after 1, 2 and 3 months. 70 patients had intact grafted tympanic membrane and 6 patients had residual perforation after 1 month of tympanoplasty. After 2 months of tympanoplasty 72 patients had intact grafted tympanic membrane and in 4 patients perforation remained. 3 months post-tympanoplasty 73 patients had intact grafted tympanic membrane while in 3 patients perforation remained in their tympanic membrane. In group-A (pre-operative), on PTA mean (AC) air conduction was 42.34dB, mean (BC) bone conduction was 13.05dB and mean AB-gap was 29.39dB. In group-B (post-tympanoplasty) mean (AC) air conduction was 26.95dB, (BC) bone conduction was 13.12db and AB-gap was 15.44dB. Mean reduction of air conduction is 15.39db after tympanoplasty and mean reduction of AB-gap 13.95db.

Table-I Shows status of tympanic membrane pre and post-tympanoplasty. Pre-operative all 76 patients had perforations in their tympanic membrane. 1 month post-tympanoplasty, in 70 patients grafted tympanic membrane intact and remained perforation in 6 patients. After 2 months of tympanoplasty 72 patients had intact grafted tympanic membrane and in 4 patients remained perforation. 3 months post-tympanoplasty, 73 patients had intact grafted tympanic membrane while in 3 patients remained perforations in their tympanic membrane. Graft success rate is

achieved 96.05% after tympanoplasty.

Table-II Shows PTA results pre and post-operated tympanoplasty in which air conduction, bone conduction and AB-gap measured. Pre-operative mean air conduction was 42.34db and post-operated air conduction changed into 26.95dB. Air conduction gained is 15.39dB. Pre-operative AB-gap was 29.39dB and post-operative AB-gap changed into 13.95, AB-gap gained is 13.95dB. p value is found to be < 0.001 is significant. No change in bone conduction showed safety of vestibule-o-cochlear apparatus. Hearing was

improved after tympanoplasty. Figure-2

Figure-1 Shows pre-operative AB-gap, post-operative AB-gap and reduction of AB-gap. Pre-operative AB-gap was 29.39dB and post-tympanoplasty AB-gap changed into 15.44db and reduction of AB-gap is 13.95db.

Figure-1 this pie chart shows pre-operative status of tympanic membranes. 45 patients had small perforation, 16 patients had medium sized perforations and 15 patients had large perforation in their tympanic membrane.

Examination of Tympanic membrane with oto-endoscope	Pre-operative Status of tympanic membrane(Group-A)	1 month of post-tympanoplasty. (Group-B)	2 month of post-tympanoplasty. (Group-B)	3 month of post-tympanoplasty. (Group-B)
Intact Grafted Tympanic membrane	0	70	72	73
Perforation in Tympanic membrane	76	6	4	3

Table-I. Showing status of tympanic membrane pre and post-operative 1, 2 and 3 months of tympanoplasty

PTA	Pre-operative Tympanoplasty (Group-A)	Post-operated Tympanoplasty (Group-B)	Gain of Hearing	P-Value
Air Conduction(mean) in dB	42.34	26.95	15.39	<0.001
Bone Conduction(mean) in dB	13.10	13.12	0.02	<0.793
AB-gap(mean) in dB	29.39	15.44	13.95	<0.001

Table-II. Showing PTA results pre and post-tympanoplasty with p value.

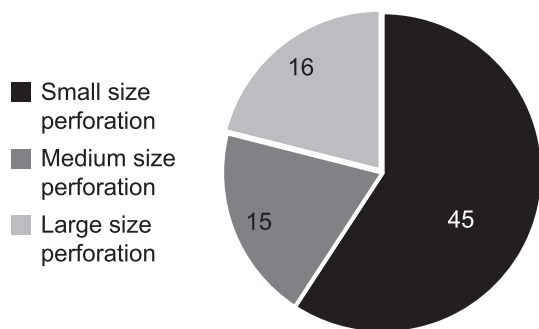


Figure-1. This pie chart showing different sizes perforations in tympanic membranes (Group-A)

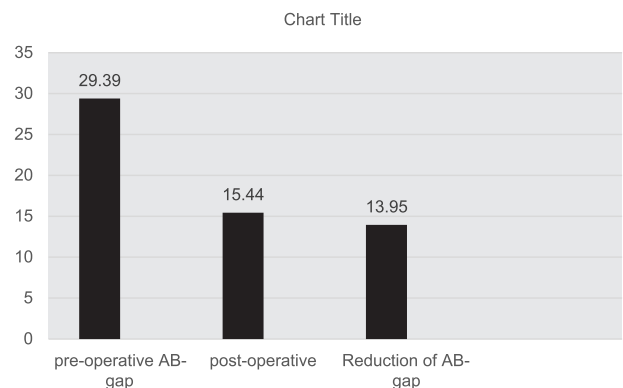


Figure-2. Showing pre-operative AB-gap, post-operative AB-gap and reduction of AB-ga

DISCUSSION

Bhushan K et al (2015) mentioned in his study that pre-operative hearing threshold was 45.69dB while average post-operative hearing threshold was 27.69dB, the average gain was 18dB. The average pre-operative AB-gap was 32.44dB and post-operative AB-gap was 14.44 dB, average gain was 18dB³. Our study co relate with this study in which average pre-operative hearing threshold was 42.34dB, post-operative hearing threshold was 26.95dB and average AB-gap reduction was 13.95dB.

In another study (2014) showed that mean pre-operative air conduction was 35.3 ± 2.78 dB and post-operated air conduction was 22.27 ± 5.4 dB. There was gain of 14dB after surgery. All cases had excellent cosmetic outcome.⁷ This is also co relate with our study in which average gain after tympanoplasty was 13.95dB.

Daneshi A et al (2017) described in their study that graft success rate was 94.44%, mean air bone gap improved from 13.88dB pre operatively to 9.16dB post-operatively.⁸ In our study graft success rate is 96.05%.

A study published in 2019 revealed that graft success rate was 91% in cartilage tympanoplasty while 83% in temporalis fascia tympanoplasty. Pre-operative AB-gap was 19.5 ± 5 dB and post-op. AB-gap was 19.8 ± 4.8 dB⁹, this study co relate with our study.

A study published in 2019 revealed that graft success rate in permeatal group of tympanoplasty was 88% and in microscopic tympanoplasty, it was 84%. Improvement in pure tone audiometry between two group was 9.46 ± 5.41 in microscopic tympanoplasty and 8.29 ± 5.37 in endoscopic tympanoplasty. Improvement in AB-gap between two groups 6.51 ± 2.65 in microscopic and 6.09 ± 4.10 in endoscopic tympanoplasty.¹⁰

In 2017 a study published, which described that the graft uptake rate was 89.7% (26/29). Pre-operative mean air bone gap was 22.7 ± 6.96 db, post-operative AB-gap was 8.9 ± 4.5 dB. A significant decrease in mean AB-gap seen with

p value < 0.001.¹¹

Another study published in 2017 revealed that graft success rate was 93.7% after tympanoplasty. Pre-operative AB-gap was 18.7 ± 7.2 dB while post-operative AB-gap was 11.3 ± 8.6 dB and the p value was <0.001.¹²

A study published recently in 2019 revealed that graft success rate in endoscopic tympanoplasty is 86.66% whereas in microscopic tympanoplasty, it was 83.33%.¹³

Another study reported that pre-operated mean air conduction was 53.22 ± 12.24 dB, post-operated mean air conduction was 39.11 ± 19.93 dB and post-operated AB-gap decreased by 8.68dB.¹⁴ this study also co relate with our study.

CONCLUSION

Tympanoplasty is a good and safe procedure for chronic suppurative otitis media patients in which patients complaint intermittent or continuous discharge with hearing impairment. After tympanoplasty, AB-gap reduced and hearing improved as well as provide protection of middle ear mucosa from infections due to closure of perforations of tympanic membranes.




Copyright© 25 May, 2020.

REFERENCES

1. Al Anazy FH, Alobaid FA, Alshiha WS. **Sensorineural hearing loss following tympanoplasty surgery: A prospective cohort study.** The Egyptian Journal of Otolaryngology. 2016 Apr 1; 32(2):93.
2. Aftab A, Shamsheer A, Shahab FH, Syed AH. **A Prospective Study Comparing the Results of Endoscope Assisted Versus Microscope Assisted Myringoplasty.** Glob J Oto. 2016;1(4):1-6.
3. Bhushan K, Himani D, Joginder G, Vikas K, Yadav SPS, et al; **Staining in tympanoplasty; Is Methylene blue Rationale?.** Glob J Oto.2015; 1(2):555557.
4. Y Yegin, ZM Yazici, M Celik, S Gunes, I Syin, FT Kayhan. **Comparison of temporalis muscle fascia and full thickness cartilage grafts in type 1 tympanoplasty.** Int J Clin Exp Med 2016; 9(5):8731-8736.

5. Kim MB, Park JA, Suh MJ, Song CI. **Comparison of clinical outcomes between butterfly inlay cartilage tympanoplasty and conventional underlay cartilage tympanoplasty.** *Auris Nasus Larynx.* 2019 Apr 1;46(2):167-71.
6. Balasubramanian T, Venkatesan U. **Endoscopic otology a supplement.** *Otolaryngology.* 2012;2:1-25.
7. Malik SA. **Permeatal approach for tympanoplasty: Scar-less approach of external auditory canal integrity.** *JLUMHS.* 2014 May; 13(02):76.
8. Daneshi A, jahandide H, Daneshvar A, safdarian M. **Bilateral same-day endoscopic transcanal cartilage tympanoplasty: Initial results.** *Braz j Otorhinolaryngol.* 2017; 83: 411-5.
9. M S Gozeler and A K sahin. **Comparison of temporalis fascia and transcanal composite chondroperichondrial tympanoplasty techniques.** *Ear, Nose and throat Journal (2019)1-4* (<http://us.sagepub.com/en-us/nam/open-access-at-sage>).
10. Pal R, Surana P. **Comparative Study Between Microscopic and Endoscopic Tympanoplasty Type I.** *Indian Journal of Otolaryngology and Head & Neck Surgery.* 2019 Nov 1;71(2):1467-73.
11. M Karatas, S Dogan. **Inlay butterfly cartilage tympanoplasty for large central perforations;** *Eur Res J* 2017; 3(3): 259-263.
12. R Muzaffar, R Rafiq, S M Naik. **Endoscopic tympanoplasty and microscopic tympanoplasty: A comparative analysis.** *Int. Journal of Sci. and Res publications;* 2017 august. :7(8): 587-590.
13. Haldar A, Pervej M K. **Microscopic tympanoplasty versus endoscopic tympanoplasty; A comparative study in a tertiary care centre, West Bangal.** *J. Evid. Based Med. Health.* 2019; 6(7): 400-403.
14. J Huang, Z Li, KWu, W Wang. **Long term outcomes after performing tympanoplasty without mastoidectomy for active and inactive non choleostomous chronic otitis media.** August 2018. *J of ORL: Karger AG, Basel:*1-7.

AUTHORSHIP AND CONTRIBUTION DECLARATION

Sr. #	Author(s) Full Name	Contribution to the paper	Author(s) Signature
1	Tahir Hussain Khan	Performed surgical procedure under supervision of Professor Sohail A Malik. Thesis writing and did research.	
2	Humaira Tahir	She summarized data after signature of participants in study and helped in article writing.	
3	Imran Ali	Given General Anesthesia, formatting and editing article.	
4	Sohail Abdul Malik	Supervised the research.	