



A RARE CASE OF SPONTANEOUS SCROTAL ENTEROCUTANEOUS FISTULA AS A COMPLICATION OF INCARCERATED INGUINAL HERNIA WITH REVIEW OF LITERATURE.

1. MBBS, FCPS (General Surgery)
Post Graduate Resident
King Edward Medical University
Mayo Hospital Lahore.
2. MBBS, FCPS (General Surgery)
Senior Registrar General Surgery
King Edward Medical University
Lahore.
3. MBBS
Post Graduate Resident Pediatric
Surgery
King Edward Medical University
Mayo Hospital Lahore.

Correspondence Address:

Dr. Mohammad Sohail Asghar
House No. 170, New Nazimabad,
Faisalabad.
kdark7582@gmail.com

Article received on:

04/10/2019

Accepted for publication:

26/12/2019

Mohammad Sohail Asghar¹, Ahmad Kaleem², Sushil Rijal³

ABSTRACT... Inguinal hernias are one of the most common problems presenting in both adult and pediatric surgical departments. Normally hernia is easy to diagnose and manage. On the other hand if its presence is ignored and surgery is delayed, hernia related morbidity can increase significantly. In developing countries, these complications are seen more often as there is more ignorance, illiteracy, lack of health facilities. We present a rare case of entero cutaneous fistula in scrotum due to a complete indirect inguinal hernia incarceration. There have been very few such cases that have been like this and reported so far.

Key words: Enterocutaneous Fistula, Inguinal Hernia, Richter's Hernia.

Article Citation: Asghar MS, Kaleem A, Rijal S. A rare case of spontaneous scrotal enterocutaneous fistula as a complication of incarcerated inguinal hernia with review of literature. Professional Med J 2020; 27(7):1537-1540.
DOI: 10.29309/TPMJ/2020.27.07.4113

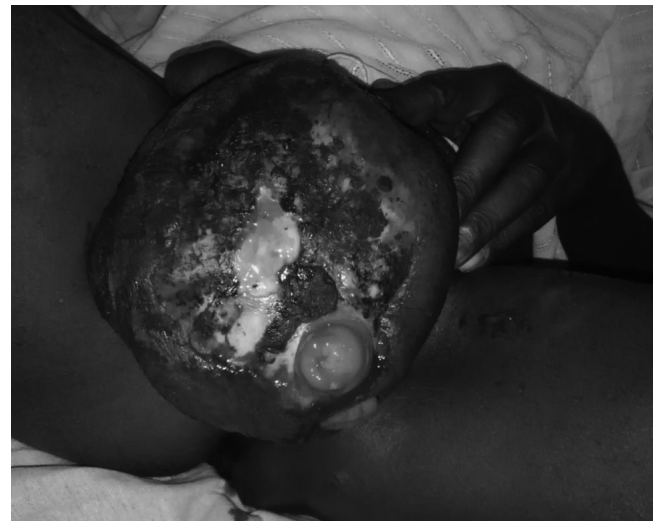INTRODUCTION

Inguinal hernias are one of the most common problems presenting in both adult and pediatric surgical departments. Normally hernia is easy to diagnose and manage. On the other hand if its presence is ignored and surgery is delayed, hernia related morbidity can increase significantly. Natural history of hernia, if not corrected at an earlier stage is from reducible to irreducible, incarcerated, obstructed, strangulated and then rarely fistula formation. Most of the spontaneous enterocutaneous fistulas in adults are formed by Richter's hernias but in inguinal hernias, this type of spontaneous fistula is rare. In developing countries, these complications are seen more often as there is more ignorance, illiteracy, lack of health facilities. We present a case of enterocutaneous fistula in scrotum due to a complete indirect inguinal hernia incarceration.

CASE

Our patient 60-year-old male presented to us in June 2019 when developed an inguinoscrotal swelling on left side 2 years back. It was initially reducible but he did not seek any medical help and ignored his complaint as it was not painful. Patient has history of lifting heavyweight at his

workplace. The swelling gradually increased in size but did not become painful until 4 months ago when it became irreducible. Patient took pain killers but did not undergo any surgery. After some days he developed excoriation on left side of scrotum and gut contents started coming out of it. Surprisingly patient did not get any surgical advice and he let this enterocutaneous fistula as it is. He had a dragging sensation in his scrotum in the start but after that he did not feel any pain. The main reason for consultation on surgical floor was skin excoriation in adjoining area of the scrotum.



On examination, his pulse was 70/min and regular, B.P 130.90 mm Hg, temperature 98.6 F and respiratory rate 18/ min. On abdominal examination there was no swelling, tenderness or previous scar marks. There was scrotal swelling on the left side. An opening of small gut on left side of scrotum was present with surrounding skin having blackish discoloration along with variable areas of necrotic tissue and fibrinous discharge possibly due to incarceration. On blood work his Hb=12.7 mg/dl, TLC =6700/microliter. His liver function tests and renal function tests were in normal limits.

He was admitted in surgical ward, initial resuscitation with IV antibiotics and fluids started. As the patient had a compromised cardiac reserve i.e ejection fraction 35 %, he was asked to be operated on high-risk consent. In spite of the fact that he was made aware of any imminent strangulation and peritonitis, the patient did not give high-risk consent to be operated under general anesthesia. So keeping in view his age, ease with which he was managing the fistula, decision was made to debride the local necrotic skin of the scrotum to reduce the septic load under local anesthesia and not to operate for the fistula. He was discharged from the surgical floor after debriding the adjoining necrotic skin.

DISCUSSION

Most of the hernias that usually make spontaneous or postoperative enterocutaneous fistulas, are Richter's hernia. Richter's hernia occurs in small hernia rings large enough to entrap the partial circumference of the bowel wall, but small enough to prevent protrusion of a loop of the intestine, with firm margins commonly occurring in the femoral ring (72 %-88 %), followed by inguinal canal (12-24 %) and the abdominal wall incisional hernias (4 %-25 %).¹ A Richter's hernia progresses more rapidly to gangrene due to constricting ring that exerts direct pressure on the bowel wall and hence compromised blood supply. When less than two-thirds of the circumference of the bowel wall is involved, the signs and symptoms of intestinal obstruction are absent. This leads to late diagnosis or even misdiagnosis, and thus it allows bowel necrosis to develop.² Any part of

intestine may get incarcerated but most commonly involves distal ileum, caecum, and sigmoid colon. As only a segment of bowel is involved, luminal continuity is maintained, thus there is only partial intestinal obstruction with minimal clinical signs.³ In 1598, Fabricius Hildanus⁴, reported the earliest known case of a Richter's hernia. Richter's hernia is named after the German surgeon, August Gottlieb Richter, who gave the first description of this type of hernia in 1778.² In 1956 Gillespie classified patients with Richter's hernia into three clinical groups according to the presentation of this disease.⁵ The obstructive group characterized by nausea, vomiting, peritonitis, and constipation which if untreated leads to shock. The second group was post necrotic group characterized by strangulation with necrosis and perforation causing enterocutaneous fistula. The third group was dangerous group which includes patients with minimal abdominal signs. This group has the maximum morbidity and mortality owing to delay in diagnosis.

Most of the enterocutaneous fistulas form as a consequence of the surgery.⁶ That is why the development of a spontaneous enterocutaneous fistula is very rare among adult patients having an inguinal hernia. Up till now only 5 cases of adult spontaneous enterocutaneous fistula in scrotum have been reported as presentation of inguinal hernia.⁷ Samad A presented a case from Pakistan in which a 25-year-old male presented with multiple enterocutaneous fistulas in the scrotum and suprapubic region which initially was an inguinoscrotal swelling but did not seek any surgical advice.⁸ Koshariya M presented a case in India where a middle-aged man presented with a neglected case of untreated incarcerated inguinal hernia and leading to fecal fistula.⁹ Similarly Puneet M and Rajamanickam reported two other cases of enterocutaneous fistula from India.^{10,6,7} Another adult case of scrotal enterocutaneous fistula was reported from Nigeria which indicated that these rare complications are seen most of the time in developing countries.¹¹ These were the cases of spontaneous scrotal enterocutaneous fistulas reported up till now in adults.

Klein AM reported a case in which a 15-year-old

male developed a scrotal enterocutaneous fistula after laparoscopic hernia repair.¹²

Most of the patients with strangulation hernia are hemodynamically unstable and if not intervened soon can cause the death of patients. Initially, there is accumulation of exudates in the coverings of the hernia. Afterward with the blood supply of hernia gut including the bowel wall gets compromised along with the edematous bowel walls. Compromised blood supply increases the edema and thus can cause perforation in the gut wall. Superimposed infection and necrosis spreads to subcutaneous tissues and then skin which in result causes an enterocutaneous fistula.¹³

Obstructed inguinal hernias which later on go on to the development of enterocutaneous fistulas may in start be painful but once the fistula has developed, it leads to decompression of gut and thus relieve from the pain. This is another reason for delayed presentation of such fistulas. But strangulation if not corrected in time may lead to other local and systemic complications like sepsis, Fournier gangrene and testicular necrosis.¹⁴ Therefore urgent release of strangulation along with resection of necrotic gut and skin is very important to save the patient's life.¹⁵

In our patient, there was a history of incarceration for 4 months before presentation with resultant enterocutaneous fistula formation. This probably occurred because of friction-related inflammatory response in scrotum with necrosis and consequent fistula formation. In fact, the fistula formed very early in the course which led to the temporary relief and the condition did not deteriorate to the sepsis. He was able to manage his fistula well but was concerned regarding the skin of the scrotum. Only one case of the above-reported ones was on left side like it was in our case, while the rest were on the right side. Orchidectomy was needed in one case only and rest were treated only debridement of scrotal skin. The main reason for such late presentation of inguinal hernia is lack of resources, delayed referral, and illiteracy which is also evident by thy presentation of such cases only in developing countries.

CONCLUSION

Inguinal hernias are easy to manage but if ignored their presence, which usually occurs due to lack of resources and information, can lead to complications like strangulation and very rarely fistula which significantly increases its morbidity and mortality.



Copyright© 26 Dec, 2019.

REFERENCES

1. Ahi K, Moudgil A, Aggarwal K, Sharma C, Singh K. **A rare case of spontaneous inguinal fecal fistula as a complication of incarcerated Richter's hernia with brief review of literature.** BMC Surgery. 2015; 15.
2. Habib Faridi S, Siddiqui B, Amanullah Khan M, Anees A, Ali SA. **Suprapubic fecal fistula due to richter's inguinal hernia: A case report and review of literature.** Iran J Med Sci. 2013; 38(2):129-31.
3. Elenwo SN, Igwe PO, Jamabo RS, Sonye US. **Spontaneous entero-labial fistula complicating Richters hernia: Report of a case.** Int J Surg Case Rep. 2016; 20:27-9.
4. Steinke W, Zellweger R. **Richter's hernia and Sir Frederick Treves: An original clinical experience, review, and historical overview.** Annals of surgery. 2000; 232(5):710-8.
5. Gillespie RW, Glas WW, Mertz GH, Musselman MM. **Richter 's Hernia hernia: Its Etiology, Recognition, and Management.** JAMA Surgery. 1956; 73(4):590-4.
6. Ahi KS, Moudgil A, Aggarwal K, Sharma C, Singh K. **A rare case of spontaneous inguinal fecal fistula as a complication of incarcerated Richter's hernia with brief review of literature.** BMC Surg. 2015; 15:67-.
7. Malik P, Rathu M, Kumar K, Sharma R, Meena P, Arya A, et al. **Scrotal enterocutaneous fistula: A rare initial presentation of inguinal hernia.** J Surg Case Rep. 2014; 2014(6):rju056.
8. Samad A, Sheikh GM. **Spontaneous fecal fistula: A rare presentation of inguinal hernia.** Journal of Ayub Medical College, Abbottabad: JAMC. 2005; 17(4):77-9.
9. Koshariya M, Naik S, Rai A. **Incarcerated inguinal hernia presenting as spontaneous scrotal fecal fistula. Hernia: the journal of hernias and abdominal wall surgery.** 2006; 10(5):434-5.
10. Rajamanickam S, Yadav A, Rai A, Singh D, Sonkar A. **A complicated true sliding hernia presenting as a spontaneous enteroscrotal fistula in an adult.** Journal of Emergencies, Trauma, and Shock. 2010; 3(1):62-5.

11. Nwabunike TO. **Enterocutaneous fistulas in Enugu, Nigeria. Diseases of the colon and rectum.** 1984; 27(8):542-4.
12. Klein AM, Banever TC. **Enterocutaneous fistula as a postoperative complication of laparoscopic inguinal hernia repair.** Surgical laparoscopy & endoscopy. 1999; 9(1):60-2.
13. Friedman A. **Strangulated femoral hernia complicated by fecal fistula.** MJ and Rec. 1931; 134:537-8.
14. Gupta D, Rohatgi M. **Inguinal hernia in children: An Indian experience.** Pediatric surgery international. 1993;8(6):466-8.
15. Malik P, Rath M, Kumar K, Sharma R, Meena P, Arya A, et al. **Scrotal enterocutaneous fistula: A rare initial presentation of inguinal hernia.** J Surg Case Rep. 2014; 2014(6).

AUTHORSHIP AND CONTRIBUTION DECLARATION

Sr. #	Author(s) Full Name	Contribution to the paper	Author(s) Signature
1	M. Sohail Asghar	Literature search, interpretation of data composing of draft of article and final proof reading.	
2	Ahmad Kaleem	Operatiang surgeon, Literature search and review final proof reading of the article and composing.	
3	Sushil Rijal	Reference writing and final proof reading of article.	