



HISTOPATHOLOGICAL ANALYSIS OF APPENDECTOMY SPECIMENS IN A TERTIARY CARE HOSPITAL; A DESCRIPTIVE STUDY.

1. MBBS, MRCS, FCPS
Post Graduate Trainee Surgical Unit 1
Holy Family Hospital Rawalpindi.
2. MBBS, FCPS
Assistant Professor Surgical Unit 1
Holy Family Hospital Rawalpindi
3. MBBS
House Officer Surgical Unit 2
Benazir Bhutto Hospital Rawalpindi.
4. MBBS, FCPS
Post Graduate Trainee Surgical Unit 1
Holy Family Hospital Rawalpindi.
5. MBBS, MRCPCH
Post Graduate Trainee Paediatric
Medicine
Fauji Foundation Hospital
Rawalpindi.
6. MBBS
House Officer Surgical Unit 1
Holy Family Hospital Rawalpindi.

Correspondence Address:

Dr. Ahmed Mujtaba Malik
Department of Surgical Unit 1
Holy Family Hospital Rawalpindi.
ahmedckoolmalik98@gmail.com

Article received on:

23/09/2019

Accepted for publication:

21/12/2019

Ahmed Mujtaba Malik¹, Gohar Rasheed², Tooba Mazhar³, Sara Malik⁴, Maariah Asif⁵, Ali Hafeez⁶

ABSTRACT... Objectives: To analyse the pattern and morphologies of all the surgically resected appendices in the surgical emergency of holy family hospital in relation to gender, age and the percentage of negative appendectomies. **Study Design:** Descriptive Cross Sectional study. **Setting:** Surgical Unit 1 Holy Family Hospital, Rawalpindi. **Period:** January 2013 to April 2019. **Material & Methods:** 1993 patients (1011 males, 982 females) which underwent appendectomy were included in this study. Structured proforma was made. All the specimens were sent to pathology lab for histopathology. Detailed histopathological report was received in the OPD follow-up of the patient. All the data was analysed using SPSS version 22. **Results:** Acute appendicitis (57.3%) was the most common morphology followed by suppurative appendicitis (11.1%). One case was carcinoid tumour (0.05%). The incidence of negative appendectomy was 8.42% while the incidence of perforated appendix was 3.5%. **Conclusion:** Appendicitis is one of the most common surgical Emergency and histopathology is gold standard in definitive diagnosis.

Key words: Appendix, Appendectomy, Appendicitis, Histopathology, Surgical Emergency.

Article Citation: Malik AM, Rasheed G, Mazhar T, Malik S, Asif M, Hafeez A. Histopathological analysis of appendectomy specimens in a tertiary care hospital; a descriptive study. Professional Med J 2020; 27(8):1570-1574.
DOI: 10.29309/TPMJ/2020.27.08.4189

INTRODUCTION

Appendix is part of the gastrointestinal tract and is known to be as a true diverticulum of cecum and is prone to inflammation; both acute and chronic. The diagnosis of the appendicitis is often difficult pre-operatively due to its location the common differential diagnosis come out to be mesenteric lymphadenitis, acute salpingitis, ectopic pregnancy, mittelschmerz syndrome and Meckel diverticulitis.¹

Surgical acute abdomen is a common presentation in emergency settings of a tertiary care hospital and among the most common causes is acute appendicitis. It is a disease of all age groups with a total life time risk of 8.6%. And 6.7% among males and females respectively the incidence of disease varies from region to region and is usually 110-140 per 100,000 population. Males are slightly more prone to develop the disease.^{2,3}

Pathologists have come to a conclusion that in about 50 to 80 percent increased intramural pressure leads to venous congestion of the organ and there by resulting in acute appendicitis, however after inflammation has occurred there is sequela of events that result in different morphologies of appendix. Appendicitis may occur due to obstruction by worms, fecolith or gall stones. Stasis of the intra-luminal contents causes bacterial proliferation and thereby favouring ischemia and inflammatory response resulting in the both microscopic and macroscopic changes i.e edema, neutrophilic infiltration and loss of the glistening serosa into dull, granular, erythematous surface. If the inflammatory response continues localized abscesses form in the wall of the appendix leading to the formation of the acute suppurative appendicitis, further inflammation causes ulceration and necrosis of the wall and hence causing gangrenous and perforated appendicitis leading to peritonitis; a life threatening emergency.^{1,2,3}

Carcinoid tumor is the most common tumor of appendix. It is neuro-endocrine in nature. It is almost always benign and nodal metastasis is very infrequent. It may cause obstruction of the lumen of the appendix and hence mimic the presentation of acute appendicitis.¹

Patient typically presents with peri-umbilical pain shifting to right iliac fossa, nausea, vomiting, fever, anorexia, tenderness and rebound tenderness in the right iliac fossa with leucocytes and neutrophils raised. Radiological investigation of choice is spiral CT scan provide substantial evidence for a provisional diagnosis of acute appendicitis however such a challenging diagnosis may lead to negative appendectomy, therefore histopathology remains the gold standard in diagnosing and confirming the disease.⁵

This study aims to analyse the pattern and morphologies of all the surgically resected appendices in the surgical emergency of holy family hospital in relation to gender, age and the percentage of negative appendectomies done in this setting.

The rationale of our study is that hospital administrations, surgeons and histopathologists will have a reference of our regional pattern of histopathology of appendix specimens. This will be an addition to the already present literature and will open gateways for future research in the pathogenesis of the specific type of appendicitis.

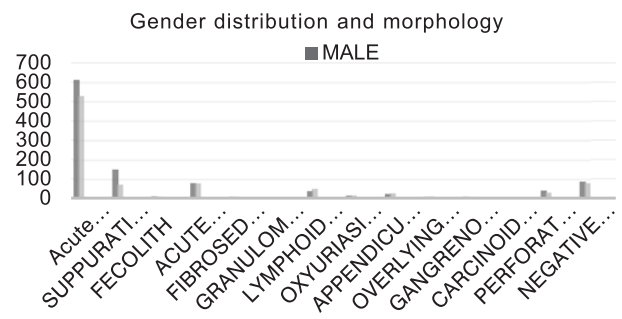
MATERIAL & METHODS

1993 patients were included in this descriptive cross-sectional study conducted in surgical unit 1 from January 2013 to April 2019. All the operated cases of appendicitis whether emergency, elective or incidental were included in this study. Structured Performa consisting of patient's demographic profile, clinical examination and per-operative findings were provided to the pathology department. All the specimens sent for histopathology were fixed in 10% formalin solution and sent to pathology department within 12 hours of surgery. Detailed report of histopathology was received from pathology department when the patient came for follow up in outdoor department

of surgical unit 1. Histopathology report included gross as well as microscopic examination of the specimens. Data was analysed using spss version 22.0.

RESULTS

Out of the total 1993 specimens, 1011 (50.7%) were male and 982 (49.3%) were female with the mean age of 22.76 Years \pm 12.53 years, mode 17 years and median was 21.50 years. The youngest being 5 years of age and oldest being 78 yrs old.



DISCUSSION

The incidence of acute appendicitis has risen in the past few decades particularly in Europe, America and Australasia with upto 16% of population undergoing appendectomy in some part of their lives. Acute appendicitis is rare among neonates and infants however the incidence increases with age with peak incidence among teens and young adults. The incidence decreases after the middle age.⁶

The mean age of the patients presenting in our study is 22.76 Years \pm 12.53 years where more than 80 % patient were less than 40 years of age. The male to female ratio in our study was comparative to other studies i.e male predominance 3:2 at age 25.^{5,6,7,8,9}

Acute appendicitis was the most common histopathological diagnosis accounting for 57.3% followed by acute suppurative appendicitis 11.1%, this is comparative to the study done by Zulfikar et al.¹⁰

	2013	2014	2015	2016	2017	2018	2019	Total	%Age
Acute appendicitis	113	178	95	314	191	225	27	1143	57.30%
Suppurative appendicitis	15	21	9	34	64	54	25	222	11.1%
Fecolith	10	7	-	-	-	-	-	17	0.8%
Acute appendicitis with periappendicitis	29	84	3	-	-	15	27	158	7.92%
Fibrosed appendix	7	3	-	1	-	3	-	14	0.72%
Granulomatous	3	-	-	-	-	-	-	3	0.15%
Lymphoid hyperplasia	3	4	-	3	42	32	4	88	4.41%
Oxyuriasis/parasitic infestation	4	3	-	10	1	11	2	31	1.5%
Appendicular abscess	-	4	4	31	8	3	1	51	2.5%
Overlying peritonitis (suppurative + periappendicitis)	-	9	6	-	-	-	-	15	0.75%
Gangrenous	-	-	-	1	-	9	1	11	0.55%
Carcinoid tumor	-	-	-	1	-	-	-	1	0.05%
Perforated appendix	4	11	15	9	21	7	4	71	3.5%
Negative appendectomies	22	25	28	32	21	27	13	168	8.42%
Total	210	349	160	436	348	386	104		
Grand total								1993	

Table-I. Histopathological analysis of all the specimens of appendix.

Fibrosing/resolving appendicitis and granulomatous appendicitis were 0.85 % which is very much comparative to the study done by Park et al where they found it to be 1%.¹¹ The diagnosis of chronic resolving/ fibrosing appendicitis and granulomatous appendicitis is questionable and its existence is debatable.

The rate of perforation of appendix was slightly higher 3.5% as comparison to the studies conducted elsewhere and less as compare to some of the other studies, however the rate of perforation in extreme of ages was similar to other studies conducted. Worldwide the rate of perforation is affected by the duration of symptoms, age, gender and race of the patients so its highly variable in geographical distribution.^{12,13}

Parasitic infestation is one of the causes that lead to the luminal obstruction of the appendix and hence appendicitis. Its not a very uncommon cause, the rate of parasitic infection also known as oxyuriasis was 1.5% in our study. It is comparative to the other studies conducted in different geographical regions of the world where the rate is about 0.3 to 3.15%.^{13,14,15} The Organism isolated from all our specimens was Enterobius

Vermicularis. All of the specimens in this category had eosinophilic infiltration and granulomatous changes.

Carcinoid tumor was only found to be in 1 case only (0.05%) this is comparative to the other studies conducted.^{15,16,17} In our study the patient did not present with the typical symptoms of acute appendicitis but presented with classic symptoms of carcinoid tumor and on investigation the tumor was found to be at the tip of appendix and was localized and hence only appendectomy was done.

In our study the rate negative appendectomies came out to be 8.42% which is a globally acceptable. The acceptable incidence of negative appendectomies is said to be between 10 to 20 % depending upon the geographical location, age and gender. Various studies show a rate of 6.1% to 34.2% with rate being higher among female patients. These negative appendectomies may be avoided if a short term course of antibiotics is given to the patients and the level of inflammation may be monitored with clinical symptoms and laboratory investigations.^{17,18,19,20}

Our study was very extensive in differentiating the different types of appendicitis and therefore many of our subtypes couldn't be compared with local, regional or international publications. Our limitations were that we did not correlate our study with the duration of symptoms of the patient which has a key role in the ultimate histopathology and the surgeon and histopathologist were not same in all cases.

CONCLUSION






Acute appendicitis is the most common morphology followed by the acute suppurative appendicitis. Incidence of negative appendectomy was in correlation to the internationally acceptable range, this incidence should be lowered using advanced radiological investigations and diagnostic laparoscopy. Our study may be used as a regional reference for prevalence of different types of appendicitis.

Copyright© 21 Dec, 2019.

REFERENCES

1. F. Brunicardi, Dana Andersen, Timothy Billiar, David Dunn, John G. Hunter, Jeffrey Matthews, Raphael E. Pollock. **Schwartz's principles of surgery**, 10th edition. New York USA: McGraw-Hill; 2014.
2. Cartwright SL, Knudson MP. **Evaluation of acute abdominal pain in adults**. Am Fam Physician. 2008 Apr 1; 77(7):971-8.
3. Körner H, Söndena K, Söreide J, Andersen E, Nysted A, Lende T et al. **Incidence of acute non perforated and perforated appendicitis: Age-specific and sex-specific analysis**. World Journal of Surgery. 1997; 21(3):313-7.
4. Oguntola AS, Adeoti ML, Oyemolade TA. **Appendicitis: Trends in incidence, age, sex, and seasonal variations in South-Western Nigeria**. Ann Afr Med 2010; 9:213-7.
5. Alvarado A. **A practical score for the early diagnosis of acute appendicitis**. Ann Emerg Med. 1986 May; 15(5):557-64.
6. Liu CD, McFadden DW. **Acute abdomen and appendix, in Surgery: Scientific Principles and Practice, 2nd edition**. Philadelphia USA: Lippincott-Raven; 1997
7. Oguntola AS, Adeoti ML, Oyemolade TA. **Appendicitis: Trends in incidence, age, sex, and seasonal variations in South-Western Nigeria**. Ann Afr Med 2010; 9:213-7.
8. Edino ST, Mohammed AZ, Ochicha O, Anumah M. **Appendicitis in Kano, Nigeria: A 5 year review of pattern, morbidity and mortality**. Ann Afr Med 2004; 3:38-41.
9. Noudeh YJ, Sadigh N, Ahmadnia AY. **Epidemiologic features, seasonal variations and false positive rate of acute appendicitis in Shahr-e-Rey, Tehran**. Int J Surg 2007; 5:95-8.
10. Nabipour F. **Histopathological feature of acute appendicitis in Kerman-Iran from 1997 to 2003**. Am J Env Sci 2005; 1:130-2.
11. Zulfikar I, Khanzada TW, Sushel C, Samad A. **Review of the pathologic diagnoses of appendectomy specimens**. Ann King Edward Med Univ 2009;15:168-70
12. Park CS, Chang MS, Park IA, Kim YI, Choe G. **Pathologic analysis of 2159 cases of appendix**. Korean J Pathol 2000; 34:39-49.
13. Omari AH, Khammash MR, Qasaimeh GR, Shammari AK, Yaseen MK, Hammori SK. **Acute appendicitis in the elderly: Risk factors for perforation**. World J Emerg Surg. 2014 Jan 15; 9(1):6
14. Marudanayagam R, Williams GT, Rees BI. **Review of the pathological results of 2660 appendectomy specimens**. J Gastroenterol 2006; 41:745-9.
15. Aydin O. **Incidental parasitic infestations in surgically removed appendices: A retrospective analysis**. Diagn Pathol 2007; 2:16.
16. Duzgun AP, Moran M, Uzun S et al. **Unusual findings in appendectomy specimens: Evaluation of 2458 cases and review of the literature**. Indian J Surg 2004; 66:221-6.
17. Ojo OS, Udeh SC, Odesanmi WO. **Review of the histopathological findings in appendices removed for acute appendicitis in Nigerians**. JR Coll Surg Edinb 1991; 36:245-8.
18. Jones AE, Phillips AW, Jarvis JR, Sargen K. **The value of routine histopathological examination of appendectomy specimens**. BMC Surg 2007; 10:7.
19. Amulic B, Cazalet C, Hayes GL, et al. **Neutrophil function: From mechanism of disease**. Annu Rev Immunol. 2012; 30:459-89.
20. Fitzmaurice GJ, McWilliams B, Hurreiz H, Epanomeritakis E. **Antibiotics versus appendectomy in the management of acute appendicitis: A review of the current evidence**. Can J Surg 2011 Oct; 54(5):307-14.

AUTHORSHIP AND CONTRIBUTION DECLARATION

Sr. #	Author(s) Full Name	Contribution to the paper	Author(s) Signature
1	Ahmed Mujtaba Malik	Idea, Concept.	
2	Gohar Rasheed	Mentor, Guidance.	
3	Tooba Mazhar	Article writing.	
4	Sara Malik	Data analysis.	
5	Maariah Asif	Results discussion.	
6	Ali Hafeez	Data collection.	