



## COMPARISON OF BRACKA I VERSUS BLAIR-BYAR'S TECHNIQUE IN CHORDEE CORRECTION.

Masood Mahmood<sup>1</sup>, Imran Qadir<sup>2</sup>, Sadaqat Ali<sup>3</sup>, Muhammad Sarfraz Khan<sup>4</sup>

1. MBBS  
Medical Officer Paediatric Urology  
Children Hospital, Faisalabad.
2. MD, FCPS  
Senior Registrar & Head Paediatric  
Urology  
Children Hospital, Faisalabad.
3. MBBS, FCPS  
Senior Registrar Paediatric Surgery  
Children Hospital, Faisalabad.
4. MBBS, FCPS  
Senior Registrar Paediatric Urology  
Children Hospital, Faisalabad.

**Correspondence Address:**

Dr. Masood Mahmood  
Department of Paediatric Urology  
Children Hospital, Faisalabad.  
drimranqadir@yahoo.com

**Article received on:**

17/09/2019

**Accepted for publication:**

11/11/2019

**ABSTRACT...** To compare the outcome of the Bracka I Graft Technique versus Blair-Byar's Flap technique in orthoplasty for urethral plate in terms of procedure time, hospital stay and urine stream after removal of Foley catheter. **Study Design:** Randomized Control Trial study. **Setting:** Pediatric Urology Department, Children Hospital Faisalabad (CHF). **Period:** 1 year and 9 months, from April 2016 to December 2018. **Material & Methods:** Total 80 patients were taken with Non probability consecutive sampling technique was adopted with inclusion criteria with more than 2 years of age and hypospadias with chordee while, exclusion criteria of patients were previous surgery of chordee correction and any other associated anomalies. **Results:** In the patients with Bracka I procedure, n=37 patients (92.5%) have uneventful uptake of graft, where two (5%) patients have failure of uptake of graft while one (2.5%) of them had wound infection and adequate urinary stream after removal of Foley was found in all 40 patients. In Blair-Byar's technique procedure had uneventful uptake of graft in n= 36 patients (90%) where two (5%) patients have failure of uptake of graft while two (5%) of them have wound infection. Cosmetically acceptance was in 39 patients (97.5%) by the parents and feasibility to do the second stage. While among Blair-Byar's technique cosmetically acceptance was in 35 patients (87.5%) by the parents and feasibility to do the second stage. **Conclusion:** Bracka I (graft) Orthoplasty and Blair-Byar's (flap) Orthoplasty has equivocal results in terms of tissue uptake and uneventful recovery, urinary stream post operatively, post-operative meatal diameter while cosmetically Bracka I is superior to Blair-Byar's technique while feasibility of the availability of local tissue to make tube for urethroplasty in stage II.

**Key words:** Blair-Byar's Technique, Bracka1 Technique, Chordee Correction, Orthoplasty, 1<sup>st</sup> Stages of Urethroplasty.

**Article Citation:** Mahmood M, Qadir I, Ali S, Khan MS. Comparison of bracka I versus blair-byar's technique in chordee correction. Professional Med J 2020; 27(7):1420-1423. DOI: 10.29309/TPMJ/2020.27.07.4168

### INTRODUCTION

Hypospadias is one of the most common congenital defects of male external genitalia, occurring in approximately 1 in 250 live male newborn of which proximal hypospadias (penoscrotal, scrotal, and perineal types) account for 20% of all cases.<sup>1</sup> It is a significant surgical challenge to achieve a cosmetically and functionally acceptable straight penis in such patients. Single-stage procedures are often associated with complications and reoperations, which negate the purpose of single-stage procedure. Contemporary series of -single-stage repair report complication rates of 20-50%.<sup>2,3,4</sup> Reconstruction of severe hypospadias using two-staged techniques is associated with an overall

lower rate of complications, about 2.5–6% as reported in the literature.<sup>5,6</sup> The debate over the optimal treatment for severe cases of hypospadias is ongoing, and many surgeons believe that two-stage procedure offers superior functional and cosmetic results with fewer complications.<sup>7</sup> Bracka, using his two-stage principle of repair, published his results of first 600 cases in 1995.<sup>8</sup> Bracka is a two-stage procedure: The first stage of Bracka repair consists of orthoplasty and urethral bed substitution with free preputial graft. After 6 months, the urethral plate created from free graft is tabularized to form neourethra. Two-stage repairs reduce the complications and create better cosmetic view. Hypospadias repair has a number of correction technique, and there

are multiple studies, where these techniques are compared each other like in a study by Sadeghi<sup>9</sup>, where he compared outcomes of Duckett's one-stage technique with modified Bracka's two-stage procedure.

There are multiple types of procedure to correct the chordee in hypospadias with chordee cases we planned to perform study to discuss the differences between Bracka I where Graft is used for the plate of urethra and Blair-Byar's Flap technique in term of procedure time hospital stay and urine stream after removal of Foley Catheter.

To compare the outcome of the Bracka I Technique and Blair-Byar's Flap technique in orthoplasty for urethral plate in terms of procedure time hospital stay and urine stream after removal of Foley catheter.

## **MATERIAL & METHODS**

Total 80 patients were taken with randomized control trial study design in the Pediatric Urology Department, Children Hospital Faisalabad (CHF). With duration of 1 year and 9 months, from April 2016 to December 2018. Non probability consecutive sampling technique was adopted.

Inclusion criteria of the patients for study were; the Patients with hypospadias with chordee, Patient more than 2 Years of age and Patients with ventral chordee more than 30 degree angle, which will be confirmed by physical examination.

Exclusion criteria of the patients for study were; Patients with previous surgery for chordee correction, Patients with other urogenital anomalies like undescended testis, inguinal hernia, hydrocele, Patients with small sized penis.

Two types of management of ventral chordee correction in case of hypospadias with chordee were chosen where first (Group A) method was orthoplasty with Bracka I technique<sup>9</sup> where chordee correction done by removing the scared tissue on the ventral side and preputial graft was taken and applied on the ventral deficient skin area and while in second (Group B) method Orthoplasty with Blair-Byar's flap technique where

after straightening of penis ventral deficient area was covered by a dorsal flap of prepuce was raised and incised into two halves at twelve 0 clock level and both portions crossed over on ventral side with Z-plasty technique known as Blair-Byar's technique.<sup>10</sup>

Outcome of the comparison of both studies was measured in terms of procedure time, hospital stay, soft tissue infection, meatal stenosis, postoperative cosmetic results and urine stream after removal of Foley catheter.

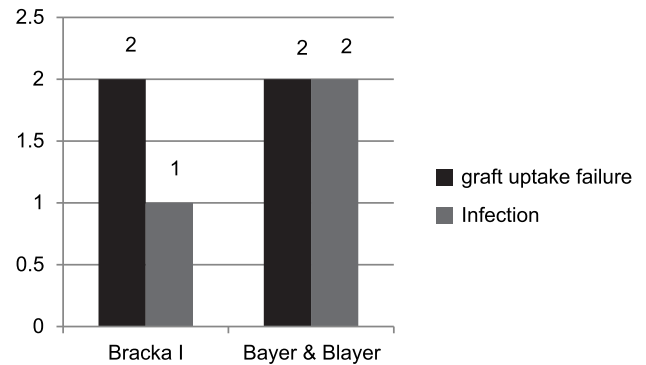
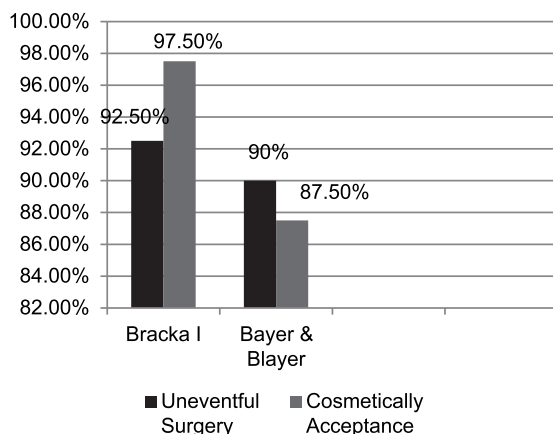
After the approval of the research proposal from the "Hospital Ethical Committee", as per inclusion and exclusion criteria all consecutive patients were included in study in the Department of Urology, Children hospital Faisalabad from the Outdoor Patient Department of the Hospital who were admitted in the indoor department for research. Informed consent was taken from all the patients for procedures, all investigations to do study and the use of data for research purpose.

Total 80 male patients were taken for study. This included with age ranging from 2 to 14 years (with mean age: 7.65 and SD:  $\pm 2.15$ ). All patients were divided into two groups by computer generated random number table. Group A (n=40, 50%) were proceeded Bracka I technique for orthoplasty, where preputial graft was used on ventral side of penis after removing the scar and straightening of penis to cover the deficient area of penis while group B (n=40, 50%) were proceeded Blair-Byar's technique where dorsal preputial skin was used as flap rotated anteriorly to cover the ventral aspect of the penis after removing the scar and straightening of the penis. After surgery all patients were observed in the indoor department for 10 days and discharged on 10<sup>th</sup> post operative day and advised the revisit on the 21<sup>st</sup> post operative day. Outcomes of chordee correction was measured that is soft tissue infection or meatal stenosis. Outcome of the comparison of both studies was measured in terms of procedure time hospital stay, postoperative cosmetic results and urine stream after removal of Foley catheter. Data was entered on a Proforma, attached herewith, by me accordingly. Independent t-test

was applied.

## RESULTS

On the 10<sup>th</sup> post-operative day, patients belong to Group A, who were treated with Bracka 1 procedure had uneventful uptake of graft n=37 patients (92.5%) where two (5%) patients had failure of uptake of graft while one (2.5%) of them had wound infection and adequate urinary stream after removal of Foley was found in all 40 patients. While among Group B patients, who were treated with the Blair-Byar's technique procedure had uneventful uptake of flap were n=36 patients (90%) where two (5%) patients had failure of uptake of flap while two (5%) of them had wound infection and adequate urinary stream after removal of Foley was found in all 40 patients. On the 21<sup>st</sup> post operative day Group A patients who were treated with BRACKA 1 procedure had been corrected chordee and no meatal stenosis was found in all 40 patients. Cosmetically acceptance was in 39 patients (97.5%) by the parents and feasibility to do the second stage i.e. urethroplasty, and 36 patient (90%) have excellent tissue anatomy. While among Group B patients, who were treated with the Blair-Byar's technique procedure had been corrected chordee and no meatal stenosis was found in all 40 patients. Cosmetically acceptance was in 35 patients (87.5%) by the parents and feasibility to do the second stage i.e. urethroplasty, and 33 patients (82.5%) have excellent tissue anatomy.



## DISCUSSION

In the Department of Paediatric Urology Children Hospital Faisalabad, two staged Hypospadias repair is the only choice where two methods were adopted for Orthoplasty when Bracka 1 and Blair-Byar's with comparison of other researches Joshi<sup>1</sup> had results in his study where Bracka 1 was proceeded and 10 out of 43 patients (23.25 %) had graft contraction and uneven scarring was found in 3 patients out of 43 (6.97%).

In another study by Faustin Felicien used Bracka 1 in 12 patients where he found 3 patients with complication which are (25%).<sup>11</sup> Sakr<sup>12</sup> had researched that in Bracka 1 he found graft swelling in 6 patients (26.9%) skin echimosi n=2 (12.5%) and graft loss was two (12.5%), while in our study wound infection in Bracka 1 was (2.5%) and in Blair-Byar's it was (5%). Sadegi<sup>9</sup> studied Bracka compared with Duckett and declared Bracka has less complication versus with Duckett; 8.1% in Bracka and 26.9% in the Duckett, while in our study uneventful surgery was in Bracka I was (92.5%) and in Blair-Byar's it was (90%). Catti<sup>13</sup> studied that Bracka has better cosmetic results as compare to Cloutiers technique, while in our study cosmetic acceptance in Bracka I was (97.5%) while in Blair-Byar's (87.5%).

## CONCLUSION

Bracka I (graft) orthoplasty and Blair-Byar's (flap) orthoplasty has equivocal results in terms of tissue uptake uneventful recovery, urinary stream post operatively, post-operative meatal diameter while cosmetically Bracka I is superior to Blair-Byar's technique while feasibility of the availability of local tissue to make tube for urethroplasty in




stage II.

Copyright© 11 Nov, 2019.

## REFERENCES

- Joshi RS, Bachani MK, Uttarwar AM, Ramji JI. **The Bracka two-stage repair for severe proximal hypospadias: A single center experience.** J Indian Assoc Pediatr Surg. 2015 Apr-Jun; 20(2):72-6.
- Glassberg KI, Hansbrough F, Horowitz M. **The Koyanagi-Nonomura 1-stage bucket repair of severe hypospadias with and without penoscrotal transposition.** J Urol. 1998;160(3Pt2):1104-7
- Demirbilek S, Kanmaz T, Aydin G, Yucesan S. **Outcomes of one-stage techniques for proximal hypospadias repair.** Urology 2001 Aug; 58(2):267-70
- Castañón M, Muñoz E, Carrasco R, Rodó J, Morales L. **Treatment of proximal hypospadias with a tubularized island flap urethroplasty and the only technique: A comparative study.** J Pediatr Surg. 2000 Oct; 35(10):1453-5.
- Subramaniam R, Spinoit AF, Hoebeke P. **Hypospadias repair: An overview of the actual techniques.** Semin Plast Surg. 2011 Aug; 25(3):206-12.
- Zheng DC, Yao HJ, Cai ZK, Da J, Chen Q, Chen YB, et al. **Two-stage urethroplasty is a better choice for proximal hypospadias with severe chordee after urethral plate transection: A single-center experience.** Asian J Androl. 2015 Jan-Feb; 17(1):94-7.
- Gershbaum MD, Stock JA, Hanna MK. **A case for 2-stage repair of perineoscrotal hypospadias with severe chordee.** J Urol. 2002 Oct; 168(4Pt2):1727-8.
- Bracka A. **A versatile two-stage hypospadias repair.** Br J Plast Surg. 1995; 48(6):345-52.
- Sadeghi A, Mirshemirani A, Tabari AK et al. **Duckett versus modified Bracka technique for proximal hypospadias repair A 10-year experience.** Iran J Pediatr. 2017 December; 27(6):e7752
- Blair VP, Byars LT. **Hypospadias and epispadias.** J Urol. 1938; 40:814.
- Faustin Felicien MT Nwahmakon AS et al. **Our experience of proximal hypospadias repair using Cloutier-Bracka technique at gynaeco-obstetric and paediatric Hospital, Yaounde-Cameroon.** Afr J Paediatr Surg. 2016;13(4):193-195.
- Sakr A, Elkady E, Abdalla M et al. **Lingual mucosal graft two-stage Bracka technique for redo hypospadias repair.** Arab J Urol. 2017 Sep; 15(3): 236-241.
- Catti M, Demede D, et al. **Management of severe hypospadias.** Indian J Urol. 2008 Apr-Jun; 24(2): 233-240.

## AUTHORSHIP AND CONTRIBUTION DECLARATION

Sr. #	Author(s) Full Name	Contribution to the paper	Author(s) Signature
1	Masood Mahmood	Introduction, Data collection, Result preparation.	
2	Imran Qadir	Material and methodology surgical procedures, Result formation.	
3	Sadaqat Ali	Surgical procedure, Discussion and comparison with other.	
4	M. Sarfraz Khan	Abstract writing conclusion, Discussion.	