



1. MBBS, MS (Urology)
Associate Professor
DHQ Teaching Hospital Gujranwala/
Gujranwala Medical College,
Gujranwala.
2. MBBS, MS (Urology)
Assistant Professor
DHQ Teaching Hospital Gujranwala/
Gujranwala Medical College,
Gujranwala.
3. BSc, MBBS
Postgraduate Resident FCPS
Urology
DHQ Teaching Hospital Gujranwala/
Gujranwala Medical College,
Gujranwala.
4. MBBS
Post Graduate Resident MS Urology
DHQ Teaching Hospital Gujranwala/
Gujranwala Medical College,
Gujranwala.
5. MBBS
Medical Officer Urology
DHQ Teaching Hospital Gujranwala/
Gujranwala Medical College,
Gujranwala.
6. MBBS, MS (Urology)
Professor
DHQ Teaching Hospital Gujranwala/
Gujranwala Medical College,
Gujranwala.

Correspondence Address:

Dr. Khalid Hussain
DHQ Teaching Hospital Gujranwala/
Gujranwala Medical College,
Gujranwala.

Article received on:

09/03/2019

Accepted for publication:

25/07/2019

INTRODUCTION

Ureterorenoscopy (URS) is considered a less invasive approach with few side effects and with better results.¹⁻² To facilitate the endoscopic management of ureteric stones, stone removal devices and intracorporeal lithotripsy have been created. It is considered 1st interventional option for the management of ureteric stones. Many new innovations have made this endoscopic approach more valuable in treating ureteric stones. There are many types of energy sources which are used e.g. pneumatic, ultrasonic and laser lithotripter. With the help of these endoscopic modalities about 95% stone free results are achieved in many studies done at many higher specialized centres.³⁻⁴

During pneumatic lithotripsy retrograde Retropulsion of stone fragments is a challenging

INCIDENCE OF STONE RETROPULSION IN URETEROSCOPIC PNEUMATIC LITHOTRIPSY FOR LOWER URETERIC STONES BY USING STONE CONE.

Khalid Hussain¹, Attiq-ur-Rehman Khan², Rao Nouman Ali³, Maria Tariq⁴, Salman Shahid⁵, Muhammad Khalid Butt⁶

ABSTRACT... Objectives: To measure the incidence of stone Retropulsion and its complication in ureteroscopic pneumatic lithotripsy for lower ureteric stones by using stone cone. **Study Design:** Observational cross sectional study. **Setting:** Department of Urology, Teaching DHQ Hospital Gujranwala / Gujranwala Medical College, Gujranwala. **Period:** January 2017 to December 2018. **Material & Methods:** Consecutive simple random sampling technique was used. Total 120 patients were treated with URS pneumatic lithotripsy for single ureteric stone were enrolled in study. The diagnosis was established by plain spiral CT scan in all patients. The incidence of stone Retropulsion and complications of procedure were noted. Data was analyzed using SPSS 22.0, chi square test was used to check stratification of data, p value less than 0.05 was taken significant. **Results:** The stone was in lower ureter in all patients who were included in study regardless of side. The mean age of patients was 46±2.6 years and 65% (78) patients were male while 35% (42) patients were females. Success rate of 97.5% (116) achieved in patients in which stone cone was used. **Conclusion:** Use of stone cone gives high success rate in preventing stone Retropulsion by using pneumatic lithotripsy.

Key words: Lower Ureteric Stone, Stone Cone, Stone Retropulsion.

Article Citation: Hussain K, Khan A, Ali RN, Tariq M, Shahid S, Butt MK. Incidence of Stone Retropulsion in Ureteroscopic Pneumatic Lithotripsy for lower ureteric stones by using stone cone. Professional Med J 2019; 26(12):2169-2172. DOI: 10.29309/TPMJ/2019.26.12.3693

issue which is responsible for increasing patient cost and morbidity.⁵ About 5 % to 40 % of stone retropulsion is noted in proximal ureteric stones during ureteroscopic pneumatic lithotripsy while only 1.5 to 2 % in distal ureteric stones in various studies. Stone Retropulsion needs further evaluation and management.⁶

Those stones who migrates to higher area during procedure needs usage of additional equipment e.g. ureteric stent placement and extracorporeal shock wave lithotripsy later on.⁷

Persistent infections, renal colic and stone recurrence are major issues that are associated with residual stone fragments.⁸

Many new instruments such as dormia basket and previous less capable versions of stone cone,

tried to prevent Retropulsion of stone fragments but there were many limitations regarding access and cost of such instrument to achieve anticipated results.

The Stone Cone (Microvasive-Boston Scientific Corp., Spencer, IN) can reduce retrograde ureteric stone Retropulsion and allow safe fragment extraction during URSL.⁹ The purpose of stone cone is to reduce retrograde Retropulsion of stone during ureterorenoscopy. We will focus on our experience with use of stone cone during the pneumatic lithotripsy of lower ureteric stones to measure the incidence of stone Retropulsion with use of stone cone and complications of procedure.

MATERIALS AND METHODS

Study Technique

Cross-Sectional Study.

Study Setting

Department of Urology, Teaching DHQ Hospital Gujranwala / Gujranwala Medical College, Gujranwala.

Study Duration

Study was carried out from January 2017 to December 2018.

Sample Size

120 patients

Sampling Technique

Consecutive simple random sampling technique was used.

Sampling Criteria

Patients diagnosed as lower ureteric stone were enrolled, non-contrast spiral CT scan was used to diagnose and to assess size and location of the stone. Patients aged 20 to 50 years of both gender were enrolled. Patients who were treated previously with any other devices and patients having multiple stones were excluded from study.

Data Collection and Analysis Procedure

After approval from hospital ethical committee

and informed consent 120 patients were enrolled in study. Detailed history was taken and physical examination was done. Diagnosis was confirmed with spiral CT scan. Routine laboratory tests were performed and antibiotics were given accordingly. All patients underwent ureteroscopic pneumatic lithotripsy and stone cone was used to decrease repulsion of fragments. A stone fragment Retropulsion of >5mm and which could not be reached by ureteroscopy was considered upward Retropulsion. Success of procedures was considered as absence of any residual fragment having size >2mm and no need of additional procedure required. After procedure imaging done was computed tomography and abdominal plain radiography. Patient's demographic data, age, gender, duration of disease, stone size, success rate and complication of procedure was noted in specially designed proforma. All data was entered in SPSS 22.0. Mean and standard deviation were presented for quantitative variables while frequencies and percentages were presented for qualitative variables. Chi square test was applied for stratification of data, p value 0.05 taken as significant

RESULTS

There were 65% male while 35% patients were females with a mean age as 46 ± 2.6 years. Success rate of 97.5% was achieved in patients in which stone cone was used. Complications included retropulsion of stone in 4 patients (3.3%), ureteric mucosal injury was seen in 5 patients (4.1%) it was defined as procedures in which ureteral mucosal flap was raised during procedure and it was managed conservatively. ureteric perforation was seen in 1 patient (0.83%) and it was diagnosed as creation of small hole in the wall of ureter due to energy transmission through the wall of ureter during procedure and it was managed conservatively by placing D.j stent. Later it was followed after 4 weeks and found no perforation on removal of D.j stent. The ureteric stone length ranged from 6.8-13.5mm. Data was stratified for age (p value 0.01), gender (p value 0.0002) and duration of disease (p value 1.2).

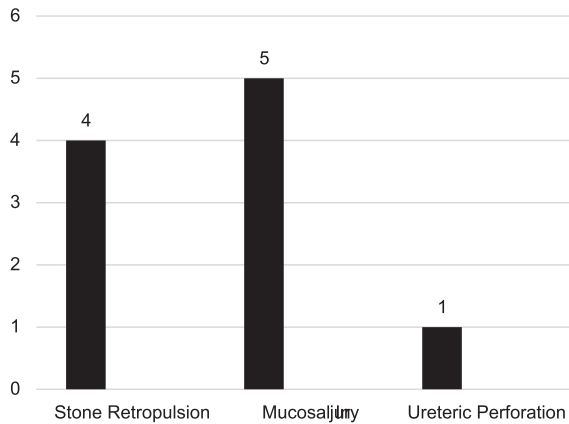


Figure-1. Complications of procedure

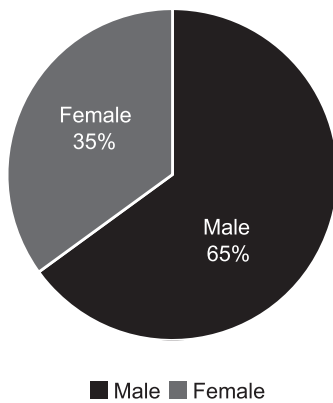


Figure-2. Distribution of gender

Gender	Stone Retropulsion		Total
	Yes	No	
Male	3 (3.8%)	75 (96.2%)	78 (100%)
Female	1 (2.3%)	41 (97.7%)	42 (100%)

p-value=0.0002

Table-I. Cross tabulation of gender and stone retropulsion

Age Group	Stone Retropulsion		Total
	Yes	No	
20-35 Years	2 (2.8%)	68 (97.2%)	70 (100%)
36-50 Years	2 (4%)	48 (96%)	50 (100%)

p-value=0.01

Table-II. Cross tabulation of age and stone retropulsion

Duration of Disease	Stone Retropulsion		Total
	Yes	No	
Less than 6 Months	1 (1.08%)	91 (98.92%)	92 (100%)
More than 6 Months	3 (10.7%)	25 (89.3%)	28 (100%)

p-value=1.20

Table-III. Cross tabulation of duration of disease and stone retropulsion

DISCUSSION

Lower ureteric stones most commonly treated by URS. It is minimally invasive with good acceptance by patients and with few side effects. Due to back pressure created by energy source, proximal retropulsion is a common problem during ureteroscopic pneumatic lithotripsy.¹²

In this study only 4 patients out of 120 who were treated by pneumatic lithotripsy with stone cone got stone size >5 mm migrated in kidney with incidence of about 97.5% declared successful procedures. There was no association between the size of stone and retropulsion. There was mucosal injury in 4.1% patients and ureteric perforation in 0.83%. In our study retropulsion rate was 3.3 % which is comparable to other studies. In one study of the 133 uses of the Stone Cone, there were 2 (1.5%) residual retropulsed fragments >2 mm which required an additional procedure.¹⁰ In a comparative study by Waleed shabana the retropulsion rate of stone in pneumatic lithotripsy with stone cone was 2.1 % against the control group in which stone Retropulsion rate was 15.4% which was statistically significant.¹³

Mr gupta reported use of holmium laser as energy sources has only 3.3% of failure rate due to back Retropulsion of stone. About 18 to 92 minutes is reported operation time of URS. The operation duration didn't significantly increased with application of stone cone in this study. During ureteroscopy minor lesions of ureter are more common as reported rates of 0-15.4% in this study. Few patients in this study got mucosal lacerations 0.05%.¹⁴ It is reported that use of stone cone is associated with reduction in duration of operation and less chances of ureteric injury as well significant decrease in upward stone

Retropulsion.¹⁵

CONCLUSION






In conclusion, the success rate of stone cone is high in decreasing upward Retropulsion in ureteroscopic pneumatic lithotripsy for stones of lower ureter. It didn't increase the operation time and complication rates when used meticulously.

Copyright© 25 July, 2019.

REFERENCES

- Zumstein V, Betschart P, Abt D, Schmid HP, Panje CM, Putora PM. **Surgical management of urolithiasis—a systematic analysis of available guidelines.** BMC Uro. 2018; 18(1):25.
- Breda A, Territo A, López-Martínez JM. **Benefits and risks of ureteral access sheaths for retrograde renal access.** Current opinion in urology. 2016; 26(1):70-5.
- Kramolowsky E, McDowell Z, Moore B, Booth B, Wood N. **Cost analysis of flexible ureteroscope repairs: evaluation of 655 procedures in a community-based practice.** J Endourol. 2016; 30(3):254-6.
- Abbott JE, Sur RL. **Ureteroscopy complications.** Smith's Textbook of Endourology. 2019:653-67.
- Desai MR, Patel SB, Desai MM, et al. **The dretler stone cone: A device to prevent ureteral stone Retropulsion. The initial clinical experience.** J Urol 2012; 167:1985–8.
- Patel S, Kukreja R, Sabnis R, Desai R et al. **The dretler stone cone: A device to prevent ureteral stone retropulsion—The initial clinical experience.** Journal of Urology. 2012; 167(5):1985-8.
- Phan YC, Segaran S, Chew BH, Sriprasad S, Rane A. **Devices to help combat stone retropulsion during ureteroscopic lithotripsy in 2016.** J Clin Urol. 2017; 10(2):87-92.
- Assimos D, Krambeck A, Miller NL, Monga M, Murad MH, Nelson CP, Pace KT, Pais VM, Pearle MS, Preminger GM, Razvi H. **Surgical management of stones: American urological association/endourological society guideline, Part I.** The J Urol. 2016; 196(4):1153-60.
- Holley P, Sharma S, Perry K, Turk T. **Assessment of novel ureteral occlusion device and comparison with stone cone in prevention of stone fragment retropulsion during lithotripsy.** Journal of Endourology. 2005; 19(2):200-203.
- Eisner B, Dretler S. **Use of the stone cone for prevention of calculus retropulsion during holmium: YAG laser lithotripsy: Case series and review of the literature.** Urologia Internationalis. 2009; 82(3):356-360.
- Farahat Y, Elbahnasy A, Elashry O. **A randomized prospective controlled study for assessment of different ureteral occlusion devices in prevention of stone retropulsion during pneumatic lithotripsy.** Urology. 2011; 77(1):30-35.
- Wolf J. **Treatment selection and outcomes: Ureteral Calculi.** Urologic Clinics of North America. 2007; 34(3):421-430.
- Shabana W, Teleb M, Dawod T. **Safety and efficacy of using the stone cone and an entrapment and extraction device in ureteroscopic lithotripsy for ureteric stones.** Arab Journal of Urology. 2015; 13(2):75-79.
- Scotland KB, Krocak T, Pace KT, Chew BH. **Stone technology: Intracorporeal lithotripters.** World J Uro. 2017; 35(9):1347-51.
- Elashry O, Tawfik A. **Preventing stone retropulsion during intracorporeal lithotripsy.** Nature Reviews Urology. 2012; 9(12):691-698.

AUTHORSHIP AND CONTRIBUTION DECLARATION

Sr. #	Author(s) Full Name	Contribution to the paper	Author(s) Signature
1	Khalid Hussain	Researcher	
2	Attiq-ur-Rehman Khan	Making perfoma & Data collection.	
3	Rao Nouman Ali	Statistical analysis.	
4	Maria Tariq	Proof Reading.	
5	Salman Shahid	Proof Reading.	
6	Muhammad Khalid Butt	Supervisor.	