



## EFFECT OF HALOPERIDOL ON CENTRILOBULAR VEIN AND PORTAL TRIAD OF LIVER IN THE ALBINO RATS DURING INTRAUTERINE LIFE.

Shazia Tufail<sup>1</sup>, Sobia Ibrahim<sup>2</sup>, Muhammad Suhail<sup>3</sup>

1. M.Phil (Anatomy)  
Assistant Professor  
Department of Anatomy  
KEMU, Lahore.
2. M.Phil (Anatomy)  
Professor  
Department of Anatomy  
SKZMDC.
3. M.Phil (Anatomy)  
Assistant Professor  
Department of Anatomy  
KEMU, Lahore.

**Correspondence Address:**  
Dr. Shazia Tufail  
Department of Anatomy  
KEMU, Lahore.  
iqbalian@hotmail.com

**Article received on:**  
21/07/2018

**Accepted for publication:**  
11/12/2018

**Received after proof reading:**  
22/05/2019

**ABSTRACT:** Haloperidol is first generation antipsychotic used to treat psychosis. Its usage during pregnancy benefits psychotic mother and is indispensable for treating psychiatric emergency situations. To evaluate the effects of haloperidol on development of centrilobular vein and portal triad of liver given to albino rats during intrauterine period. **Study Design:** Experimental study. **Setting:** PPGMI Animal House, Lahore. **Period:** July to September 2014. **Materials & Methods:** Pregnant female rats were randomly divided into three groups A, B and C, 15 rats in each group. Group B & C were given haloperidol in a dose of 0.4mg/kg and 0.8mg/kg body weight by intraperitoneal route whereas group A was considered as control group. Hysterotomy was done on 21<sup>st</sup> day of gestation and pups were removed. Pups of group A, B and C were designated as A1, B1 and C1. They were grossly examined for any abnormality and liver was removed after dissection. Slides were made and stained to evaluate changes in detailed histological study of centrilobular veins and portal triads. **Results:** Comparison of centrilobular vein and portal triad of group B1 and C1 with control A1 revealed that there is significant congestion seen in centrilobular veins of group B1 and C1 with P value  $\leq 0.001$  and signs of inflammation are present in experimental groups which were significant as compared to control group A1 with P value  $\leq 0.001$ . **Conclusion:** Haloperidol, given during intrauterine life is responsible for initiating cell injury sequelae in the developing liver of fetal albino rats and must be given with caution if necessary.

**Key words:** Centrilobular Vein, Congestion, Fetal Liver, Haloperidol, Portal Triad.

**Article Citation:** Tufail S, Ibrahim S, Suhail M. Effect of haloperidol on centrilobular vein and portal triad of liver in the albino rats during intrauterine life. Professional Med J 2019; 26(6):973-979. DOI: 10.29309/TPMJ/2019.26.05.3610

### INTRODUCTION

Psychosis is a disease which affects brain development and it has multiple genetic and environmental factors which affects neuronal disconnection.<sup>1</sup> The genetic etiology is likely to be polygenic. According to an estimate almost 6.6 % of 1<sup>st</sup> degree relatives are affected.<sup>2</sup> Its treatment involves education, close monitoring of symptoms, stress management and creating a strong, supportive environment in addition to medication. However medication is always the mainstay in relieving symptoms of psychosis and is critical in preventing relapses. These medicines are categorized as antipsychotics or neuroleptics.<sup>3</sup> Haloperidol is one of the first generation neuroleptic drug approved by the U.S. Food and Drug Administration (FDA) on April 12, 1967<sup>4</sup> and was later marketed in the U.S.

and other countries under the brand name Haldol by McNeil Laboratories. It is a typical and non-selective which has the ability to bind to a broad range of receptors as dopamine D1 and D2, 5-HT<sub>2</sub>, histamine H1 and  $\alpha$ <sub>2</sub> adrenergic receptors in the brain. It acts as antagonism of dopamine receptors in the mesolimbic and mesofrontal systems.<sup>5</sup>

The monitoring of haloperidol is important clinically, however large doses can be given safely in intravenous and intramuscular injections for rapid neuroleptization.<sup>6</sup> Its prolonged clinical affects are due to hydroxyl metabolites. The recommended doses in psychosis 0.5 to 5 mg twice or thrice, intramuscular doses vary from 2 to 30 mg where as intravenous up to 30mg.<sup>7</sup> Lethal dose (LD<sub>50</sub>) in rats is  $\geq 128$ mg/

kg subcutaneously, 27mg/kg intraperitoneally and 15mg/kg intravenously.<sup>8</sup> Haloperidol is contraindicated in coma, acute stroke cardiac disease, and pregnancy and lactating mother.

Various studies were conducted in the past to evaluate effects of haloperidol in different organs of adults and fetus. In a series of paper by Lewis et al, he concluded that haloperidol stunted brain growth.<sup>9</sup> In 1990, forebrain development was observed by giving haloperidol and it was found that haloperidol halted brain growth<sup>10</sup>, with its usage proliferation of brain cells were affected during development.<sup>11</sup> In 2002, cerebral cortex was examined with increased number of apoptotic cells after administration of haloperidol<sup>12</sup> and vasoconstriction of basilar artery was observed in 2004 with chronic haloperidol usage.<sup>13</sup>

Damaging effects on adult liver was observed in a study conducted in 2009.<sup>14</sup> In 2010, another study conducted on guinea pigs also revealed damaging effects of haloperidol on adult liver.<sup>15</sup> This study was designed to see the damaging effects of haloperidol on developing liver.

## MATERIALS AND METHODS

45 female albino rats and 12 male albino rats of Sprague-drawly strain, weighing about 250-300 g were used in this study. They were obtained from Pakistan Council of Scientific and Industrial Research (PCSIR), Karachi.

All animals were kept separately for acclimatization in the animal house of Punjab Postgraduate Medical Institute, Lahore for 15 days. A twelve hour light and dark cycle was maintained at room temperature between 22-25°C. After 15 days, three female and one male rat were kept together in a cage for a week for conception and male rats were removed from the cage later on. Female rats were then observed for vaginal plug (Appendix II).<sup>16</sup> This was taken as day zero of pregnancy.

After conception female rats were randomly divided in three groups, each group having 15 rats. Groups were defined as control group A and experimental groups B and C respectively.

Haloperidol in inject able form was given to the rats by intraperitoneal route (Figure-1) from 9<sup>th</sup> day of gestation onwards to the experimental groups as liver primordium first appears on the 11<sup>th</sup> day of development.<sup>17</sup> Control group A received phosphate buffered saline only. The dose schedule was as follows:

### Control Group A

It had 15 female rats which were given 0.2mg/kg body weight of phosphate-buffered saline intra peritoneal from 9<sup>th</sup> to 21<sup>st</sup> day of gestation as a champ treatment.

### Experimental Group B

It had 15 female rats which were given 0.4mg/kg body weight of haloperidol intra peritoneal from 9<sup>th</sup> to 21<sup>st</sup> day of gestation.

### Experimental Group C

It had 15 female rats which were given 0.8mg/kg body weight of haloperidol intra peritoneal from 9<sup>th</sup> to 21<sup>st</sup> day of gestation.

These animals of each group (A,B and C) were then euthanized on 21<sup>st</sup> day of gestation by injecting sodium pentobarbital as anesthetic intraperitoneally in doses of 45mg/kg<sup>18,19</sup> and morphine as analgesic in doses of 0.3-0.5mg/kg intraperitoneally.<sup>20</sup> Hysterotomy was done and pups were removed. Average litter size of albino rats in each group was 5 per animal, so in this step of study the total number of the pups was 5 X 45 =225. 24 pups from each group were randomly selected by lottery method (appendix-III).<sup>21</sup> These pups were labeled as A1, B1, and C1.

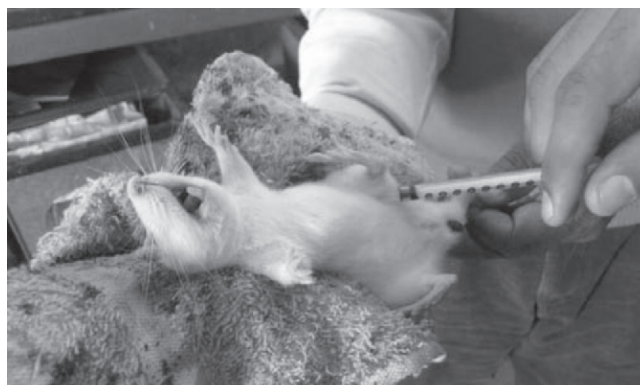

Figure-1. Photograph of albino rat showing administration of haloperidol through intraperitoneal route

### Procedure of dissection

The body weight of each animal was recorded before dissection. Animals were stretched out in supine position on the dissection tray. Their limbs get fixed with the help of pins and an extended midline incision from the xiphisternum to the pubic symphysis was given in the skin to open the abdominal wall in the mid line with the help of scissors. The liver was identified, dissected out after cutting off the falciform and coronary ligaments. Common hepatic duct and hepatic vessels were also incised. (Figure-2). The liver was weighed and observed for any gross abnormality and preserved in 10% formalin for histological evaluation.




Figure-2. Photograph of albino pup showing its organs after dissection

### STATISTICAL ANALYSIS

Data was analysed by SPSS version 21. Qualitative parameters as centrilobular vein and portal triads were described by using frequencies and percentages for each group. Comparison of these variables among each group was done by performing CHI Square tests. The P-value less than 0.05 was considered as statistically significant.

### RESULTS

The liver of pups of control group A1 were examined by light microscope and they revealed normal hepatic structure, with typical features of classic hepatic lobules; made up of radiating plates of hepatocytes forming a network around a centrilobular vein.<sup>22</sup> The hepatocytes were presented as radiating rows with narrow sinusoids. These sinusoids had irregular boundaries composed of only a single layer of fenestrated

endothelial cells.<sup>23</sup> Outside the hepatic lobule at angles, lied the portal areas of connective tissue, each including a hepatic portal vein, a branch of hepatic artery and a bile ductule<sup>24</sup> (Figure-3). Sections of liver of haloperidol treated experimental rats of group B1 & C1 showed adverse effects of drug on hepatocellular structure, hepatocytes were not arranged in parallel rows rather they are scattered. Portal triads were not formed and central veins were dilated. Congestion seen in central vein and sinusoids and neutrophil infiltrations were present. (Figure-4&5)

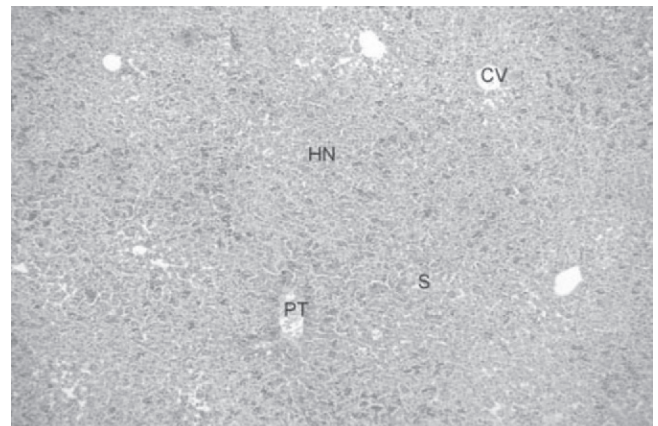


Figure-3. Photomicrograph of cross section of liver of pup of control group A1 showing centrilobular vein (CV), hepatic sinusoids (S), portal triad (PT), hepatocytes nucleus (HN) (H&E, 10X)




Figure-4. Photomicrograph of cross section of liver of pup of experimental group B1 showing disturbed architecture of hepatocytes (H), centrilobular vein (CV), hepatic sinusoids (S) (H&E, 10X)

### Inflammation and congestion in the portal triad

When portal triads were analyzed it was observed that the portal triads were not formed properly in 2 pups of group A1, 21 pups of group B1 and

all 24 pups of the group C1, and the difference was statistically significant with p-value <0.001. (Table-I)

When pairwise comparison was made, the findings for group B1 and C1 were significantly different from A1, both with p-values <0.001, while the difference between B1 and C1 was statistically insignificant with p-value 0.113. (Table-II, Figure-7)

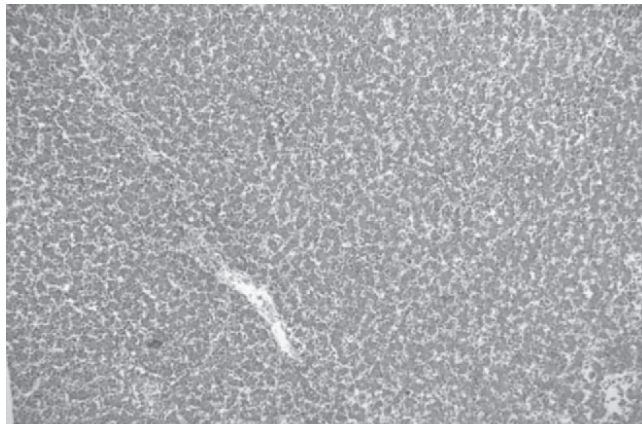


Figure-5. Photomicrograph of cross section of liver of pup of experimental group C1 showing disturbed cord like arrangement of hepatocytes of the liver, centrilobular vein and hepatic sinusoids (H&E, 10X)




Figure-6. Photomicrograph of cross section of liver of pup of control group A1 showing centrilobular vein (CV), hepatic sinusoids (S), portal triad (PT), hepatocytes (H), hepatocytes nucleus (HN) (H&E, 20X)

**Congestion in the centrilobular veins**

Congestion in the centrilobular vein was present in 1(4.2%), 11(45.8%) and 17(70.8%) pups in groups A1, B1 and C1 respectively and this difference was significant with p-value <0.001. (Table-III) The pair wise comparison yielded that the difference of B1 and C1 from A1 was significant with 0.003 and <0.001 respectively. The difference between B1 and C1 was insignificant with p-value 0.079. (Table-IV, Figure-8)

Based on observed means

**Key**

- A1 Control Group
- B1 Experimental Group
- C1 Experimental Group
- Df Degrees of freedom
- \*\* Highly significant difference(P<0.01)
- ++ Insignificant difference

**Key**

- A1 Control group
- B1 Experimental group
- C1 Experimental group
- \*\* Highly significant difference (p-value< 0.001)
- ++ Insignificant difference

Groups	Present		Absent		Not Formed		Total	
	N	%	N	%	N	%	N	%
Group A1	1	4.2	21	87.5	2	8.3	24	100.0
Group B1	2	8.3	1	4.2	21	87.5	24	100.0
Group C1	0	0.0	0	0.0	24	100.0	24	100.0

Table-I. Inflammation and congestion in the portal triads of liver in control and experimental groups exposed to haloperidol  
Chi-square = 67.5 p-value <0.001\*\*

Group 1	Group 2	Chi-square	Df	P-value
Group A1	Group B1	41.0	1	<0.001**
	Group C1	52.4	1	<0.001**
Group B1	Group C1	4.36	1	0.113++

Table-II. Pair wise comparison for inflammation and congestion in the portal triads of liver in control and experimental groups exposed to haloperidol

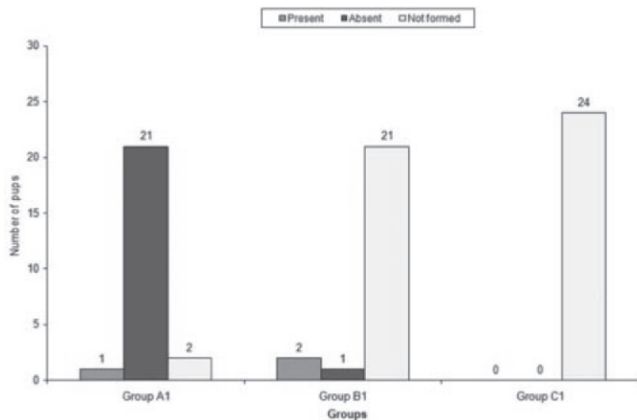


Figure-7. Graphic comparison of inflammation and congestion in portal triads among various groups

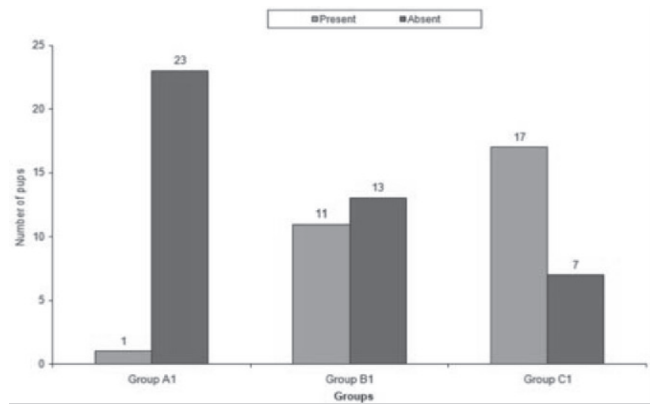


Figure-8. Graphic comparison of congestions in the centrilobular vein in control group A1 and experimental groups B1 and C1 exposed to haloperidol

Groups	Present		Absent		Total	
	N	%	N	%	N	%
Group A1	1	4.2	23	95.8	24	100.0
Group B1	11	45.8	13	54.2	24	100.0
Group C1	17	70.8	7	29.2	24	100.0

Table-III. Congestion in centrilobular veins of liver of control and experimental groups exposed to haloperidol  
Chi-square = 22.63 p-value <0.001\*\*

Group 1	Group 2	Chi-square	Df	P-Value
Group A1	Group B1	9.0	1	0.003**
	Group C1	20.0	1	< 0.001**
Group B1	Group C1	3.08	1	0.079++

Table-IV. Pairwise comparison for the congestion in centrilobular veins in liver of control and experimental groups exposed to haloperidol

**DISCUSSION**

In the present study, congestion was observed in the centrilobular vein and venous sinusoids of hepatocytes of experimental groups B1 and C1 (p<0.001). Mild congestion was also observed in livers of control group A1. These findings were correlated with the findings of other researchers as in 2008 it was observed that haloperidol induced congestion and hemorrhage in adult liver tissue.<sup>25</sup> The probable mechanism of this congestion is a reduced outflow of blood from tissues due to impaired venous drainage resulting from the toxic effects of haloperidol on the liver.<sup>26</sup> It has been postulated that haloperidol increases activity and super sensitivity of D1 like receptors which are in abundant in the smooth muscles of blood vessels of the major organs of rats resulting in congestion of blood vessels<sup>27</sup> as observed in experimental groups B1 & C1.

Multinucleated Giant cells, also known as

scavenger cells were also observed in some tissues of experimental groups B1 & C1. These changes are due to the fact that in acute inflammation permeability of vessel wall increases with active migration of polymorphs between endothelial cells through the vessel wall and then into the surrounding tissue to cause chemotaxis.<sup>28</sup> It is an attempt of injured cell to remove debris. These findings of the present study were correlated with the findings of other researchers as in 1987, Sommi et al also observed similar changes in hepatocytes of adult rats.<sup>29</sup> In 2008, Badria and Fawzyah also observed similar changes induced by haloperidol in the developing liver of chick embryo.<sup>30</sup> In another study, it was postulated that continuous oxidative stress and oxygen free radicals released from haloperidol oxidation are responsible for activation of nuclear transcription factor. This resulted in chemokine production by Kupffer cells, leading to leucocytes infiltration.<sup>31</sup> These polymorphs

along with mononuclear phagocytes system work in collaboration to clear abnormal toxins released by haloperidol metabolites circulating in the blood. If the haloperidol metabolites persist then macrophages belonging to mononuclear phagocytic system are transformed and persist as giant cells to combat against inflammation.<sup>32</sup>

In the present study, dilatation of centrilobular veins were also noted in the experimental groups B1 and C1 and was found statistically significant as compared with control group A1 ( $p < 0.001$ ). This dilatation possibly resulted due to impaired venous drainage in injured hepatic tissue. As a result of congestion described previously, blood volume and pressure in the central vein increases leading to edema and venous dilatation of centrilobular veins.<sup>33</sup>

## CONCLUSION

The present study was performed on the albino rats and revealed that haloperidol was responsible for destroying the normal architecture of the developing liver. It was concluded that the signs of inflammation were seen in the developing liver which is suggestive of congestion around portal triad and centrilobular veins. It is recommended that the antidepressant drug particularly haloperidol must not be given to pregnant women or must be stopped before pregnancy and further research work would be carried out to observe side effects of these drugs.



Copyright© 11 Dec, 2018.

## REFERENCES

1. **What causes Psychosis.** [internet] 2006 Available from: <http://www.psychosissucks.ca/whatcausespsychosis.cfm>.
2. Xu B1, Ionita-Lazal, et al. **De novo gene mutations highlight patterns of genetic and neural complexity in schizophrenia.** *Nat Genet.* 2012; 44(12):1365-9.
3. Melmon KL. Antipsychotic drugs. In: Melmon and Morelli's. **Clinical pharmacology.** New York: McGraw-Hill; 1999.
4. **Haloperidol.** [internet] 2013 [updated 2014 May 14]. Available from: [en.wikipedia.org/wiki/Haloperidol](http://en.wikipedia.org/wiki/Haloperidol).
5. Katzung BG. **Basic and clinical pharmacology.** 10<sup>th</sup> ed. New York: Lange; 2007.p.479.
6. Finnegan P, Buckingham R. **Treatment of acute excited psychosis with intramuscular haloperidol.** *Can Fam Physician.* 1980; 26: (1199-1202).
7. Julia Hega di Labdani. **Haloperidol.** [internet] 1992 [updated 1992 Sep 10]. Available from: <http://www.inchem.org/documents/pims/pharm/haloperi.htm>.
8. **Material safety data sheet 2007.**
9. Patel AJ, Barochovsky O, Lewis PD. **Psychotropic drugs and brain development: effects on cell replication in vivo and in vitro.** *Neuropharmacology.* 1981; 20(12):1243-9.
10. Castro R, Brito B, and Notario V (1990) **Prenatal haloperidol alters the expression of DNA polymerases in brain regions of neonate rats.** *Cell Mol Neurobiol.* 1990; 10(2): 281-289.
11. Williams R, Ali SF, Scalzo FM, Soliman K, Holson RR. **Prenatal haloperidol exposure; Effects on brain weights and caudate neurotransmitter levels in rats.** *Brain Res Bull.* 1992; 29(3-4):449-58.
12. Mitchell J. Cooper A.C. Griffiths M.R. Cooper A.J. **Acute administration of haloperidol induces apoptosis of neurons in the striatum and substantia nigra in the rat.** *Neuroscience.* 2002; 109(1):89-99.
13. Gepdiremen. N. Aydin. N. Halici Z. Sahin O. Unal B. Aydin M.D. Bakuridze K. **Chronic treatment of haloperidol causes vasoconstriction on basilar arteries of rats, dose dependently.** *Pharmacolo Res.* 2004,12,3; 50(6):569-74.
14. Halici Z. Dursun H. Keles O. Odaci E. Suleyman H. Ayden N. Cadirci E. Kalkan Y. Unal B. **Effect of chronic treatment of haloperidol on the rat liver: A stereological and histopathological study.** *Naunyn-Schmied Arch Pharmacol.* 2009; 379(3):253-61.
15. Obzek et all. **Haloperidol induced neuronal damage in guinea pig hippocampus. A Microscopic Study.** *Journal of neurobiological sciences.* 2010; 27(4):438-445.
16. Saharmm., Omar, Abed el samad. **Modified vaginal smear cytology for the determination of the rat estrous cycle phases, versus ordinary papanicolaou technique, verified by light and scanning electron microscopic examination of the endometrium.** *The Egyptian journal of histology.* 2007; 30(2):397-408.
17. Laurence L, Brunton. **Goodman & Gilman's the pharmacological basis of therapeutics.** 11th edition. New York: McGraw Hill Professional; 2005.
18. Lee-Parritz, D. **Analgesia for rodent experimental surgery ISRAEL Journal of Veter Medi.** 2007; 62:3-4.

19. **AVMA guidelines on Euthenasia.**
20. British Society of Animal Sciences. **Ethical guidelines for research in animal sciences.** Jarvis S, Day J.E.L, Reed B.
21. Appendix III. **Tutorial simple random sampling 2014** [internet] Available from: <http://www.emathzone.com/tutorials/basic-statistics/simple-random-sampling.html>.
22. Mescher A.L. **Junqueira's basic histology.** Text & Atlas. 13<sup>th</sup> edition. McGraw Hill.2013.
23. Siddiqui H.L. **Medical histology.** 5<sup>th</sup> edition. Paramount publishing enterprise. 2011.
24. Gray H. Standring S. **Gray' anatomy the anatomical basis of clinical practice.** 40<sup>th</sup> edition. Spain. Churchill Livingstone Elsevier. 2008.
25. Halici Z., Dursun H, Keles O, Odaci E, Suleyman H, Ayden N, Cadirci E, Kalkan Y, UnalB. **Effect of chronic treatment of haloperidol on the rat liver: A stereological and histopathological study.** Naunyn-Schmied Arch Pharmacol.2009; 379(3):253-61.
26. Govan A, Macfarlane P, Callander R, **Pathology Illustrated.** New York: Churchill Livingstone; 1981.
27. Hussain T, Lokhandwala M (2003). **“Renal dopamine receptors and hypertension”.** Exp Biol Med (Maywood) 228 (2): 134–42.
28. Curran R.C. Crocker J. Curran's Atlas of Histopathology. 4<sup>th</sup> edition. Oxford University Press: Harvey Miller Publishers; 2005.
29. Sommi R, Crismon M.L, Bowden. C.L. **Fluoxetine- A serotonin specific second generation antidepressant.** Pharmacotherapy; 7:1-15.
30. Abd-Elmagid B, Abdullah Al-Ghamd F. **Effect of administration of haloperidol on the developing liver of the chick embryo.** sjsbs. 2008,12; 15(2):297-306.
31. Vairetti M, Battaglia A, PAMPARANA F, Canonica PL, Ricchelmi P, Berte F **Haloperidol induced changes in glutathione and energy metabolism: Effect of nicergoline.** Eur J Pharmacol 453:69-73.
32. Kumar V, Abbas A.K., Fausto N, Mitchell R.N. **Robbins basic pathology.** 8th ed. Saunders: Elsevier; 2007.
33. Ahmed J. **Gross pathology.** 4th edition. Pakistan. Zubair Bashir Printers; 2002.

### AUTHORSHIP AND CONTRIBUTION DECLARATION

Sr. #	Author-s Full Name	Contribution to the paper	Author=s Signature
1	Shazia Tufail	Research work	
2	Sobia Ibrahim	Research work	
3	Muhammad Suhail	Supervision	