



## EFFICACY OF PHOTODYNAMIC THERAPY IN THE TREATMENT OF CUTANEOUS LEISHMANIASIS.

Mahvish Aftab Khan<sup>1</sup>, Sehrish Aftab<sup>2</sup>, Nadia Shams<sup>3</sup>, Rahmat Ullah Khan<sup>4</sup>

1. MBBS, FCPS Dermatology  
Assistant Professor  
Department of Dermatology  
Rawal Institute of Health Sciences  
Islamabad.
2. MBBS, FCPS Dermatology  
Consultant Dermatologist  
Department of Dermatology  
DHQ Hospital Multan.
3. MBBS, FCPS Medicine  
Associate Professor  
Department of Medicine  
Rawal Institute of Health Sciences  
Islamabad.
4. MBBS, FCPS Medicine,  
FCPS Gastroenterology  
Consultant Physician.  
PAEC General Hospital Islamabad.

**Correspondence Address:**

Dr. Mahvish Aftab Khan  
H # 880, Street # 27, G – 9 / 1,  
Islamabad.  
mahvishmuddasser@yahoo.com

**Article received on:**

02/06/2018

**Accepted for publication:**

31/09/2018

**Received after proof reading:**

22/05/2019

**ABSTRACT...** A limited number of case reports have studied the efficacy of Photodynamic Therapy (PDT) in management of Cutaneous Leishmaniasis (CL). Topical PDT is an innovative mode of therapy that works on principle of selective uptake of photosensitizing agent by CL lesions. Current study was conducted to determine efficacy of topical photodynamic therapy of CL. **Study Design:** Descriptive cross sectional study. **Setting:** Dermatology outdoor clinic PIMS Islamabad. **Period:** July 2015 to Jan 2016. **Materials and Methods:** Total 75 patients (>12 years) of either gender with biopsy proven CL lesions were included after ethical approval. Pregnant or lactating women, those with sensitivity to light or photo sensitizer were excluded. The selected cases were administered once a week sessions of topical 5-ALA PDT therapy. This therapy was continued till 4 weeks and efficacy was observed at 6<sup>th</sup> week; efficacy labeled as yes if there was no erythema with resolution of papules, plaques or nodules, surrounded by normal healthy skin clinically and the histo-pathological smears revealing absence of amastigotes, otherwise labeled as non-effective. **Results:** Mean age was 24.37+7.43 years. There were 44(58.67%) females and 31(41.33%) males. Mean duration of disease was 40.29+11.73 days and mean size of lesion was 19.69+9.88 mm. Effective PDT outcome was seen in 67(89.33%) patients at 6<sup>th</sup> week of therapy. **Conclusion:** This study concluded that topical photodynamic therapy is an effective method for treatment of Cutaneous Leishmaniasis.

**Key words:** ALA, Amastigotes, Kala azar, Leishmaniasis, Photodynamic Therapy.

**Article Citation:** Khan MA, Aftab S, Shams N, Khan R. Efficacy of photodynamic therapy in the treatment of cutaneous leishmaniasis. Professional Med J 2019; 26(6):944-950. DOI: 10.29309/TPMJ/2019.26.05.3602

### INTRODUCTION

Cutaneous Leishmaniasis (CL) is the most frequently observed type of Leishmaniasis caused by a mono-cellular parasite that is transmitted to humans by the vector (i.e. sandfly bites). There are approx. twenty species of Leishmania. CL is a major health problem in tropical and sub-tropical regions of Asian & African countries.<sup>1,2</sup> CL is found to be endemic in eighty eight countries, with twelve million people globally affected and 1.5-2 million new cases every year.<sup>3</sup>

The lesions develop where the Phlebotomus sand-fly bites and then over a period of few months it progresses to erythematous papules to larger dusky granulomatous lesions. The lesions have ulceration in center with raised indurated borders. The CL may be localized i.e. restricted to a single part of the skin or diffuse i.e. with larger

number of lesions on multiple body parts (diffuse CL).<sup>4,5</sup> One of the variety called mucocutaneous leishmaniasis presents with the involvement and destruction of mucous membranes of the oral cavity, throat and nose. Certain species of Leishmania may present with visceral involvement (i.e. Leishmania donovani, L. infantum, L. chagasi). They can also lead to extensive invasion of viscera life threatening form of Visceral Leishmaniasis also called as Kala-azar. Among the patients who are immunologically competent, the clinical presentation of CL depends on the underlying species of Leishmania.<sup>6,7</sup>

The localized form CL is commonly caused by L. major (zoonotic CL) that has tendency for recovery over 2-4 months duration.<sup>8</sup> The L. tropica is restricted only to human beings (anthroponotic CL) and its lesions remain for a prolonged time

period of 6-15 months. However, the *L. infantum* is less commonly seen species. In the current era, localized form of CL is caused predominantly by *L. Braziliensis*, *L. Peruviana*, *L. Guyanensis*, or *L. Mexicana*. In southern America, diffuse CL is caused *L. Amazonensis*; and in Africa by *L. Aethiopica*. However, the immune-deficient patients may develop diffuse form of CL even by species usually causing localized CL. moosavi et al reported cases from Southern America that have presented with mucosal spread, i.e. by *L. Braziliensis*, *L. Panamensis* or *L. Guyanensis*.<sup>5</sup>

The laboratory diagnostic confirmation of CL can be obtained by directly seeing the parasites in scrapings from skin lesions, skin biopsy or the impression smears. The stains being used are Giemsa, Leishman's or Wright's stain. The fresh or active lesion shave higher yield of amastigotes. However, the polymerase chain reaction assays (i.e. PCR) can be used in certain cases as per availability and affordability of patients. The culture of *Leishmania* can also be obtained, however different *Leishmania* species demonstrate growth only on specific media. Some of the species can be difficult to isolate, hence leading to false negative cultures.<sup>9</sup>

The may be natural healing of the lesions over a duration of months to years, but this often leads to residual disfigurement along with mildly depressed scars. Though, CL is a self-healing disease, however the scarring and disfigurement in untreated or partially treated cases along with prolonged duration of the disease suggests the need for timely and effective therapy.<sup>10</sup> The final aim of therapy in CL is to eradicate all the amastigotes, reduce the size of lesions, reduce the disfigurement and minimize the scars. The available literature regarding optimal therapy of CL is still insufficient, i.e. certain modes of therapy effective for one *Leishmania* species may not be that effective for another. Hence, it is suggested that opinion of topical medicine consultant should be obtained to improvise the therapy according to regionally predominant species of *Leishmania*.<sup>11</sup> The proper investigations to identify the particular species of *Leishmania* including PCR should be done before starting therapy. In a developing

country, usually there is often only one species present in a particular locality, so diagnosing few cases may provide a guidance to the prevalent species in that area. Unfortunately, leishmaniasis has been a neglected disease. Also, the available therapeutic options have significant side-effects and toxicity.<sup>12</sup>

Therapeutic systemic therapy for *Leishmania* include the pentavalent antimony compounds; i.e. Sodium stibogluconate and Meglumine antimonite. certain other modes of therapy being used are intravenous Amphotericin B (lipid formula based), topical paromomycin sulfate, local heat application, or freezing with liquid nitrogen.<sup>9,13</sup> However, limited number of case reports and case series have focused on efficacy of PDT for CL management.<sup>9,13-15</sup> The topical PDT is an innovative therapy that works on basic principle of targeted absorption of photosensitizing agent by CL lesions. the tissues are exposed to specific light source. As a result, reactive oxygen species are formed in tissues with destruction of the target cells finally.<sup>16</sup> Asilian et al<sup>17</sup> in his study has found excellent response to PDT with 93.5% parasite free cases and declared effective therapy.

However, there is need for further randomized trials with a longer study duration and better sample size to determine and compare the efficacy of PDT with other treatment options being practiced. Currently available data on CL is limited, therefore, with reference to the above mentioned therapeutic challenges; we have conducted this study to determine the efficacy of topical photodynamic therapy of CL in our population. Hence, on the basis of the results, certain practical recommendations can be made in our routine practice guidelines for management of CL in our region.

## MATERIALS AND METHODS

This descriptive cross sectional study was conducted upon 75 patients with CL lesions (proved by biopsy) and age >12 years after ethical approval from institutional review board form July 2015 to Jan 2016. Patients of both the genders presenting to outpatient Dermatology Department of PIMS Hospital, Islamabad

were included after informed consent by non-probability convenience sampling. Sample size was calculated by WHO sample size calculator, taking confidence interval 95%, precision 6% and expected efficacy of photodynamic therapy in CL as 93.5%.<sup>17</sup>

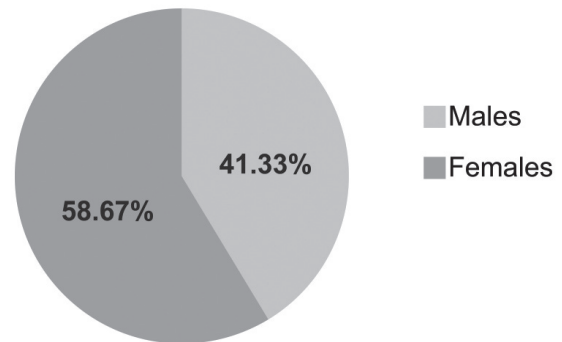
The pregnant and lactating women, sensitivity to Light or Photosensitizer and porphyria cases were excluded. All selected patients were administered 5-ALA PDT sessions topically once a week till 4weeks duration. Local application of freshly prepared water-in-oil emulsion of 10% 5-Aminolevulinic acid (ALA) was applied under occlusion that was kept for 4 hours. The accumulation of photo-sensitizer in the CL lesions was clinically labelled by fluorescence of ALA-induced porphyrins by examination under Woods lamp. The CL lesions were irradiated by exposure from Diode laser to red light (630 nm wavelength). The energy was delivered at the rate of and 100 J/cm<sup>2</sup> and intensity of 150 mW/cm<sup>2</sup> during each session. Once a week therapeutic sessions were conducted till 4 weeks and at 6<sup>th</sup> week of treatment, efficacy was noted as yes if there was no erythema, papules, plaques or nodules have disappeared, the surrounding skin is clinically normal and the histological smears were negative for amastigotes. The clinical and histological data was photographically recorded during whole study period.

Frequency and percentage was calculated for qualitative variables (gender and efficacy). Effect modifiers like age, gender, size of lesion and duration of disease were controlled through stratification; and post-stratification chi square was applied to see their effect on outcome. P-value < 0.05 considered as statistically significant.

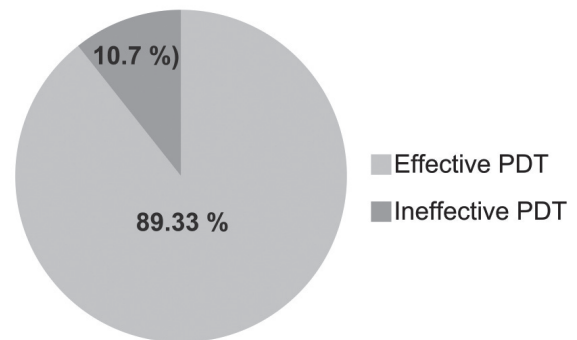
**RESULTS**

Among 75 cases, mean age was 24.37+7.43 years (12-75 years). There were 44(58.67%) females and 31(41.33%) males with ratio of 1.42:1 (Figure-1). Majority of the patients i.e. 39% were between 21 to 30 years of age. Mean duration of disease was 40.29+ 11.73 days and mean size of lesions was 19.69+9.88 mm.

The effective PDT (i.e. no erythema with resolution of papules, plaques or nodules, surrounded by normal healthy skin clinically and the histopathological smears revealing absence of amastigotes) was seen in 67(89.33%) patients while remaining 8(10.67%) demonstrated no efficacy at 6<sup>th</sup> week of therapy. Stratification of patients with respect to age groups and gender showed no significant association to efficacy of PDT (Table-I). Also the duration of disease and size of lesion was not found to be associated with efficacy of PDT, however efficacy was found to be inversely proportional to duration of disease and the size of CL lesion.



**Figure-1. Cutaneous leishmaniasis cases according to gender (n=75).**



**Figure-2. Efficacy of photodynamic therapy in cutaneous leishmaniasis cases (n=75)**

**DISCUSSION**

The CL usually leads to involvement of skin only. It may be present with a single lesion or up to more than dozen lesions. The lesions have varying characteristic appearances and distribution depending upon the species of Leishmania; i.e. ulcers, smooth nodules, flat plaques or hyperkeratotic lesions that resemble warts.

Variable		Efficacy		P-Value
		Yes (n=67)	No (n=8)	
Age Groups	12-20	13(92.86%)	1(7.14%)	0.947*
	21-30	26(89.66%)	3(10.34%)	
	31-40	11(91.67%)	1(8.33%)	
	41-50	10(83.33%)	2(16.67%)	
	51-65	7(87.50%)	1(12.50%)	
Gender	Male	29(93.55%)	2(6.45%)	0.321*
	Female	38(86.36%)	6(13.64%)	
Duration of Lesion	< 28 days	46(93.88%)	3(6.12%)	0.080*
	>28 days	21(80.77%)	5(19.23%)	
Size of Lesion	<15 mm	39(95.12%)	2(4.88%)	0.075*
	>15 mm	28(82.35%)	6 (17.65%)	

**Table-I. The efficacy of photodynamic therapy with respect to age, gender, duration and size of cutaneous leishmaniasis lesions (n=75)**

(\*Test of significance Chi-square test; significant p<0.05)

Usually, early lesions are papules that develop on skin being exposed to sand fly. Most lesions remain restricted to sand fly exposed area, however the secondary skin lesions may develop as a result of spread of parasites through lymphatics. Occasionally parasites may spread to mucosa of other body parts as well.<sup>18,19</sup> The regional lymphadenopathy may sometimes develop. Mostly the lesions aren't painful; however they may become painful if secondarily infected. Except in the ear, where ulcers remain restricted to skin and do not affect the subcutaneous tissues. maximum number of lesions have heal spontaneously; however, the duration of healing is variable and depends upon the species of Leishmania.<sup>20</sup> In few cases, ulcers make take several months to year to heal. There may be permanent scarring and disfigurement with forms of Leishmania. The HIV patients, that are immune-compromised as well, can develop severe form of disease that is resistant to treatment, with higher chances of visceral involvement and complications. Similarly, patients on long term steroids or immunosuppressive therapy may also present with exceptionally severe form of leishmaniasis.<sup>21,22</sup>

The skin scrapings, impression smears or biopsy of skin can be directly visualized under microscope to observe parasites. Also, the PCR test can be used as per availability and affordability. Leishmania species can also be cultured though different strains are required for

different species and cultures may yield false negative results in some cases.<sup>23,24</sup> Currently, the treatment of CL involves antimony compounds like meglumine antimoniate, sodium stibogluconate, ketaconazole, amphotericin B, etc. Most of these compounds have incidence of severe side effects due to their narrow therapeutic windows (i.e., the minimum doses that have therapeutic effect and do not cause toxicity). The other treatment modalities are under research, i.e. by using heat and cold therapies and their result are found to be comparable to currently available regimens. Certain researches have proved the efficacy of these alternative treatments, either used individually or as an adjunct to traditional therapy. The three investigated alternative therapies being practiced are heat, cold, and photodynamic therapies. These modalities are readily used particularly in remote areas with limited number of facilities and resources.<sup>25</sup>

The PDT works on the principle based on the damage caused in affected tissues or the infecting microorganisms, secondary to reactions that occur by exposure to light source. These reactions are labeled as photosensitization reactions. The process of photosensitization occurs when photosensitizer absorbs light and transfers its energy to neighboring molecules. As a result, light is converted into chemical reactivity. As a result of this photocycle, the PS regains ground state and may then absorb another photon. After this photo-physical step, there is formation of an

efficient PS is the intersystem crossing (ICS). It transforms singlet into triplet species, that have prolonged life.<sup>26</sup> We have conducted this study to determine the efficacy of Photodynamic therapy in the treatment of CL that is based on above mentioned principle.

The CL may affect all age groups. Reports from Afghanistan and Colombia show that adolescents and young adults are at maximal risk. However In Iran, most cases are reported in infants.<sup>27,28</sup> The mean age of patients in our study was  $24.37 \pm 7.43$  years with majority of the patients 29(38.67%) were between 21 to 30 years of age. These results are very much comparable with research conducted by Asilian et al<sup>16</sup> who had a mean age of 25 years but higher than Gardlo K et al<sup>14</sup> and Gardlo K et al<sup>15</sup> who had a mean age of 29 and 31 years respectively. In our study, 58.67% cases were females and 41.33% males with a ratio of 1.42:1. Many previous studies have also shown female predominance as observed in our study.<sup>14-16,27</sup> Authors also suggest that larger scale study may enhance these results and provide more reliable data regarding female gender predominance.

In our study, efficacy of PDT was seen in significant number of cases; i.e. 89.33% CL patients while rest of 10.67% cases had shown no efficacy at 6<sup>th</sup> week of treatment. Gardlo K et al<sup>15</sup> in his study compared the PDT with paromomycin sulfate in 10 lesions of CL. He found that all five PDT treated lesions and two of the paromomycin sulfate-treated plaques were negative for Leishmania, that was proven by clinical and histological examination. The three lesions with poor response to paromomycin sulfate at final observation were then treated with additional PDT that yielded good response. Also, after ten months of treatment, there wasn't any relapse of CL and the cosmetic results were excellent after PDT.

In a randomized clinical trial, Asilian et al<sup>17</sup> proved the efficacy of PDT in the treatment of CL. Sixty patients with confirmed CL by clinical and parasitological diagnosis were divided into three groups with different modes of treatment.

Group 1 was treated with PDT once a week, group 2 received twice a day paramomycin along with methyl-benzethonium chloride ointment and group 3 received paraffin based ointment without active ingredients. The treatment was carried on for a month in each group. At the end of the study healing was present in 93.5% in group 1, 41.2% in group 2 and 13.3% in group 3. At the same time, 100%, 64.7% and 20% of the lesions were found to be parasite negative in group 1, 2 and 3, respectively. These results prove the efficacy of PDT in CL cases.

In another study conducted by Enk et al<sup>29</sup>, an effective response to PDT was observed in as large as 31 lesions out of 32. These lesions were amastigote free after one or two sessions of PDT. The partial response to PDT was seen in 74.2% of lesions by one week therapy. However, only 26.5% of lesions managed with topical paromomycin and none of the placebo group had partial response to therapy. These findings prove that PDT has quick and effective action on lesions. It leads to the flattening of lesions, reduction in their size and induration. Ghaffarifar et al<sup>30</sup> in his study found that sixty percent cases were amastigote negative after single dose of PDT session and forty percent after two sessions.

The efficacy of PDT in animal models especially murines has been studied in certain international studies. Akilov et al<sup>31</sup> in 2007 conducted a research on use of ALA in CL lesions in the ears of mice. He also studies the action of ALA-PDT vs. ALA in murine with leishmaniasis. The parasites were significantly reduced (24.5 folds) in the PDT treated cases vs. the ALA treated. Certain studies from Iran and Germany had comparable results.

Current study proves that PDT is treatment modality that can achieve results above 90% healing of wounds. However, results of current study should be interpreted carefully as certain studies indicate that not all healed wounds become free of parasites.<sup>30,32</sup> The mechanism of ALA PDT in the case of leishmaniasis has been shown to be due to killing of infected host cells i.e. macrophages rather than direct killing of parasites. Hence, it is concluded that topical PDT

is an effective option for treatment of CL.

There is limited regional data available on CL. Certain limitations of the study include the sampling technique and sample size. CL being a comparatively rare disease with even fewer cases approaching health care facility from remote areas, the multicenter collection of data may lead to better sample size. Authors suggest careful interpretation of results of current study in view of these limitations. Current study will be helpful to compare our regional data with international studies. Hence the attending Dermatologist/Physician can implement a management plan that is effective and curative for CL cases.

## CONCLUSIONS

This study concluded that topical photodynamic therapy is an effective method for the treatment of Cutaneous Leishmaniasis with success rate of 89%. So, we recommend that topical photodynamic therapy should be used as a first line therapy in the treatment of Cutaneous Leishmaniasis in order to improve the social life, emotional well-being and leisure activities of Cutaneous Leishmaniasis patients.




Copyright© 31 Sep, 2018.

## REFERENCES

- James, William D.; Berger, Timothy G. **Andrews' diseases of the skin: Clinical dermatology**. Saunders Elsevier. 2006.
- Herwaldt BL. **Leishmaniasis**. *Lancet*. 1999; 354:1191-99.
- Nazari N, Faraji R, Vejdani M, Mekaieili A, Hamzavi Y. **The prevalence of cutaneous leishmaniasis in patients referred to kermanshah hygienic centers**. *Zahedan J Res Med Sci*. 2012; 14(8):77-79.
- Blum J, Desjeux P, Schwartz E, Beck B, Hatz C. **Treatment of CL among travellers**. *J Antimicrob Chemother*. 2004; 53:158-66.
- Moosavi Z, Nakhli A, Rassaii S. **Comparing the efficiency of topical paromomycine with intralesional meglumine antimoniate for CL**. *Int J Dermatol*. 2005; 44:1064-5.
- Dedet JP. **Leishmanioses tegumentaires**. In: Dedet JP, editor. *Les leishmanioses*. Paris: Ellipses; 1999; p. 173-8.
- Dedet JP. **Epidémiologie des leishmanioses du Nouveau Monde**. In: Dedet JP, editor. *Les leishmanioses*. Paris: Ellipses; 1999; p.147-60.
- Murray HW, Berman JD, Davies CR, Saravia NG. **Advances in leishmaniasis**. *Lancet*. 2005; 366:1561-77.
- Barnes JC, Stanley O, Craig TM. **Diffuse CL in a cat**. *J Am Vet Med Assoc*. 1993; 202(3):416-8.
- Ikram M, Khan RU, Firdous S, Atif M, Nawaz M. **Photodynamic therapy of Non-Melanoma skin cancers**. *Laser Phys*. 2011; 21(2):427-33.
- Bailey MS, Lockwood DN. CL. *Clin dermatol*. 2007; 25(2):203-11.
- Neuber H. **Leishmaniasis**. *J Dtsch Dermatol Ges*. 2008; 6(9): 754-65.
- Enk CD, Fritsch C, Jonas F, Nasereddin A, Ingber A, Jaffe CL, et al. **Treatment of CL with photodynamic therapy**. *Arch Dermatol*. 2003; 139:432-4.
- Gardlo K, Horska Z, Enk CD, Rauch L, Megahed M, Ruzicka T, et al. **Treatment of CL by photodynamic therapy**. *J Am Acad Dermatol*. 2003; 48:893-6.
- Gardlo K, Hanneken S, Ruzicka T, Neumann NJ. **Photodynamic therapy of CL. A promising new therapeutic modality**. *Hautarzt*. 2004; 55:381-3.
- Ibbotson SH. **Topical 5-aminolaevulinic acid photodynamic therapy for the treatment of skin conditions other than non-melanoma skin cancer**. *Br J Dermatol*. 2002; 146:178-88.
- Asilian A, Davami M. **Comparison between the efficacy of photodynamic therapy and topical paromomycin in the treatment of old world CL: A placebo-controlled, randomized clinical trial**. *Indian J Dermatol*. 2006; 51:182-5.
- Centers for Disease Control and Prevention. Parasites home: Leishmaniasis. Resources for health professionals**. Available at [http://www.cdc.gov/parasites/leishmaniasis/health\\_professionals/](http://www.cdc.gov/parasites/leishmaniasis/health_professionals/). Accessed April 10, 2014.
- Asilian A, Sharif A, Faghihi G, Enshaeieh S, Shariati F, Siadat AH. **Evaluation of CO laser efficacy in the treatment of CL**. *Int J Dermatol*. 2004; 43:736-8.
- Baron S, Laube S, Raafat F, Moss C. **CL in a Kosovan child treated with oral fluconazole**. *Clin Exp Dermatol*. 2004; 29:546-7.

21. Prata A, Silva-Vergara ML, Costa L, Rocha A, Krolewiecki A, Silva JC, et al. **Efficacy of azithromycin in the treatment of CL.** *Rev Soc Bras Med Trop.* 2003; 36:65–9.
22. Silva-Vergara ML, Silva LA, Maneira FRZ, Silva AG, Prata A. **Case report: Azithromycine in the treatment of mucosal leishmaniasis.** *Rev Inst Med Trop S Paulo.* 2004; 46:175–7.
23. El-On J, Katz M, Weinrauch L. **Treatment of CL by photodynamic therapy.** *J Am Acad Dermatol.* 2004; 50:e12.
24. Saenz RE, Paz H, Berman JD. **Efficacy of ketoconazole against Leishmania braziliensis panamensis CL.** *Am J Med.* 1990; 89:147–55.
25. Kunzler B. **Cutaneous leishmaniasis: The efficacy of non-antimony treatment in the austere environment. Using cryotherapy, thermotherapy, and photodynamic therapy as an alternative method of treatment.** *J Spec Oper Med.* 2013; 13(4):40-5.
26. Wilkinson F, Helman WP, Ross AB. **Rate constants for the decay and reactions of the lowest electronically excited singlet state of molecular oxygen in solution.** An expanded and revised compilation. *J Phys Chem.* 1993; 22:113.
27. **Centers for Disease Control and Prevention. Parasites home: Leishmaniasis.** Epidemiology & risk factors. Available at <http://www.cdc.gov/parasites/leishmaniasis/epi.html>. Accessed April 11, 2014.
28. Cardo LJ, Rentas FJ, Ketchum L, Salata J, Harman R, Melvin W, et al. **Pathogen inactivation of Leishmania donovani infantum in plasma and platelet concentrates using riboflavin and ultraviolet light.** *Vox Sang.* Feb 2006; 90(2):85-91.
29. Cardo LJ, Rentas FJ, Ketchum L, Salata J, Harman R, Melvin W, et al. **Pathogen inactivation of Leishmania donovani infantum in plasma and platelet concentrates using riboflavin and ultraviolet light.** *Vox Sang.* Feb 2006; 90(2):85-91.
30. Enk CD, Fritsch C, Jonas F. **Treatment of CL with photodynamic therapy.** *Arch Dermatol.* 2003; 139:432-4.
31. Ghaffarifar F, Jorjani O, Mirshams M, Miranbaygi MH, Hosseini ZK. **Photodynamic therapy as a new treatment of CL.** *La Revue de Santé de la Méditerranée orientale.* 2006; 12(6):902-8.
32. Akilov OE, Kosaka S, O’Riordan K, Hasan T. **Photodynamic therapy for CL: The effectiveness of topical phenothiaziniums in parasite eradication and Th1 immune response stimulation.** *Photochem Photobiol Sci.* 2007; 6:1067-75.
33. Bonnett R, Benzie R, Grahn MF, Salgado A, Valles MA. **Photodynamic therapy photosensitizers derived from chlorophyll.** *A Proc Spie.* 1994; 2078:71.

### AUTHORSHIP AND CONTRIBUTION DECLARATION

Sr. #	Author-s Full Name	Contribution to the paper	Author=s Signature
1	Mahvish Aftab Khan	Data collection, Methodology, Write up, Statistics, Discussion.	
2	Sehrish Aftab	Data collection, Write up, Referencing, Literature review.	
3	Nadia Shams	Data collection, Write up, Literature review.	
4	Rahmat Ullah Khan	Data collection and literature review.	