



CLINICAL EXPERIENCE WITH FLAP RECONSTRUCTION OF POST TUMOR EXCISION HEAD AND NECK DEFECTS.

Imran Adeel¹, Ghazanfar Ali², Irem Zoya Tariq³

1. MBBS, FCPS (Plastic Surgery)
Senior Registrar
Department of Plastic Surgery
Bahawal Victoria Hospital,
Bahawalpur.
2. MBBS, FCPS (Surgery), FCPS
(Plastic Surgery)
Assistant Professor
Department of Plastic Surgery
Quetta Institute of Medical Sciences
Quetta.
3. MBBS
Ex-House Officer
Nishtar Hospital, Multan.

Correspondence Address:

Dr. Imran Adeel
Department of Plastic Surgery
Bahawal Victoria Hospital, Bahawalpur.
Imran_adeel17@yahoo.com

Article received on:

15/05/2018

Accepted for publication:

25/10/2018

Received after proof reading:

22/05/2019

ABSTRACT... Soft tissue reconstruction of defects after excision of head & neck malignancies is one of the difficult tasks for plastic surgeons and it has always been a challenge for plastic surgeons to seek options which are safe & with less morbidity and good functional and aesthetic outcomes. Multiple options are available for reconstruction purpose, ranging from simpler options in the form of primary closure and skin grafting, to more complex reconstruction with flaps. Flap coverage is more reliable over simpler options, in terms of functional and aesthetic outcome for the management of head and neck malignancies. The purpose of this study is to determine the role of different types of flaps for the soft tissue reconstruction in the management of head and neck malignancies, and reliability of local flap coverage in the management of head and neck malignancies. **Study Design:** Retrospective case series. **Setting:** This study was conducted at the department of Plastic and Reconstructive Surgery, Shaikh Zayed Postgraduate Medical Institute, Lahore. **Period:** 5 years from 2009 to 2013. **Materials and Methods:** A total of 63 patients, with diagnosis of head and malignancies, were studied retrospectively over a period of 5 years from June 2009 to June 2013. Age ranged from 18 to 80 years (mean: 59.17 years). There were 30 males (47.61%) and 33 females (52.38%). Soft tissue reconstruction was done with different types of local and distant flaps. **Results:** A total of 65 different types of flaps were done for the reconstruction purpose. Local flaps were done in 42 (68%) cases, regional flaps were done in 15 (23%) cases and in 6 (9%) cases, free tissue transfer was done. In two cases more than one flap were used for reconstruction. Neck dissection was done in 13(21.74%) of the cases. Good results were achieved in all cases with respect to functional and aesthetic outcome. **Conclusion:** Despite of the intricate anatomy of head and neck region and the challenging reconstruction, flap reconstruction is a reliable option with good functional and aesthetic outcome and most of the soft tissue reconstruction can be achieved with different local flaps, depending on the extent of soft tissue defect.

Key words: Flap, Free tissue transfer, Squamous cell carcinoma, Soft Tissue Reconstruction

Article Citation: Adeel I, Ali G, Tariq IZ. Flap reconstruction; clinical experience with flap reconstruction of post tumor excision head and neck defects. Professional Med J 2019; 26(6):929-933. DOI: 10.29309/TPMJ/2019.26.05.3599

INTRODUCTION

Head and neck malignancies are among the common malignancies which a surgeon deals in his routine practice and most of these are soft tissue in origin. Squamous cell carcinoma comprises 90% of the head and neck malignancies. Reconstruction in these patients pose a challenge to plastics surgeons because of the intricate anatomy and specific attributes associated with head and neck region and the functional and aesthetic concerns of patients.

The goals of reconstruction in the head and neck region include both functional as well as aesthetic

concerns of the patients.

Multiple reconstructive options are available for the management of head and neck malignancies, which range for simpler ones in the form of primary closure and skin grafting, to more complex flap reconstruction. All of them have some advantage over the other. Superficial soft tissue defects can be reconstructed with split skin grafts. However, despite their ease and faster take, graft contraction continues to be a problem. Moreover, graft coverage has poor aesthetic and functional results as compared to the flaps for head and neck region. In addition, if deeper tissues are

involved, their applicability is limited.

Flap coverage has always been a reliable option for reconstruction in the head and neck region for the management of malignant lesions, because of the more natural functional and aesthetic outcome in terms of color match, texture and soft tissue.^{1,2}

Flap options include tissue taken from the surrounding area locally, regional flaps³ and distant flaps including free tissue transfer.⁴

In this article, we share our 5 years clinical experience of different types of flaps used for reconstruction purpose in the management of soft tissue malignancies of head and neck region.

PATIENT AND METHODS

During a period of 5 years between June 2008 to June 2013, a total of 63 cases with diagnosis of head and malignancies were underwent flap reconstruction after surgical excision. 33 of these patients were female and 30 were male. Ages ranged from 18 years to 80 years with mean age 59.17 years. Out of 63 cases, 32 cases were of basal cell carcinoma (50.79%), 24 cases were of Squamous cell carcinoma (38.09%), 4 cases of basisquamous carcinoma (6.34%), 1 case of malignant melanoma (1.58%) and 2 cases cystadenocarcinoma (3.17%). 16 cases (25.39%) were of locally advanced disease with involvement of surrounding structures. Lymph node involvement was found in 9 cases (14.28%).

PROCEDURE

In all the cases, surgical excision was done with excision of healthy margins according to standard protocol for each type of tumor. Reconstruction of defect after excision was done with local flaps in 42 cases (68%); regional flaps were used in 15 cases (23%) and, in only 6 cases (9%), free tissue transfer was done. Out of local flaps, forehead flap was done in 5 cases⁷, cheek rotation flap was done in 8 cases, nasolabial flap was done in 5 cases³, Abbe Estlander flap was done in 6 cases, limberg flap was done in 8 cases, glabellar flap was done in 5, dorsal nasal flap was done in 2 cases and Karapandzic flap was done in 3

cases. Of regional flaps, supraclavicular flap was done in 3 cases, temporoparietal fascial flap was done in 4 cases, temporalis muscle flap in 4 cases, pec major myocutaneous flap in 3 cases and trapezius myocutaneous flap was done in 1 case. Free radial forearm flap was done in 3 cases, free rectus abdominus myocutaneous flap was done in 1 case and free ALT Flap in 2 cases. Neck dissection was done in 13 cases. Cases were done under general and local anesthesia depending on the extent of surgery. Donor site closure was done primarily in 54 cases and in 9 cases, split thickness skin grafting was done.

RESULTS

All the cases were followed for at least 3 months after the procedure, for flap survival, on outpatient bases. Flap survival was found in 100% cases. Good results were achieved in all cases with respect to functional and aesthetic outcome. Flap debulking was done in 6 cases.

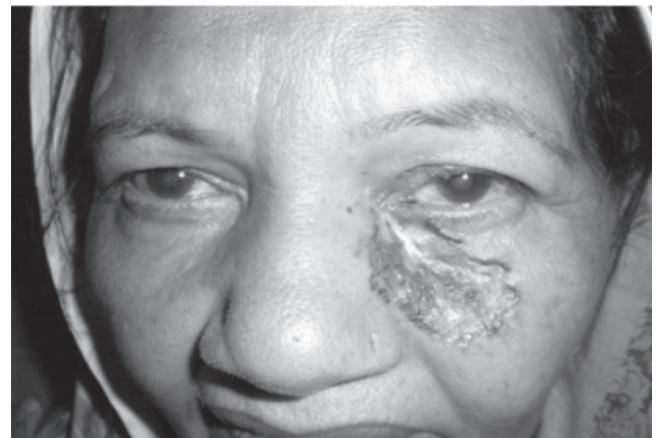


Figure-1a. Basal cell carcinoma cheek

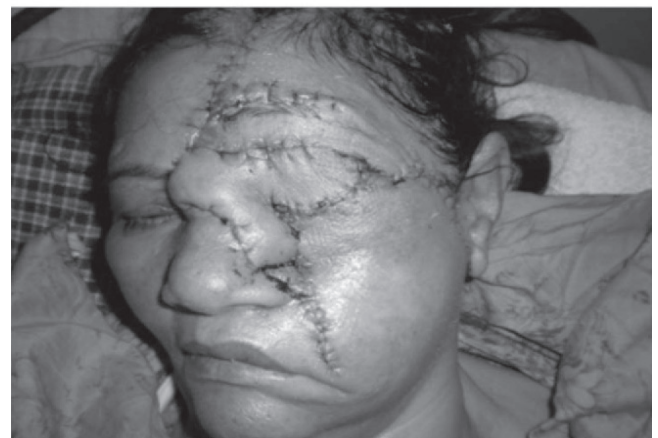

Figure-1b. Coverage with forehead flap

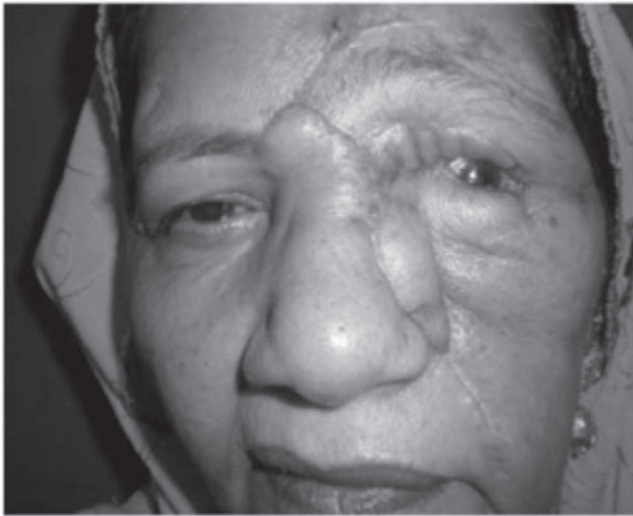


Figure-1c. Follow up after 6 months




Figure-2c. Follow up after 1 year

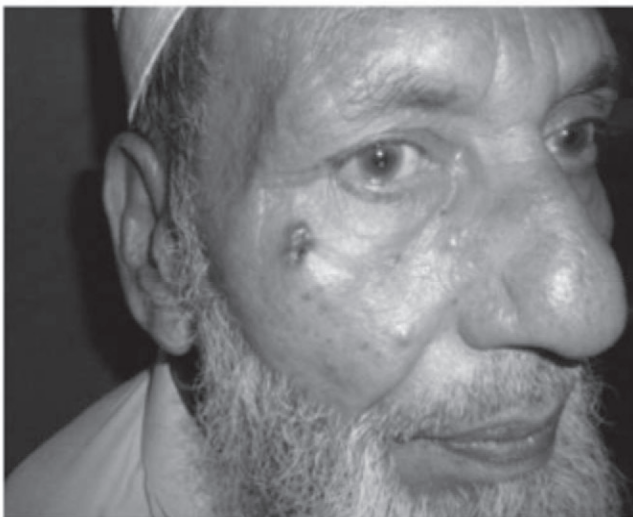

Figure-2a. Nodular Basal Cell Carcinoma right cheek

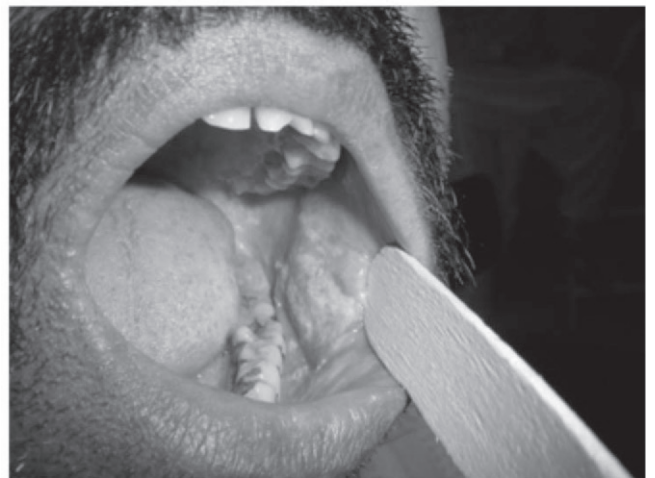

Figure-3a. Squamous cell carcinoma left buccal mucosa

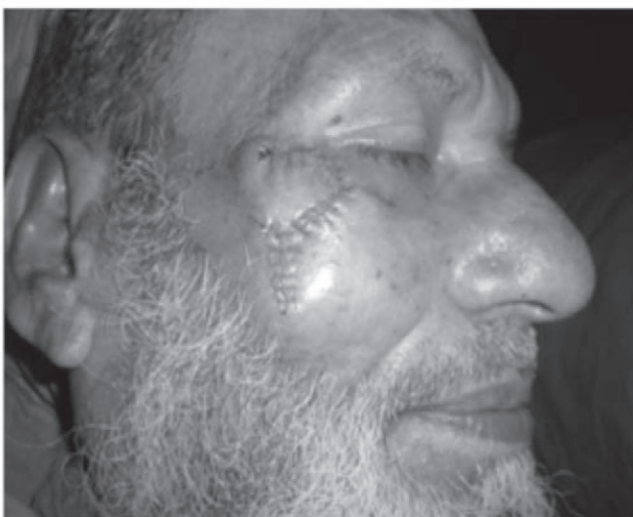

Figure-2b. Coverage with Limberg flap

DISCUSSION

Because of the special attributes of the head and neck region, functional and aesthetic concerns and presence of vital structures in head and neck region, it becomes very challenging for a plastic surgeon to deal with reconstruction of defects in this region. It becomes even more challenging while dealing with the malignant lesions of head and neck region because of the post operative concerns of adjuvant therapies.

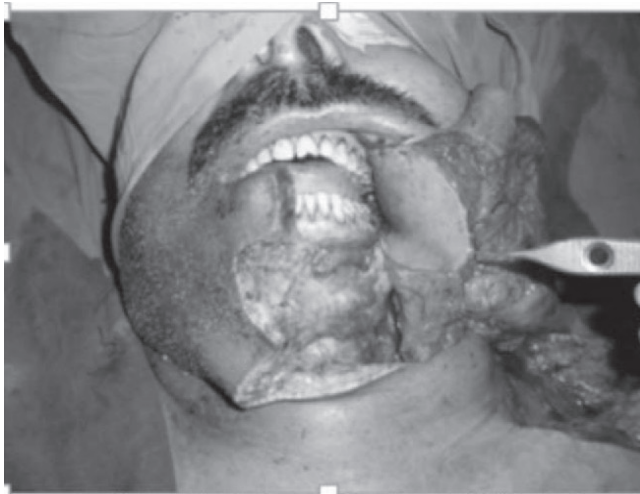

Figure-3b. Coverage with supraclavicular flap

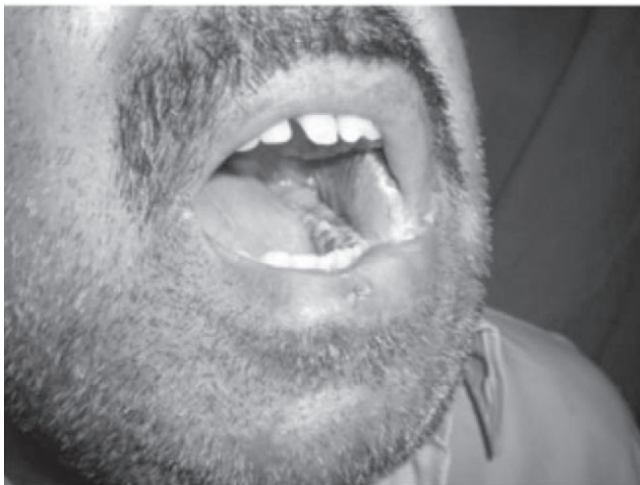

Figure-3c. 10 days follow up

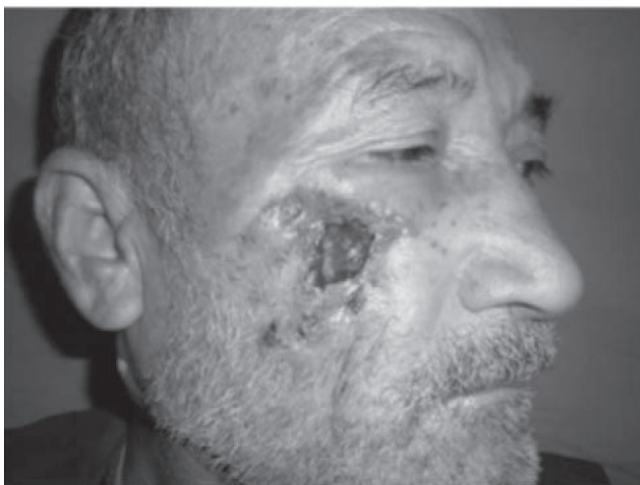

Figure-4a. Basal cell carcinoma right cheek

Multiple options are available for reconstruction but the real challenge comes when choosing a particular reconstructive option.

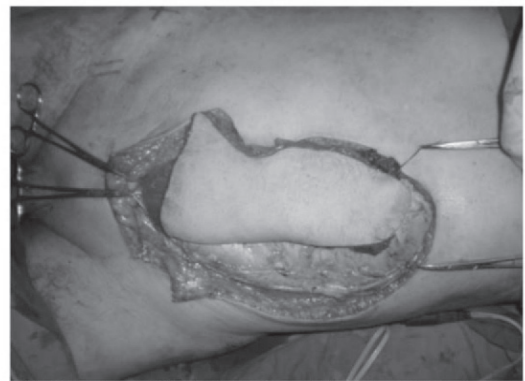


Figure-4b. Coverage with Free rectus abdominus myocutaneous flap

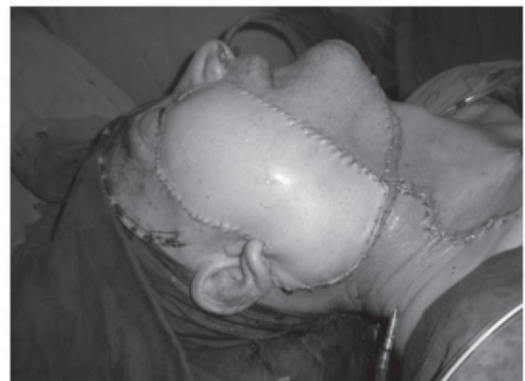

Figure-4c. Immediate post-op

Every option has some advantage over the others. Local tissue flaps are best for head and neck reconstruction because of the color and texture match but they also have few limitations. Local flaps have smaller dimensions, so not suitable for larger defects. They are less bulky and so not effective for deeper defects. Regional flaps can be used for larger defects but they have issues with color match, texture and they may be more bulky for the defects, so might need revision surgeries later on. Donor site morbidity is another issue. The advent of microsurgery has revolutionized the reconstructive surgery because of the liberty in choice of tissue for reconstruction, but it requires microsurgical equipment and expertise, prolonged operative times and donor site morbidity. Before going for reconstruction in head and neck region, careful planning is of utmost importance. Total size and depth of defect, color and texture match, tissues needed to be reconstructed, should be kept in mind before choosing a particular flap for reconstruction. In most of the cases, local flaps can be used for reconstruction, but when needed, regional and distant flaps should be used for reconstruction,

depending on the defect.²

CONCLUSION



Despite of challenging reconstruction in the head and neck region for malignant lesion, careful planning can produce favorable functional and aesthetic results. For smaller defects, local flaps are the ideal one. More complex reconstruction can be done in others according to the complexity of final defect.

Copyright© 25 Oct, 2018.

REFERENCES

1. Baliarsing AS, Thorat T, Gupta A, Bhat U, Garg S, Bhattacharyya D. **Flap selection in head and neck cancer reconstruction.** *Int J Otorhinolaryngol Clin* 2013; 5(2):63-76.
2. Chim H, Salgado CJ, et al. **Principles of head and neck reconstruction: An algorithm to guide flap selection.** *Semin Plast Surg.* 2010 May; 24(2): 148-154.
3. Colletti G, et al. **Regional flaps in head and neck reconstruction: A reappraisal.** *J Oral maxillofac Surg.* 2015.
4. Rinaldo A, Shaha AR, et al. **Microvascular free flaps: A major advance in head and neck reconstruction.** *Acta Otolaryngol.* 2002; 122: 779-784.
5. Singh S, Singh RK, Pandey M. **Nasolabial flap reconstruction in oral cancer.** *World Journal of Surgical Oncology.* 2012; 10:22.
6. Okoturo E. **Regional myocutaneous flaps for head and neck reconstruction: Experience of a head and neck cancer unit.** *Niger J Surg.* 2015 Jul-Dec; 21(2): 85-90.
7. Boyd CM, Baker SR, Fader DJ, Wang TS, Johnson TM. **The forehead flap for nasal reconstruction.** *Arch Dermatol.* 2000; 136(11):1365–1370. doi:10.1001/archderm.136.11.1365.

AUTHORSHIP AND CONTRIBUTION DECLARATION

Sr. #	Author-s Full Name	Contribution to the paper	Author=s Signature
1	Imran Adeel	Main Author	
2	Ghazanfar Ali	2nd Author, Final Proof reading.	
3	Irem Zoya Tariq	3rd Author, Composing & Proof reading.	