



1. MBBS, FCPS (General Surgery)  
Associate Professor  
North Surgery Department  
King Edward / Mayo Hospital Lahore.
2. MBBS, MRCS,  
FCPS (General Surgery)  
Assistant Professor  
North Surgery Department  
King Edward University Lahore.
3. MBBS  
Postgraduate Resident  
North Surgery Department  
Mayo Hospital  
King Edward Medical University  
Lahore.

**Correspondence Address:**  
Dr. Mohammad Sohail Asghar  
Postgraduate Resident  
Mayo Hospital King Edward  
Medical University Lahore.  
kdark7582@gmail.com

**Article received on:**  
23/04/2019

**Accepted for publication:**  
20/06/2019

**Received after proof reading:**  
30/09/2019

## A RARE PRESENTATION OF GIANT CYSTIC RETROPERITONEAL TERATOMA IN ADULT; A CASE REPORT.

Imran Aslam<sup>1</sup>, Balakh Sher Zaman<sup>2</sup>, Mohammad Sohail Asghar<sup>3</sup>

**ABSTRACT:** Teratoma are bizarre tumors of germ cell and are usually present in testis and ovaries and contains structures like hairs, teeth, bone, thyroid tissue or more complex organs. Retroperitoneal occurrence is an uncommon site of presentation. They are usually present in childhood and rarely in adults. Here we are discussing a rare case presentation of middle age female, presented with abdominal fullness and pain which later diagnosed as retroperitoneal teratoma on CT scan. Clinical presentation, workup, surgical management, and outcome is discussed in this study.

**Key words:** Teratoma, Retroperitoneal, Germ Cell.

**Article Citation:** Aslam I, Zaman B, Asghar MS. A rare presentation of giant cystic retroperitoneal teratoma in adult; a case report. Professional Med J 2019; 26(10):1805-1809. DOI: 10.29309/TPMJ/2019.26.10.3582

### INTRODUCTION

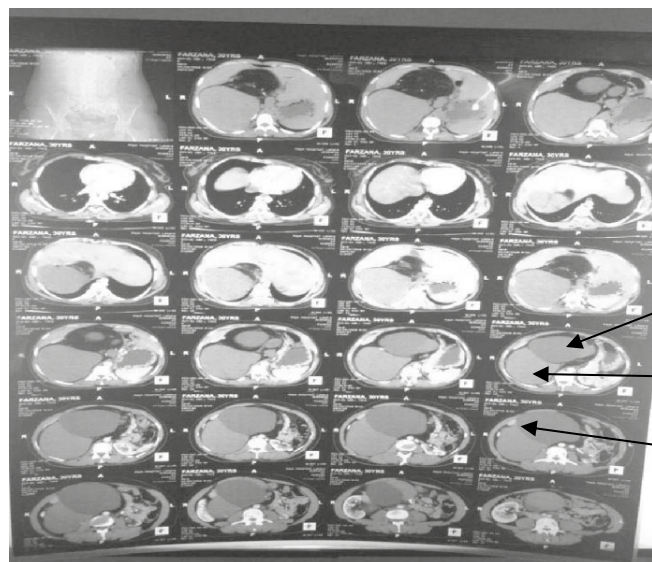
Teratoma is a germ cell tumor derived from primordial germ cells, which have the potential to differentiate into somatic cells.<sup>1</sup> They can be composed of somatic cell types from two or more germ layers (ectoderm, mesoderm or endoderm).<sup>2</sup> Teratomas are usually found in the gonadal organs, such as the ovaries and testes<sup>3</sup> and approximately 15% of all teratomas are extragonadal. The retroperitoneum is the least common location.<sup>4</sup> Retroperitoneal teratomas are rare in adults, typically occurring in this location only in infancy and childhood.<sup>5</sup> Mature cystic teratomas in the retroperitoneum are most commonly identified in the first 6 months of childhood and in early adulthood.<sup>6</sup> We are presenting a case of middle age female who was diagnosed with retroperitoneal cystic teratoma and is treated with surgical resection of the tumor.

### CASE PRESENTATION

A 30 years old female patient of south east asian origin presented in outpatient department of mayo hospital, with the history of occasional pain in epigastric region and left hypochondriac region from last one month. Pain was not associated with meals and was not radiating to back or anywhere else in the abdomen. Pain was dull in nature and

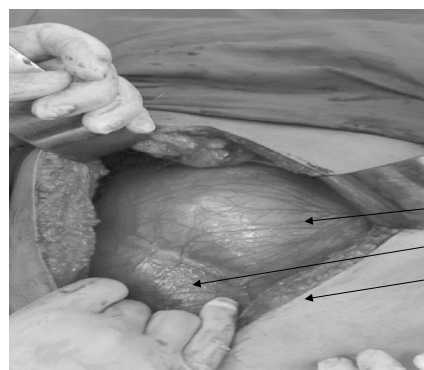
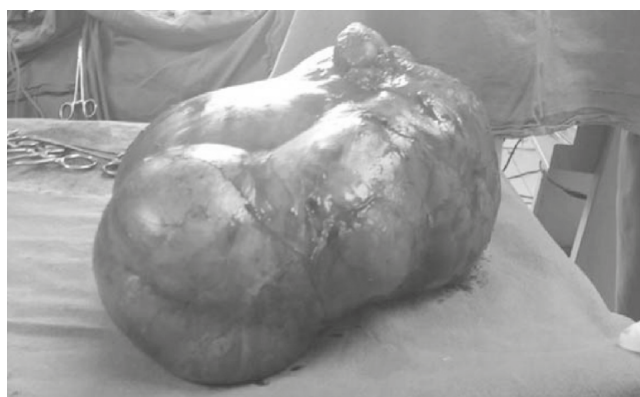does not aggravate with anything. She also had complains of epigastric fullness from many months. There was no history of nausea, vomiting, fever or constipation. She also had history of similar complain and got admitted in PIMS Islamabad. Her past history was insignificant for diabetes, hypertension, tuberculosis, ischemic heart disease or any pulmonary disease. She does not have any family history of congenital diseases. On her personal history, she does not smoke nor she an alcoholic. She had no personal history of any drug abuse. Her menstrual history was also insignificant and she is a house wife.

On general physical examination, she is middle aged female with no signs of any particular disease on inspection. On abdominal examination a mass of around 15 x 15 cm was present in epigastric region and extending to right hypogastric region. The mass was slight tender and had well defined margins and was immobile. Ultrasound abdomen was done which showed multiple large and small cysts in epigastric region with calcified areas present in the cyst. Her CT scan was done which showed a large cystic mass occupying the whole left lobe of liver measuring 13.4 x 9.4cm with calcific foci on each in the medial and lateral border of the cyst.



Cystic component of Tumor  
 Solid component of Tumor  
 IVC pushed to anterior abdominal wall

This patient was explored via midline incision, and per operatively it was found that a huge mass was present just below the liver extending from retroperitoneal region and displacing the inferior vena cava on the right and duodenum and hepatic flexure of colon inferiorly towards the pelvis, common bile duct and portal vein towards left. Left kidney was atrophied. The mass was well walled off and does not involve any major organ or vessel. Resection of the mass was done successfully with all the margins. Abdomen was lavaged with normal saline and sutured closed with prolene.



Tumor  
 IVC  
 Anterior abdominal wall

Resected specimen was 13x 15 x 13 cm retroperitoneal teratoma, cut sections was found to have yellowish cheesy liquid material with hairs and calcified teeth and bone like structures.

**HISTOPATHOLOGY REPORT**

Specimen:  
 EXCISION BIOPSY - RETROPERITONEAL CYST

**Gross Features:**

Specimen received fix in formalin and consists of cystic, fatty, soft tissue place 20x18x9cm. On cut section the cyst wall ranges from 2-5 cm. There are areas of cartilage in the cyst wall and sparse hair on the surface.

R/S taken in 6 Blocks

**Microscopic Features:**

Histological examination of the section reveals fatty neoplasm with stratified squamous lining at some foci with heterogeneous elements like bone, cartilage, muscle, sebaceous glands, ganglion cells, ciliated columnar epithelium with respiratory type submucous glands. In addition areas of lymphoid aggregates, mammary tissue and gastric mucosal glands are also seen. Foci of mature nervous tissue are also seen. However no immature element is seen in the submitted section.

NO EVIDENCE OF GRANULOMA FORMATION OR MALIGNANCY SEEN IN THE EXAMINED SECTIONS

**Opinion/Comments:**

EXCISION BIOPSY - RETROPERITONEAL CYST: MATURE TERATOMA

**DISCUSSION**

A teratoma is a tumor with tissue or organ components resembling normal derivatives of more than one germ layer. Although the teratoma may be monodermal or polydermal (originating from one or more germ layers), its

cells may differentiate in ways suggesting other germ layers. The tissues of a teratoma, although normal in themselves, may be quite different from surrounding tissues and may be highly disparate; teratomas have been reported to contain hair, teeth, bone and, very rarely, more complex organs.<sup>7,8</sup>

They are typically classified into three general categories: mature (cystic/solid, benign), immature (malignant), and mondermal (highly specialized).<sup>9</sup> A typical mature teratoma often contains components from each of the three germ layers, including lipid, epithelium, bone, cartilage, hair, fat, muscle and nerve tissue. Teratoma most commonly affects neonates and adolescents, and is mainly prevalent in women. The most common sites of occurrence are the gonads, namely the male testis and the female ovary, with extragonadal teratomas accounting for only 15% of all teratomas and often occurring in regions of the body axis, including the mediastinal and sacrococcygeal regions.<sup>10,11</sup>

Retroperitoneal teratomas are rare entities, representing only 1%–11% of all primary retroperitoneal tumors. Incidence is bimodal with peaks in the first 6 months of life and in early adulthood. Due to their location, they are usually identified only after they have grown to huge proportions.<sup>12</sup> Additionally, the incidence of retroperitoneal teratomas in females is twice that in males. When retroperitoneal teratomas do occur, they are often located near the upper pole of the kidney, with preponderance on the left side. Although these tumors are mostly asymptomatic, they can cause abdominal distension and pain, as well as nausea and vomiting via compression of surrounding structures.<sup>13</sup> Diagnostic techniques include ultrasound, magnetic resonance imaging and computed tomography. However, definitive diagnosis is based on tumor histology.<sup>14</sup> Retroperitoneal teratomas can be predominantly cystic or completely solid in appearance. A computed tomography (CT) scan or magnetic resonance image (MRI) can identify various components of these tumors, including bone, soft-tissue density structures, adipose tissue, and sebaceous and serous-type fluids. These imaging

studies also can display the precise location, morphology, and adjacent structures of the tumor, which provide better preoperative planning and increased likelihood of complete removal of the tumor with less iatrogenic damage.<sup>15</sup>

At present, the treatment of choice is complete surgical removal, which exhibits a good prognosis in benign teratomas, however, for malignant tumors; chemotherapy treatment is also administered following surgery.<sup>16</sup> A previous study of 183 infants and children diagnosed with teratoma, revealed that the 10-year event free and overall survival rates following surgery were 90.4% and 98.0% respectively.<sup>17</sup> Furthermore, immature teratomas are associated with a significantly higher mortality rate than mature teratomas.<sup>18</sup> Benign tumors, when resected, yield a 5-year survival rate of 100%. A long-term study showed that complete surgical resection is associated with the best survival rates for primary retroperitoneal tumors.<sup>19</sup> Depending on which tissue(s) it contains, a teratoma may secrete a variety of chemicals with systemic effects. Some teratomas secrete the “pregnancy hormone” human chorionic gonadotropin ( $\beta$ hCG), which can be used in clinical practice to monitor the successful treatment or relapse in patients with a known HCG-secreting teratoma. This hormone is not recommended as a diagnostic marker, because most teratomas do not secrete it. Adequate follow-up requires close observation, involving repeated physical examination, scanning (ultrasound, MRI, or CT), and measurement of AFP and/or  $\beta$ hCG.<sup>20</sup>

The present case reported a rare incidence of presence of huge retroperitoneal mature cystic teratoma with hair and teeth like structures in it. Tumor was resected successfully followed by uneventful recovery of the patient.

## CONCLUSION

Retroperitoneal teratomas are very rare in adults and usually present with abdominal distension, fullness and as a palpable mass. Abdominal ultrasound, Computed tomography and MRI aids in the diagnosis of the tumor whereas biopsy remains the gold standard for diagnosis. The mainstay of treatment is surgical resection



and post-operative follow up is required with ultrasound, CT scan and MRI.

Copyright© 20 June, 2019.

## REFERENCE

- Mikuz G, Colecchia M. **Teratoma with somatic-type malignant components of the testis.** A review and an update. *Virchows Archiv.* 2012 Jul 1;461(1):27-32.
- Barka M, Mallat F, Hmida W, Ahmed KB, Chavey SO, Abdallah AB, Tlili K. **Giant primary retroperitoneal teratoma in an adult male: A rare entity.** *Int J Case Rep Images.* 2014 Aug 1;5(8):558-61.
- Shindo K, Ueda J, Toubou T, Nakamura M, Oda Y, Eguchi T, Tanaka M. **Primary carcinoid tumor in a retroperitoneal mature teratoma: report of a case.** *Surgery today.* 2013 Jun 1;43(6):694-7.
- Bedri S, Erfanian K, Schwaizberg S, Tischler AS. **Mature cystic teratoma involving adrenal gland.** *Endocrine pathology.* 2002 Mar 1;13(1):59-64.
- Taori K, Rathod J, Deshmukh A, Singh Sheorain V, Jawale R, Sanyal R, Bhagat M, Jumle S. **Primary extragonadal retroperitoneal teratoma in an adult.** *The British journal of radiology.* 2006 Oct;79(946):e120-2.
- Gatcombe HG, Assikis V, Kooby D, Johnstone PA. **Primary retroperitoneal teratomas: a review of the literature.** *Journal of surgical oncology.* 2004 May 1;86(2):107-13.
- Chi JG, Lee YS, Park YS, Chang KY. s.l. **“Fetus-in-fetu: Report of a case.** *American Journal of Clinical Pathology* 82 (1), Vol. 01. 115–9 PMID 6540049.
- Sergi C, Ehemann V, Beedgen B, Linderkamp O, Otto HF. **Huge fetal sacrococcygeal teratoma with a completely formed eye and intratumoral DNA ploidy heterogeneity.** *Pediatric and Developmental Pathology.* 1999 Jan 1;2(1):50-7.
- Gershenson D. **Ovarian germ cell tumors: pathology, clinical manifestations, and diagnosis.** *UpToDate Patient Preview.* 2009.
- Shintani Y, Funaki S, Nakagiri T, Inoue M, Sawabata N, Minami M, Kadota Y, Okumura M. **Experience with thoroscopic resection for mediastinal mature teratoma: a retrospective analysis of 15 patients.** *Interactive cardiovascular and thoracic surgery.* 2013 Jan 3;16(4):441-4.
- Simpson PJ, Wise KB, Merchea A, Cheville JC, Moir C, Larson DW, Dozois EJ. **Surgical outcomes in adults with benign and malignant sacrococcygeal teratoma: a single-institution experience of 26 cases.** *Diseases of the Colon & Rectum.* 2014 Jul 1;57(7):851-7.
- Gatcombe HG, Assikis V, Kooby D, Johnstone PA. **Primary retroperitoneal teratomas: a review of the literature.** *Journal of surgical oncology.* 2004 May 1;86(2):107-13.
- Taori K, Rathod J, Deshmukh A, Singh Sheorain V, Jawale R, Sanyal R, Bhagat M, Jumle S. **Primary extragonadal retroperitoneal teratoma in an adult.** *The British journal of radiology.* 2006 Oct;79(946):e120-2.
- Peterson CM, Buckley C, Holley S, Menias CO. **Teratomas: a multimodality review.** *Current problems in diagnostic radiology.* 2012 Nov 1;41(6):210-9.
- Liu H, Li W, Yang W, Qi Y. **Giant retroperitoneal teratoma in an adult.** *The American Journal of Surgery.* 2007 Jun 1;193(6):736-7.
- Göbel U, Schneider DT, Calaminus G, Haas RJ, Schmidt P, Harms D. **GPOH MAKEI and the MAHO study groups. Germ-cell tumors in childhood and adolescence.** *Annals of oncology.* 2000 Mar 1;11(3):263-71.
- Curto ML, D’Angelo P, Cecchetto G, Klersy C, Dall’Igna P, Federico A, Siracusa F, Alaggio R, Bernini G, Conte M, De Laurentis T. **Mature and immature teratomas: results of the first paediatric Italian study.** *Pediatric surgery international.* 2007 Apr 1;23(4):315-22.
- Yoneda A, Usui N, Taguchi T, Kitano Y, Sago H, Kanamori Y, Nakamura T, Nosaka S, Oba MS. **Impact of the histological type on the prognosis of patients with prenatally diagnosed sacrococcygeal teratomas: the results of a nationwide Japanese survey.** *Pediatric surgery international.* 2013 Nov 1;29(11):1119-25.
- Pinson CW, ReMine SG, Fletcher WS, Braasch JW. **Long-term results with primary retroperitoneal tumors.** *Archives of surgery.* 1989 Oct 1;124(10):1168-73.
- Marina NM, Cushing B, Giller R, Cohen L, Lauer SJ, Ablin A, Weetman R, Cullen J, Rogers P, Vinocur C, Stolar C. **Complete surgical excision is effective treatment for children with immature teratomas with or without malignant elements: A Pediatric Oncology Group/Children’s Cancer Group Intergroup Study.** *Journal of clinical oncology.* 1999 Jul;17(7):2137-.

**AUTHORSHIP AND CONTRIBUTION DECLARATION**

Sr. #	Author-s Full Name	Contribution to the paper	Author's Signature
1	Imran Aslam	Main operating surgeon who approved (critical analysis).	
2	Balakhsher Zaman	Critical analysis literature review.	
3	M. Sohail Asghar	Write up grammar check bibliography.	