



## COMPARISON OF VESICOVAGINAL FISTULA REPAIR WITH OMENTAL TRANSPOSITION VERSUS PERIVESICAL FAT EMPLACEMENT.

1. MBBS, MS Urology  
Assistant Professor  
Department of Urology  
Peoples University of Medical and Health Sciences for Women  
Nawabshah.
2. MBBS, FCPS Urology  
Senior Registrar  
Department of Urology  
Peoples University of Medical and Health Sciences for Women  
Nawabshah.
3. MBBS, FCPS Urology  
Senior Registrar  
Department of Urology  
Peoples University of Medical and Health Sciences for Women  
Nawabshah.
4. MBBS, MS Urology  
Assistant Professor  
Department of Urology and Renal transplantation  
Gambat Institute of Medical Sciences Gambat.
5. MBBS, MS Urology  
Medical Officer  
Department of Urology Ward  
Peoples University of Medical and Health Sciences for Women  
Nawabshah.
6. MBBS, M.S (General Surgery)  
Assistant Professor  
Department of Anatomy  
Peoples University of Medical and Health Sciences for Women  
Nawabshah.

**Correspondence Address:**  
Dr. Aijaz Hussain Memon  
Peoples University of Medical and Health Sciences for Women  
Nawabshah.  
aijazmemonsba@gmail.com

**Article received on:**  
01/04/2019

**Accepted for publication:**  
25/06/2019

Aijaz Hussain Memon<sup>1</sup>, Mumtaz Ali<sup>2</sup>, Salman Manzoor Qureshi<sup>3</sup>, Wasim Sarwar Bhatti<sup>4</sup>, Naveed Ahmed<sup>5</sup>, Mujeeb ur Rehman<sup>6</sup>

**ABSTRACT... Objectives:** To compare the outcome of Vesicovaginal fistula repair by omental transposition and perivesical fat emplacement in terms of recurrence and maximum bladder capacity. **Study Design:** Randomized control trial. **Setting:** Urology department of Peoples University Hospital Nawabshah, Sindh, Pakistan. **Period:** From January 2018 to December 2018. **Material & Method:** Overall 40 patients with VVF were added in the research, split into two identical groups, each consisting of 20. In group 1, omental transposition and in group 2, perivesical fat emplacement was done. Adult female patients with Vesicovaginal fistula, resulting from obstetrical and as a complication of surgery was included. This was confirmed by physical examination, IVU, pelvic computerized tomography scan with contrast, retrograde urethrocystogram, ultrasound KUB and cystoscopy. Exclusion criteria were Patients with systemic illness like diabetes mellitus, chronic renal failure and chronic liver disease etc, immunosuppressant therapy like: steroids intake, patient's undergone irradiation of the pelvis due to any malignant disease. Follow up after 6, 12 and 24 weeks, all the patients were assessed for recurrence. The complications like wound infections, urgency, urge incontinence and paralytic ileus were also noted. The data was collected in a specially designed proforma. **Results:** In this study 40 patients fulfilling the inclusion criteria were included, 20 patients in each group. The success rate was 95 % ( 19 /20) in group 1, only one case had recurrence. While in group 2 all the cases were successful. Chi square analysis was employed for comparison of adequacy of both the techniques, the P value was found to be 0.311 which suggests that the difference between the efficacies was not statistically significant. **Conclusion:** It is concluded that both the techniques of Vesicovaginal fistula repair, either with omental transposition or perivesical fat emplacement are equally good in terms of recurrence and maximum bladder capacity.

**Key words:** Bladder Capacity, Recurrence, Vesico-Vaginal Fistula.

**Article Citation:** Memon AH, Ali M, Qureshi SM, Bhatti WS, Ahmed N, Mujeeb ur Rehman. Comparison of Vesicovaginal Fistula Repair with Omental transposition versus perivesical fat emplacement. Professional Med J 2019; 26(12):2146-2150. DOI: 10.29309/TPMJ/2019.26.12.3497

### INTRODUCTION

Vesicovaginal fistula (VVF) is a disastrous situation for women. Large VVF after an obstetrical trauma has been described since 2050BC.<sup>1</sup> It is an unusual connection between urinary bladder and vagina, causing continuous leakage of urine in the vagina.<sup>2</sup>

Vesicovaginal fistulae are usually due to bladder wall ischemia followed by necrosis during obstructed labor. Etiology of the obstetric fistula is absolutely distinct from surgical fistula. Vesicovaginal fistula may also result as a complication of pelvic surgery, i.e. injury due to

inaccurate clamp employment in hysterectomy. These fistulae are generally supratrigonal and have healthy tissue around. In comparison obstetric fistula is a huge injury, with dead tissue around. They mostly involve the trigone, bladder neck and urethra (Mehmood et al., 2009).

Vesicovaginal fistula presents with constant leakage of urine, persistent odor and perineal skin rash. The main concerns for the Vesicovaginal fistula lie in social and moral distress for the woman.<sup>3</sup> In developed countries, the problem of Vesicovaginal fistula due to obstetrical cause has almost been eradicated, but in developing

countries, it still remains a problem. Long standing 2nd stage of labor is said to be the dominant (97%) cause of VVF.<sup>4</sup>

Fistulae always require surgical interference. Surgery can be done through abdominal or vaginal approach. Preference of approach in a particular patient depends at the location of fistula, existence or absence of vaginal stenosis and expertise of the surgeon. To provide support, increase vascularization and better lymphatic drainage, tissue/ graft interposition between urinary bladder and vaginal wall is done. In case of vaginal repair of VVF, Martius fat graft and for abdominal approach omental transposition is the gold standard. But free bladder mucosa autograft, peritoneum, rectus sheath, ileal graft and even duramater have been used successfully attempted VVF repair by using perivesical fat interposition.<sup>5,6</sup>

Rationale of my research was to compare the results of Vesicovaginal fistula repair with omental transposition and perivesical fat emplacement in terms of recurrence and maximum bladder capacity and to conclude which technique is more suitable in our population.

## MATERIAL METHODS

It was a randomized control trial. Study was conducted in the Urology department of Peoples University Hospital Nawabshah, Sindh, Pakistan, during the time January 2018 to December 2018. All the patients were admitted through Out Patient Department (OPD). 40 patients with VVF, splitted into 2 groups, each consisting of 20 were included. Group 1, Omental Transposition and group 2, Perivesical Fat Emplacement. Adult female patients with Vesicovaginal fistula, resulting from obstetrical and as a complication of surgery. This was confirmed by physical examination, IVU, pelvic computerized tomography scan with contrast, retrograde urethrocystogram, ultrasound KUB and cystoscopy.

Patients with systemic illness like diabetes mellitus, chronic renal failure and chronic liver disease, Patients on immunosuppressant therapy like: steroids intake and Patients undergone

irradiation of the pelvis due to any malignant disease were excluded.

All the routine investigations i.e. complete blood count with bleeding profile, random blood Sugar levels, renal and liver function tests and Hepatitis B, C were done. Demographics like age, parity and etiological factor (prolonged labor, lower caesarean section, instrumental delivery and total abdominal hysterectomy) were noted. Both of the procedures were fully explained to the patients and consent was obtained. Patients were called for follow up and found good results with least complication rate. In both group urethral catheter was passed at the end of the procedure and was kept for two weeks. The patient was advised to avoid sexual intercourse for at least three months. Strict antenatal care and elective caesarean section should be done, in case of future pregnancies. After 6, 12 and 24 weeks, all the patients were assessed for recurrence. The complications like wound infections, urgency, urge incontinence and paralytic ileus were also noted.

## RESULTS

A total of 40 Patients diagnosed to have vesicovaginal fistula on basis of clinical history and investigation were included in the study. Operated most of the cases were 18 to 60 years of age as presented in Figure-1. The average age of the patients was  $35.950 \pm 10.58$  years. Mean bladder capacity was 276.15 ml in all 40 patients. Minimum capacity was 220.0 ml and maximum capacity was 350.0 ml. Figure-2.

In group 1, 60.0 % of the cases were due to hysterectomy, 15 % cases were due to C-section along with hysterectomy, 10 % were due to obstructed labor and c, section and 5% were due to D&C, while in the group 2, 55.0 % of the cases were due to hysterectomy, 20 % cases were due to C-section, 15 % were due to c- section along with hysterectomy, 5 % were due to obstructed labor and 5 % were due to RTA Table-I.

In this study only one out of twenty cases had recurrence in group 1 and all the cases in group 2 were successful Table-II.

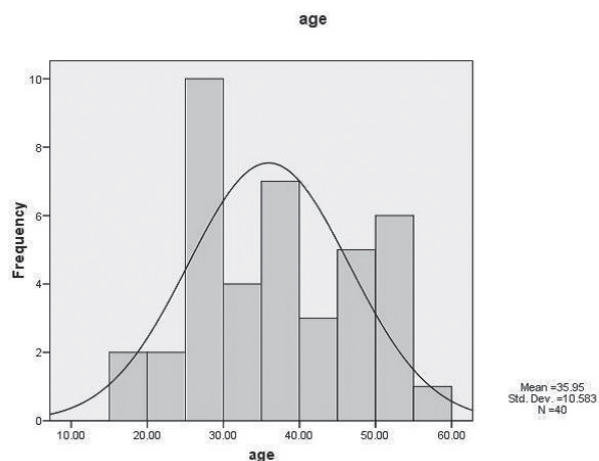


Figure-1

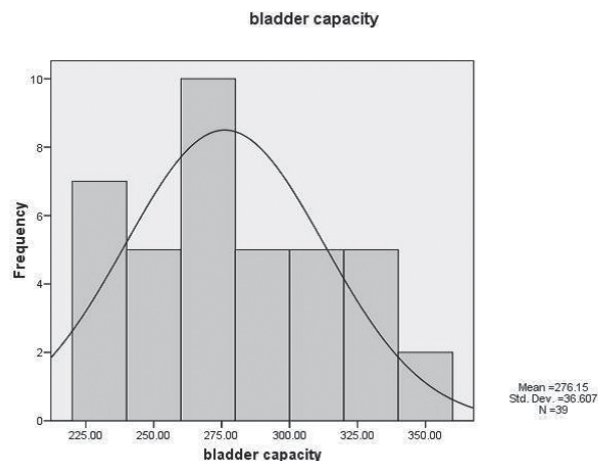


Figure-2

Etiology	Group 1 Omental Transposition		Group 2 Perivesical Fat Emplacement	
	Patients	Percentage	Patients	Percentage
Hysterectomy	12	60%	11	55%
Cesarean section	2	10%	4	20%
Cesarean section+ hysterectomy	3	15%	3	15%
Obstructed labor	2	10%	1	5%
Dilation and Curettage	1	5%	0	0%
RTA	0	0%	1	5%

Table-I. Etiology

Outcome	Group 1 Omental Transposition		Group 2 Perivesical Fat Emplacement	
	Patients	Percentage	Patients	Percentage
Successful	19	95%	20	100%
recurrence	1	5%	0	0%
Total	20	100%	20	100%

Table-II. Outcome

**DISCUSSION**

In this study two techniques of repair of Vesicovaginal fistula were compared in terms of recurrence and bladder capacity. Multiple studies are available in the literature on this important subject on various aspects. There are variety of surgical techniques for the treatment of VVFs. There are few non-surgical therapies as well for the management of small VVFs. Each modality of treatment has certain pros and cons. However it was found that interpositioning of some healthy tissue in between the bladder and vaginal mucosa lead to success rate reaching almost 100%. Multiple studies are found in

which interpositioning of healthy tissue has been employed for the treatment of VVFs with convincing results.

In this study most of the cases were 18 to 60 years of age. The average age of the patients was 35.950± 10.58 years. Study Waleed Mohammad Altaweel reported age ranged from 21 to 74 years, with a median of 34 years.<sup>7</sup> In our study most commonly cause of VVF was 60.0 % of the cases were due to hysterectomy, while in the study of Mohsin Shakil<sup>8</sup> also reported iatrogenic injury due to Hysterectomy in 70% cases.

Evans DH et al.<sup>9</sup> conducted a retrospective study and found that 10 patients out of 29 with small VVFs were repaired by interposition flap and the success rate was 100%. In remaining 19 patients with small VVFs flap was not used in the repairing of VVF so 12 patients were successful with this method (63%). Of the 8 patients with large fistulae, VVFs of 2 patients were repaired by using interposition flap and both were successful (100%). In the remaining 6 large VVFs, flap was not used during the repair and only 4 were successful with this method (67%). This study indicates a greater success rate for VVFs repaired with flap interposition (100%) outcome at their setup. In our study observed the success rate was 95 % (19 /20) in group 1, only one case had recurrence. While in group 2 the success rate was 100 %.

Miklos JR found that interposition of peritoneal flap is also a useful and effective treatment for VVF repair. They compared peritoneal flap versus Martius flap interposition through transabdominal and transvaginal approaches respectively.<sup>10</sup> Khan M reported the technique of harvesting pelvic fat as an interposition flap for the treatment of high Vesicovaginal fistula. They concluded that perivesical fat proved an effective interposition flap in the repair of VVFs.<sup>11</sup> Zambon JP et al conducted a study on 23 patients having complex Vesicovaginal fistulae. The vaginal approach was used in 17 patients and abdominal approach in 6. Follow up for all the patients was done for 1 year. They concluded that as the VVF repair through vaginal approach is a less invasive procedure, high cure rates and low cost, so new approaches for repair of VVF must be evaluated carefully before suggesting as an alternative.<sup>1</sup>

Rajamaheswari conducted a study to assess the usefulness of vaginal approach repair for the supratrighonal VVF. They had a review of 48 cases and concluded that all vaginally accessible supratrighonal VVFs of gynecological origin should be preferably repaired through the vaginal approach.<sup>12</sup>

Abdominal approach is mostly preferred when there is suspicion of ureteric involvement,

which may than require re-implantation. A review was undertaken by Santosh Kumar et al in 2007 to determine the recent advances, regarding the time and surgical technique for VVF repair.<sup>13</sup> They evaluated early versus delayed intervention, abdominal versus vaginal approaches, laparoscopic repair. They also evaluated latest robotic repair of VVF. They conclude that obstetric VVFs remains the major problem in underdeveloped countries whereas the most frequent cause of VVF in industrialized or developed countries is the hysterectomy. The time and route of fistula repair are very important for better outcome of repair. Compelling all the patients for delayed repair or by only one specific technique does not always shows promising results and recurrence may cause serious moral and social distress for the women.<sup>14</sup>

In our study omental pedicle transposition versus perivesical fat emplacement in the transabdominal VVF repair, were compared in terms of recurrence and bladder capacity. After 6, 12 and 24 weeks, all the patients were assessed for recurrence and maximum bladder capacity.

## CONCLUSION

Concluded that both the Vesicovaginal fistula repair techniques either with omental transposition or perivesical fat emplacement are equally effective in terms of recurrence and bladder capacity.






Copyright© 25 June, 2019.

## REFERENCES

1. Zambon JP, Batezini NSS, Pinto ERS, Skaff M, Girotti ME, Almeida FG. **Do we need new surgical techniques to repair vesico-vaginal fistulas?**. Int Urogynecol J 2010; 21:337-42.
2. Amna A, Sirichand P, Nadeem F. **Women perception and awareness about genitourinary fistula.** J Liaquat Uni Med Health Sci. 2015; 14(03):129-32.
3. Saadalla AM, Mirghani HO. **Psychosocial impact among Sudanese women with vesico-vaginal fistula.** Frontiers in Cognitive Psychology. 2017; 2:10-2.
4. Shafqat T, Faiz NR, Haleemi M. **Profile and repair success of Vesicovaginal Fistula in NWFP.** JPMI 2009; 23(1):99-101.

5. Uprety DK, Subedi S, Budhathoki B, Regmi MC. **Vesicovaginal fistula at Tertiary Care Center in Eastern Nepal.** J. Nepal Med. Assoc 2008; 47(171):120-2.
6. Singhal S, Nanda S, Singhal S. **Sexual intercourse: An unusual cause of Vesicovaginal fistula.** Int Urogynecol J Pelvic Floor Dysfunct 2007; 18(5):587-8.
7. Altaweel WM, Rajih E, Alkhudair W. **Interposition flaps in vesicovaginal fistula repairs can optimize cure rate.** Urol Ann. 2013 Oct-Dec; 5(4): 270–2.
8. Shakil M, Ahmed R, Hanif S. **Surgical outcomes of genitourinary fistulae: an analysis of 26 cases.** Pak J Physiol. 2016; 12(4):27-9.
9. Evans DH. **Interposition flaps in transabdominal Vesicovaginal repairs Urology.** 2001 Apr; 57(4):25-8.
10. Miklos JR, Moore RD, Chinthakanan O. **Laparoscopic and robotic-assisted vesicovaginal fistula repair: A systematic review of the literature.** Journal of minimally invasive gynecology. 2015 Jul 1; 22(5):727-36.
11. Khan M, Muhammad S, Shah FO, Tashfeen R, Faridooon S, Hadi A, Sajjad B. **Role of modified martius flap in the repair of vesicovaginal fistulae.** J Surg Pak (International). 2017 Oct; 22:4-10.
12. Rajamaheswari N, Chhikara AB, Seethalakshmi K, Bail A, Agarwal S. **Trans-vaginal repair of gynecological supratrigonal vesicovaginal fistulae: A worthy option!.** Urology annals. 2012 Sep; 4(3):154-9.
13. Kumar S, Kekre NS, Gopalakrishnan G. **Vesicovaginal fistula: An update.** Ind J Urol. 2007; 23(2):187-91.
14. Ojewola RW, Tijani KH, Jeje EA, Ogunjimi MA, Animashaun EA, Akanmu ON. **Transabdominal repair of vesicovaginal fistulae: A 10-year tertiary care hospital experience in Nigeria.** Nigerian Postgraduate Med J. 2018 Oct 1; 25(4):213-6.

### AUTHORSHIP AND CONTRIBUTION DECLARATION

Sr. #	Author(s) Full Name	Contribution to the paper	Author(s) Signature
1	Aijaz Hussain Memon	Conception and design, Statistical expertise, Critical revision of the article for important intellectual content.	
2	Mumtaz Ali	Data collection critical revision of the article for important intellectual content.	
3	Salman Manzoor Qureshi	Statistical expertise.	
4	Wasim Sarwar Bhatti	Drafting of the article.	
5	Naveed Ahmed	Data collection.	
6	Mujeeb ur Rehman	Data collection.	