



1. MDS Trainee, BDS
Department of Oral & Maxillofacial Surgery
Dr. Ishrat ul Ibad Khan Institute of Oral Health Sciences,
Dow University of Health Sciences.
2. BDS, FCPS
Associate Professor
Department of Oral & Maxillofacial Surgery
Dow International Dental College,
Dow University of Health Sciences.
3. BDS, MPhil, FCPS
Assistant Professor
Department of Oral & Maxillofacial Surgery
Dow International Dental College,
Dow University of Health Sciences.
4. BDS, FCPS
Assistant Professor
Department of Oral & Maxillofacial Surgery
Dr. Ishrat ul Ibad Khan Institute of Oral Health Sciences,
Dow University of Health Sciences.
5. MD, MSc., MFDS RCPSG, MFD RCSI
Assistant Professor
Department of Oral Biology
Dow International Dental College,
Dow University of Health Sciences.
6. BDS, MCPS
Associate Professor
Department of Oral Medicine
Dow International Dental College,
Dow University of Health Sciences.
7. BDS, F.D.S.R.C.S
Professor
Department of Oral and Maxillofacial Surgery
Dr. Ishrat ul Ibad Khan Institute of Oral Health Sciences,
Dow University of Health Sciences.

CONDYLAR FRACTURE; CORRELATION OF TREATMENT OUTCOMES OF CONDYLAR FRACTURE FIXATION WITH SINGLE AND MULTIPLE MINIPLATES.

Usman Ashraf¹, Shaheen Ahmed², Abdul Hafeez Shaikh³, Noreen Iqbal⁴, Syed Jaffar Abbas Zaidi⁵, Umer Hasan⁶, Anwar Ali⁷

ABSTRACT... Background: This study was conducted to compare treatment outcomes of condylar fracture fixation using either single or double non-compressive mini plates. **Study Design:** Interventional study. **Setting:** Department of Oral and Maxillofacial Surgery, Dr. Ishratullbad Khan Institute of Oral Health Sciences, Dow University of Health Sciences. **Period:** July 2017 till December 2017. **Materials and Methods:** A total of 30 participants were selected and randomly divided into 2 groups, each consisting of 15 participants. Patients treated with a single non-compression miniplate were placed in group 1, while those patients whose fractures were reduced and fixed by double non-compression mini plates were placed in group 2. Outcomes assessed were intraoperative time, deviation on mouth opening, malocclusion, plate bending, function of facial muscles and the relative cost of implants. **Results:** Out of a total of thirty patients, it was observed that those patients who were randomly assigned group 2 had better treatment outcomes and less complications as compared to the other group. Three patients with malocclusion were seen in group 1 compared with only a single case seen in group 2. Greater number of plate bending with susceptibility to plate fracture was also observed in Group 1. **Conclusion:** It can thus be concluded that using two plates for condylar fracture represents a more stable and sustainable solution with less complications in providing osteosynthesis.

Key words: Non-compression Miniplates, Condylar Fractures, Condylar Fixation, Treatment Outcomes.

Article Citation: Ashraf U, Ahmed S, Shaikh AH, Iqbal N, Zaidi SJA, Hasan U, Ali A. Condylar fracture; correlation of treatment outcomes of condylar fracture fixation with single and multiple miniplates. Professional Med J 2019; 26(3):416-420.
DOI: 10.29309/TPMJ/2019.26.03.3238

Correspondence Address:
Dr. Syed Jaffar Abbas Zaidi
House No. FL 1/11, Block No.3,
Gulshan-e-Iqbal, Karachi, 75300.
jaffar.zaidi@duhs.edu.pk

Article received on:
26/02/2018

Accepted for publication:
15/10/2018

Received after proof reading:
23/02/2019

INTRODUCTION

Condylar fracture remains to be one of the common mandibular fractures occurring at a frequency of almost 40%.¹⁻³ Even though advances in biomaterials and surgical techniques of fixation has revolutionized contemporary oral and maxillofacial surgery, the best treatment modality for condylar fractures still remains to be controversial.³

Closed reduction has been the mainstay treatment modality preferred by majority of oral surgeons but closed reduction has been associated with long term complications namely malocclusion, pain and deviation of mandible, inadequate vertical dimension of occlusion and possible ankylosis ultimately leading to loss of masticatory

function and poor esthetics.⁴⁻⁶

The advent of miniplate system with the added benefit of early mobilization has turned the focus of many surgeons towards open reduction treatment modalities owing to decreased morbidity.⁷ Many rigid internal fixation techniques exist for the possible reduction and fixation of the mandibular condyle. Data in the literature has pointed out that single non-compression mini plate has remained to be the most frequently used method of osteosynthesis despite various issues such as screw fracture and plate loosening being associated with it.⁸ Using double plates has demonstrated superior stability in the fixation of condylar fractures despite the burden of the cost of an additional plate and longer operating

time.^{9,10}

Instead of using multiple miniplate, stronger dynamic compression plates using 2.4mm screws have been advocated to increase rigidity but due to the high infection rate, they have not gained popularity amongst oral surgeons.¹¹ Although numerous studies have indicated that double miniplate osteosynthesis for condylar fractures have produced slightly better results as compared to compression osteosynthesis.⁶

No local study exists that justifies the clinical usefulness of double non-compression mini plates. The goal of this study is to compare the function and treatment outcomes of the mandibular condyle after reduction and fixation using two non-compression miniplates and one non-compression miniplate.

MATERIALS AND METHODS

An interventional study was undertaken, the study sample was taken from the trauma cases that reported to Department of Oral and Maxillofacial surgery, Dr. Ishratullbad Khan Institute of Oral Health Sciences, Dow University of Health Sciences. Only those patients were included who had given informed consent. Informed consent was obtained by explaining the advantages and disadvantages regarding treatment options in a clear, coherent and unambiguous language. The inclusion criteria for the study included;

1. Patients over the age of 18 years

Exclusion criteria included;

1. Patients unfit to undergo General Anesthesia
2. Patients with severe uncontrolled systemic diseases falling under ASA III or IV group
3. Patients who had insufficient dentition to reproduce occlusion

Open reduction and internal fixation was performed intraorally for all the cases. A Hind's incision was used for the exposure of the fractured condyle. In Hind's incision or retromandibular approach, the incision begins 0.5 cm below the ear lobe and continues inferiorly for 3-3.5cm up to the mandibular angle depending on the need of exposure. It does not extend beyond the angle of the mandible.

After exposure the fracture was reduced, and two mini-dynamic non-compression miniplates with 2.0 mm screws were placed. The extra oral incision was closed in two layers using Vicryl 3-0 and Proline 5-0.

Patients were recalled and treatment outcomes that were assessed were intraoperative time, degree of malocclusion, plate bending & fracture, cost of implants and facial nerve function. SPSS statistical software version 21 was used to perform statistical analysis for this study.

RESULTS

Pre-operative findings, investigations, classification, and post-operative complications	No. of Pt. in Group 1	No. of Pt in Group 2
Malocclusion	3	1
Lateral Deviation	2	0
Infection	2	1
Plate Bending/Plate Fracture	2	0
Plate Removal	1	0
Facial Nerve function	0	0

Table-I. Comparison of complications

Associated Fracture	Group1	Group 2
Symphysis	5	6
Body	2	0

Time of Surgery	Group 1	Group 2
1-2 hours	9	5
2-3 hours	6	10

Table-II. Fracture location & intraoperative time

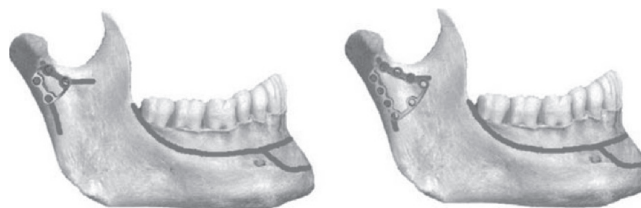


Figure-1. Meyers principle

Out of the 30 randomly chosen patients, majority comprised of male patients. 25 were male compared to 5 females. Majority of the patients who we treated were involved in road traffic accidents. Two patients had history of assault while one of the patient had history of fall. The main age of patients in both the groups was 36.5 years.

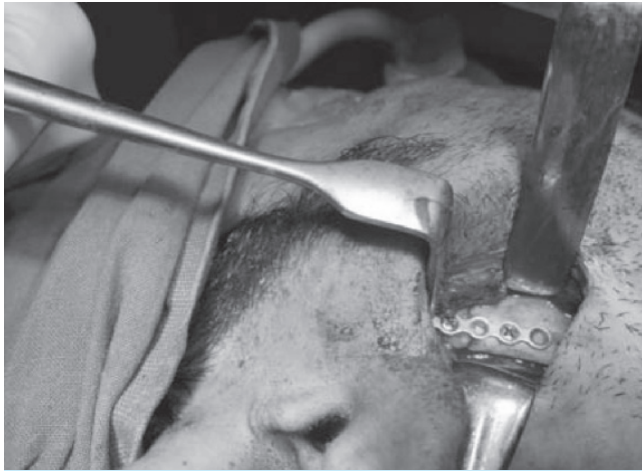


Figure-2. Single plate application on condyle

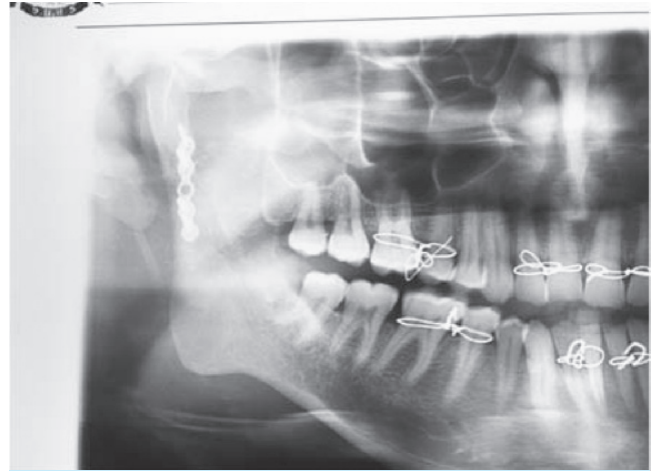


Figure-3. Post op OPG of single plate application on condyle

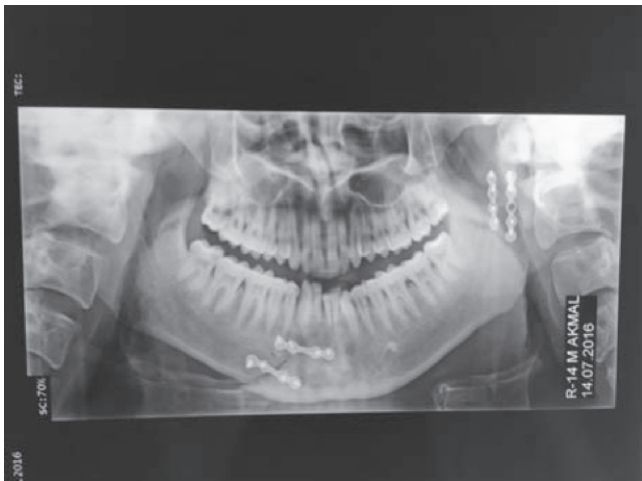

Figure-4. Application of double plate on condyle

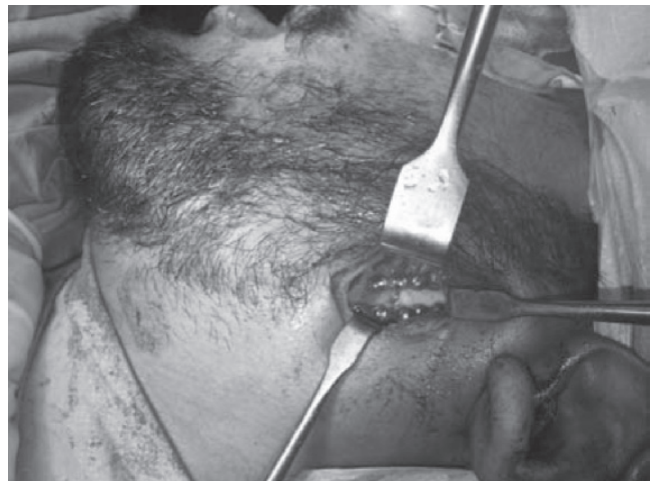

Figure-5. Double plate application on condyle

30 Patients were randomly assigned to either of the two groups so that every group consisted of 15 patients each. In one group the patients were treated through single non-compression miniplates while in the other group two non-compression miniplates were placed. Comparison between treatment outcomes of both the treatment modalities are depicted in Table-I while fracture location and intraoperative time of both the treatment modalities are shown in Table-II.

DISCUSSION

The objective of this interventional study was to correlate which treatment modality of reduction and fixation of condylar fractures of the mandible provided better treatment outcomes with less complications. The efficacy of two non-

compression miniplates to that of a single non-compression miniplate was assessed.

Various approaches such as Risdon's, Hinds, intraoral incision have been reported in the literature for the exposure of condyle.^{12,13} In this case Hinds or retromandibular approach was chosen for various advantages it has over other approaches. It has a minimal working distance from the incision up to the site of the fracture.¹⁴⁻¹⁶ Less morbidity to the facial nerve has been associated in this study as the nerve can be identified and easily retracted under direct vision. This approach is aesthetically pleasing due to the less conspicuous scar being formed.¹⁷⁻¹⁹

By applying principles of osteosynthesis, Champy was able to determine the lines of ideal

osteosynthesis on the mandibular symphysis and body but due to insufficient data, these principles were not applicable on the mandibular condyle.^{20,21} In 2002 a study by Meyer et al attempted to fill this void.²² For achieving maximum stability and fixation of mandibular fractures, it is recommended that fixation is performed along the tensile stress lines as per Champy.^{23,24} These recommendations could also be applicable to fractures of condyles and sub condylar area by delineating areas of ideal osteosynthesis such that they are parallel to the inherent strain lines of the mandible.^{14,22,25}

Choie et al have suggested that fixation of condylar fractures by placement of two non-compressive miniplates at both the anterior and posterior borders results in strengthening condyles against compressive forces.²⁶

In Group 1 in which single plate was placed, we observed that a greater number of plate fracture due to which a significant number of the plates had to be removed, which in turn required a second surgery which added to the overall cost to the patient, few patients also reported in with minor malocclusions which were locally treated by minor occlusal adjustment or placing the patient in maxillomandibular fixation for a brief time.

The main drawback observed in Group 2, the group in which we placed double non-compression plates was the cost of the extra plate that was placed along with the extra operating time that was required which in turn added to the cost of the surgery.

CONCLUSION

On the basis of our study, we can conclude that despite the extra cost involved using two non-compression plates for condylar fracture provides optimum and sustainable solution with better treatment outcomes in obtaining stable osteosynthesis with reduced morbidity.







Copyright© 15 Oct, 2018.

REFERENCES

1. Marker P, Nielsen A, Bastian HL. **Fractures of the mandibular condyle. Part 1: patterns of distribution of types and causes of fractures in 348 patients.** British Journal of Oral and Maxillofacial Surgery. 2000;38(5):417-21.
2. Zrounba H, Lutz J-C, Zink S, Wilk A. **Epidemiology and treatment outcome of surgically treated mandibular condyle fractures. A five years retrospective study.** Journal of Cranio-Maxillofacial Surgery. 2014;42(6):879-84.
3. Rastogi S, Sharma S, Kumar S, Reddy MP, Indra BN. **Fracture of mandibular condyle—to open or not to open: an attempt to settle the controversy.** Oral surgery, oral medicine, oral pathology and oral radiology. 2015;119(6):608-13.
4. O'Connor RC, Shakib K, Brennan PA. **Recent advances in the management of oral and maxillofacial trauma.** British Journal of Oral and Maxillofacial Surgery. 2015;53(10):913-21.
5. Al-Moraissi EA, Ellis E. **What method for management of unilateral mandibular angle fractures has the lowest rate of postoperative complications? A systematic review and meta-analysis.** J Oral Maxillofac Surg. 2014;72(11):2197-211.
6. Ellis E, Karas N. **Treatment of mandibular angle fractures using two mini dynamic compression plates.** J Oral Maxillofac Surg. 1992;50(9):958-63.
7. Kisnisci R. **Management of fractures of the condyle, condylar neck, and coronoid process.** Oral and Maxillofacial Surgery Clinics. 2013;25(4):573-90.
8. Ellis E, Throckmorton GS. **Treatment of mandibular condylar process fractures: biological considerations.** Journal of Oral and Maxillofacial Surgery. 2005;63(1):115-34.
9. Ghezta NK, Bhardwaj Y, Rani P, Ram R. **Efficacy of retromandibular transparotid approach for the management of extracapsular subcondylar mandibular fractures using 2-mm titanium miniplates: A prospective clinical study.** Journal of Oral and Maxillofacial Surgery. 2016;74(8):1613-21.
10. Hou J, Chen L, Wang T, Jing W, Tang W, Long J, et al. **A new surgical approach to treat medial or low condylar fractures: The minor parotid anterior approach.** Oral surgery, oral medicine, oral pathology and oral radiology. 2014;117(3):283-8.
11. Ellis E, Sinn DP. **Treatment of mandibular angle fractures using two 2.4-mm dynamic compression plates.** J Oral Maxillofac Surg. 1993;51(9):969-73.
12. Oikarinen K, Altonen M, Kauppi H, Laitakari K. **Treatment of mandibular fractures. Need for rigid internal**

- fixation.** J Craniomaxillofac Surg. 1989;17(1):24-30.
13. Rabbiosi D, Bardazzi A, Valassina D, Marelli S, Colletti G. **Surgical access to condylar fractures in panfacial traumas.** Minerva Stomatol. 2012;61(10):431-41.
 14. Rallis G, Mourouzis C, Ainatzoglou M, Mezitis M, Zachariades N. **Plate osteosynthesis of condylar fractures: A retrospective study of 45 patients.** Quintessence international. 2003;34(1).
 15. Rauso R, Tartaro G, Stea S, Tozzi U, Biondi P. **Plates removal in orthognathic surgery and facial fractures: When and why.** J Craniofac Surg. 2011;22(1):252-4.
 16. Rocton S, Chaine A, Ernenwein D, Bertolus C, Rigolet A, Bertrand JC, et al. **[Mandibular fractures: Epidemiology, therapeutic management, and complications in a series of 563 cases].** Rev Stomatol Chir Maxillofac. 2007;108(1):3-10; discussion -2.
 17. Ellis E, Dean J. **Rigid fixation of mandibular condyle fractures. Oral surgery, oral medicine, oral pathology.** 1993;76(1):6-15.
 18. Ziccardi VB, Schneider RE, Kummer FJ. **Wurzburg lag screw plate versus four-hole miniplate for the treatment of condylar process fractures.** Journal of oral and maxillofacial surgery. 1997;55(6):602-7.
 19. Undt G, Kermer C, Rasse M, Sinko K, Ewers R. **Transoral miniplate osteosynthesis of condylar neck fractures. Oral Surgery, Oral Medicine, Oral Pathology, Oral Radiology, and Endodontology.** 1999;88(5):534-43.
 20. Cillo JE, Ellis E. **Management of bilateral mandibular angle fractures with combined rigid and nonrigid fixation.** J Oral Maxillofac Surg. 2014;72(1):106-11.
 21. Ellis E, Walker L. **Treatment of mandibular angle fractures using two noncompression miniplates.** J Oral Maxillofac Surg. 1994;52(10):1032-6; discussion 6-7.
 22. Meyer C, Serhir L, Boutemi P. **Experimental evaluation of three osteosynthesis devices used for stabilizing condylar fractures of the mandible.** Journal of Cranio-Maxillofacial Surgery. 2006;34(3):173-81.
 23. Ellis E. Discussion. **Internal fixation of mandibular angle fractures: A meta-analysis.** Plast Reconstr Surg. 2010;125(6):1761-2.
 24. Ellis E. **Open reduction and internal fixation of combined angle and body/symphysis fractures of the mandible: how much fixation is enough?** J Oral Maxillofac Surg. 2013;71(4):726-33.
 25. Gerlach K, Schwarz A. **Bite forces in patients after treatment of mandibular angle fractures with miniplate osteosynthesis according to Champy.** International journal of oral and maxillofacial surgery. 2002;31(4):345-8.
 26. Choi B-H, Kim K-N, Kim H-J, Kim M-K. **Evaluation of condylar neck fracture plating techniques.** Journal of Cranio-Maxillofacial Surgery. 1999;27(2):109-12.

AUTHORSHIP AND CONTRIBUTION DECLARATION

Sr. #	Author-s Full Name	Contribution to the paper	Author=s Signature
1	Usman Ashraf	Conceptualization of study design.	
2	Shaheen Ahmed	Proof reading	
3	Abdul Hafeez Shaikh	Literature search	
4	Noureen Iqbal	Data collection	
5	Syed Jaffar Abbas Zaidi	Write up	
6	Umer Hasan	Data interpretation	
7	Anwar Ali	Data analysis	