



OBSTRUCTIVE HYDROCEPHALUS; SHORT TERM COMPLICATIONS OF ENDOSCOPIC THIRD VENTRICULOSTOMY IN OBSTRUCTIVE HYDROCEPHALUS.

Nauman Shakeel¹, Aaamir Aziz², Muhammad Faaqi Ali³, Faheem Usmani⁴, Tariq Salahuddin⁵

1. FCPS
Senior Registrar
Department of Neurosurgery
LGH PGMI.
2. FCPS
Assistant Professor
Department of Neurosurgery
LGH PGMI.
3. FCPS
Assistant Professor
Department of Neurosurgery
DUHS CHK.
4. FCPS
Registrar
Department of Neurosurgery
LGH PGMI.
5. FRCS
Ex HOD
Department of Neurosurgery
LGH PGMI

Correspondence Address:

Dr. Muhammad Faaqi Ali
Assistant Professor
DUHS CHK.
salamfaaiq@hotmail.com

Article received on:

06/06/2018

Accepted for publication:

15/11/2018

Received after proof reading:

31/01/2019

ABSTRACT... Introduction: Endoscopic Third Ventriculostomy (ETV) is a surgical procedure that allows the Cerebrospinal Fluid (CSF) to flow directly from the third ventricle to the basal cisterns and subarachnoid spaces, ETV has been established as a safe treatment for obstructive hydrocephalus because in this procedure there is no implant is deployed, that's why rate of post operative complications is low as compare to VPS as intracranial infection found in 8% patient, intracranial hemorrhage in 5% and 1% patient developed seizure post ETV. **Objectives:** Objective of this study is to determine the frequency of short term complications of endoscopic third ventriculostomy in obstructive hydrocephalus. **Study Design:** Descriptive case series. **Setting:** Department of Neurosurgery, Lahore General Hospital, Lahore. **Duration:** Six months: from 01-07-2011 to 31-12-2011. **Methods:** This was a prospective study of in which 45 patients underwent Endoscopic third ventriculostomy for Obstructive hydrocephalus. The outcome of interest was to assess the frequency of complications like infection, hemorrhage and seizures following the ETV in patient with obstructive hydrocephalus. Data was collected on a specially designed Performa. Demographic details, signs and symptoms at presentation, details of post operative evaluation (mortality and neurological deficiency) were noted. **Results:** A total of 45 patients underwent in ETV for the treatment of obstructive hydrocephalus. Complications were observed in eight (17.8%) cases in which five patients had only one complication and three patients had multiple (two) complications. Regarding type of complication, Infection was observed in six (13.3%) cases, hemorrhage was observed in four (8.9%) cases and wound CSF leakages was seen in only one (2.2%) case. **Conclusion:** Endoscopic third ventriculostomy is recent advances in the management of obstructive hydrocephalus, it has lesser complications (Infection, Hemorrhage, seizures) and long term failure rate is low as compare to the traditional treatment of obstructive hydrocephalus.

Key words: Short Term Complications, Endoscopic Third Ventriculostomy, Obstructive Hydrocephalus.

Article Citation: Shakeel N, Aziz A, Ali MF, Usmani F, Salahuddin T. Short term complications of endoscopic third ventriculostomy in obstructive hydrocephalus. Professional Med J 2019; 26(2):318-323.
DOI: 10.29309/TPMJ/2019.26.02.3115

INTRODUCTION

Hydrocephalus is a hydrodynamic disorder in which there is an abnormal accumulation of cerebrospinal fluid (CSF) in the ventricles and subarachnoid spaces of the brain. It may be regarded as an imbalance of CSF formation, flow and absorption of sufficient magnitude to produce a net accumulation of fluid within the cerebral ventricles. Based on its underlying mechanism, hydrocephalus can be classified into: Non-Communicating and Communicating Hydrocephalus. The overall incidence of hydrocephalus in the general population is not known, but the estimated prevalence is 1–1.5%.

The incidence of pediatric hydrocephalus as an isolated congenital disorder is approximately 1/1000 live births.^{1,2} Despite fact that the advent of ventriculoperitoneal shunts (VPS) represented a substantial progress in the neurosurgical management of hydrocephalus. But for the past 50 year of development of VPS system the complications associated with this procedure are inevitably numerous and still could not be eliminated in spite of improvement in operative technique, change of implant material and design. For instance VPS infection is the most frequently observed complication. which is related to substantial morbidity and mortality, and

exerts a negative impact on the quality of life of patients.³ It is studied that up to 24.6% of all shunt operations are complicated by infection in spite of the fact that neurosurgeons take numerous steps to decrease the risk of infection. Moreover, in 25% of patient the seizure is another factor to increase morbidity, while intracranial hemorrhage can occur in 3.5% of patient post operatively.^{4,5}

The higher rate of inherent complications associated with VPS has led neurosurgeons to treat patients of hydrocephalus by doing Endoscopic third ventriculostomy (ETV). It is a surgical procedure that allows the CSF to flow directly from the third ventricle to the basal cisterns and subarachnoid spaces, thus by-passing the aqueduct and the CSF pathways of the posterior fossa; Endoscopic third ventriculostomy (ETV) has been established as a safe treatment for obstructive hydrocephalus in selected patients. Because in this procedure there is no implant is deployed, that's why many studies conducted at different centers of world revealed rate of post operative complications is low as compare to ventriculoparitoneal shunt. Like intracranial infection has been reduced to up to 8% patient, intracranial hemorrhage in 5% and 1% patient developed seizure post ETV.^{6,7}

There is an emphasis on early recognition and diagnosis of obstructive hydrocephalus is essential because the complications related to disease progress can be better cured at an early stage by timely intervention. Brain imaging is a crucial part of the emergent evaluation. Computed tomography (CT) and Magnetic Resonance Imaging (MRI) scans show equal ability to identify the presence of acute and chronic hydrocephalus, site of CSF obstruction and any brain space occupying lesion. As CT scan is widely available and relatively cheaper imaging as compare to MRI, we used CT scan as imaging of first preference to assess the hydrocephalus and for further follow up.

OBJECTIVE

The objective of this study was to determine the frequency of short term complications of endoscopic third ventriculostomy in obstructive

hydrocephalus.

Study Design

Descriptive case series

Duration of Study

Six months from 01/07/2011 to 31/12/2011.

Setting

Department of Neurosurgery, Lahore General Hospital / Postgraduate Medical Institute, Lahore.

Inclusion Criteria

All the patients between 2 to 50 years of age of either sex having obstructive hydrocephalus (diagnosed on C. T Brain or MRI Brain).

Exclusion Criteria

Patients with Associated other congenital anomalies like Dandy walker cyst or Chiari malformation diagnosed on neuroimaging studies.

Patients with history of ongoing CNS infections like Meningitis or Encephalitis

Patients not fit for general anesthesia

Patients with Diabetes Mellitus

METHODOLOGY

Forty five patients presenting in the Department of Neurosurgery LGH/PGMI Lahore, fulfilling the inclusion criteria, will be enrolled. An informed consent will be obtained from patients after demonstrating the pros and cons of operative procedure. Patient and demographic data will be recorded on the specified proforma. Patients will be prepared for general anesthesia and operative procedure will be performed by the Professor and Associate Professor of department of Neurosurgery, LGH/PGMI, and Lahore.

Patient will be declared to develop infection on the basis of high grade fever > 101F at or after 3rd day within one Month postoperatively and will be confirmed by CSF lab analysis. Other short term complications, like hemorrhage which is diagnosed on neuroimaging studies and Seizures which is clinically assessed, will be recorded just after operative day within one month postoperatively.

Data was entered and analyzed in the software statistical packages for social science (SPSS-10). Frequency and percentage were computed for categorical variables like age groups, gender, complications. Mean, standard deviation, 95% confidence interval, median and IQR were computed for age. Effect modifier like age and gender were control by stratification techniques.

RESULTS

A total of forty five patients having obstructive hydrocephalus diagnosed on C.T brain were included in this study. All patients were between two to fifty years of age. Out of forty five patients, twenty one (47%) were male and twenty four (53%) were female.

In our study, complications were observed in eight (17.8%) cases in which five patients had only one complication and three patients had multiple (two) complications. Regarding type of complication, Infection was observed in six (13.3%) cases, hemorrhage was observed in four (8.9%) cases and wound CSF leakages was seen in only one (2.2%) case. (Table-I)

Rate of infection, hemorrhage and wound CSF leakages were mostly observed in above twenty years of age. Similarly infection was high in male than female while rate of hemorrhage was high in female than male.

Complications	Counts	Percentage
Infection	6	13.3%
Hemorrhage	4	8.9%
Wound CSF Leakage	1	2.2%

Table-I. Different type of complication n=45

DISCUSSION

Hydrocephalus is still a management challenge in modern neurosurgery. Surgery is the mainstay of its treatment. CSF diversion procedure like VPS is widely used modality of management.

Although the main advantage of CSF shunts is that they can be used in all types of hydrocephalus and age is not the limiting factor.

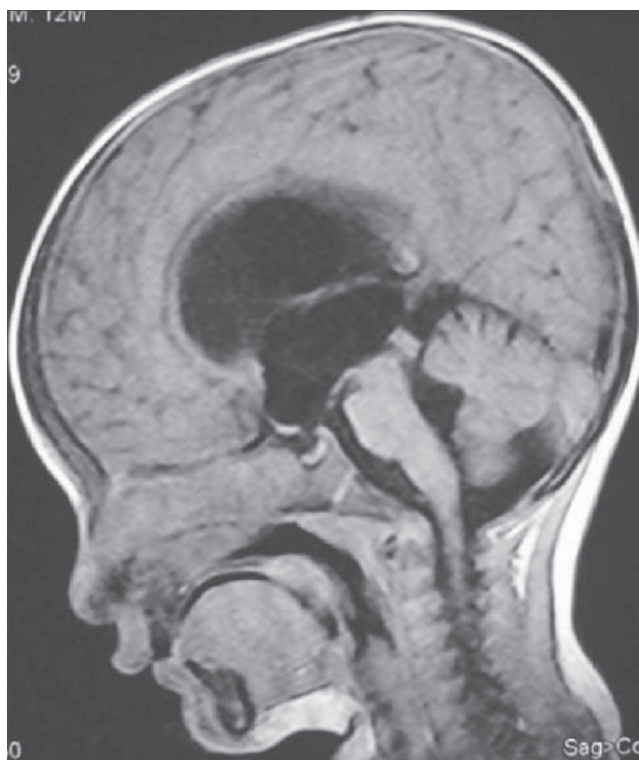
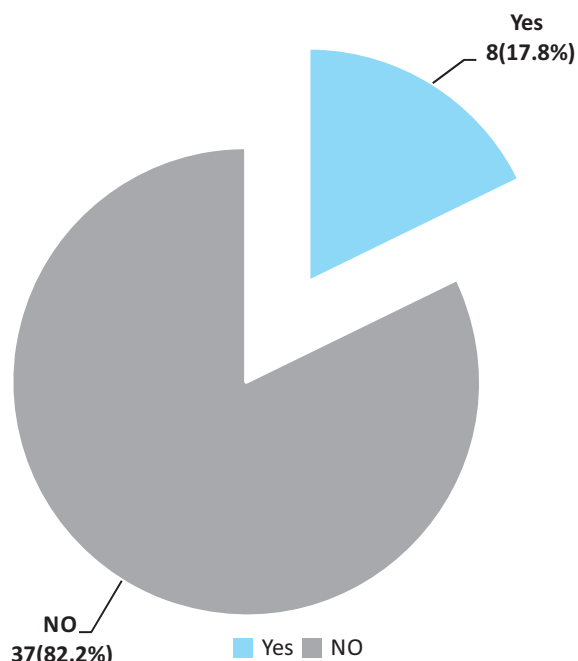


Figure-1. MRI of obstructive hydrocephalus

In contrast, utilization of ETV in children and adults has been considered to be limited by the characteristics of the CSF circulation and absorption. ETV is selectively indicated in patients with obstructive hydrocephalus.

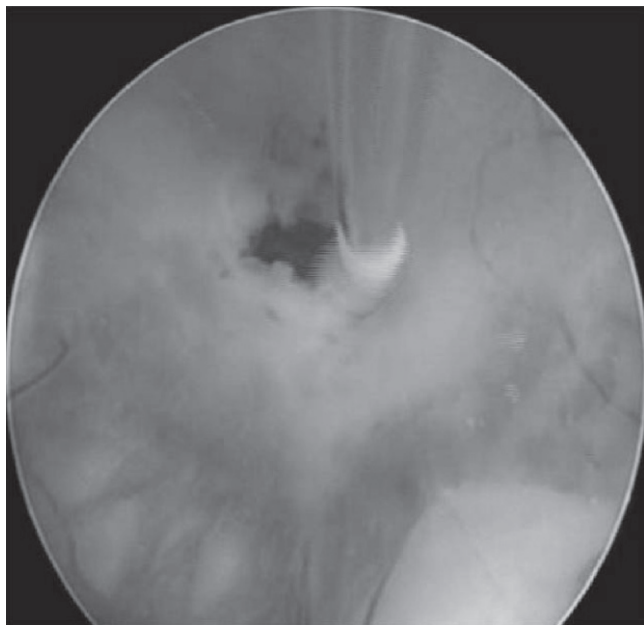


Figure-2. Fenestration of floor of third ventricle

It is less suitable in patients younger than two years of age because of the fact that in them the CSF spaces are not fully developed. Although few recent experiences appear to indicate that the preferential CSF absorption occurs within the cerebral parenchyma more than in peripheral subarachnoid spaces. As in infants the percentage of success of ETV is similar or slightly inferior to that of the same procedure to older children.⁸ Moreover, in ETV there is possibility of avoiding all the early and late complications related to VPS insertion like the presence of foreign body, and possible infective and mechanical failure of VPS.⁹

In our study the frequency of short term complications of ETV in obstructive hydrocephalus was evaluated. In Pakistan ETV is now in developmental stage and is being carried out by few consultants. That's why this was probably one of the largest studies regarding ETV in Pakistan covering the frequency of short term complications of ETV in patient suffering from obstructive hydrocephalus. It is prospective study conducted at Neurosurgery department LGH / PGMI, Lahore. A series of forty-five patients underwent ETV during six months from 01 July 2103 to 31st Dec 2013 at our center.

The mean age of the patients included in this

study was 21.66 ± 14.68 years with selected age range was 2 to 50 years. The gender distribution showed slight female predominance as 53% (24/45) were female patients and 47% (21/45) male.

Overall eight (17.8%) out of forty-five patients developed complications. In our study the most common and frequently observed complications were infection, hemorrhage and wound CSF leakage.

The rate of infection noticed was 13.34% (6/45) with slight male preponderance and in patients of age 20 or more. High grade fever (102 °F) at or after third day postoperatively considered positive indicator of impending infection, which is subsequently confirmed by CSF analysis via Lumbar Puncture (LP). Six patients developed meningitis, which was treated conservatively by using broad spectrum antibiotics for three weeks. Patients with meningitis worked up, CSF analysis revealed the culprit organism for meningitis was Staph. Aureus in five patients while Proteus spp. in one case. Antibiotics were changed according to the culture and sensitivity report for next three weeks until clinical improvement supported by serial CSF analysis normalization. Five patients showed successful recovery while one patient died secondary to ventriculitis, which could not be controlled despite broad spectrum antibiotic intravenously. Moreover, External Ventricular Drain (EVD) was also passed in frontal horn of lateral ventricle on contralateral site in order to deliver intrathecal antibiotic. In spite of all these measure single mortality could not be stopped.

Out of four patients, who developed intracranial hemorrhage, two had intracerebral hemorrhage along the trajectory of endoscope and two had intraventricular hemorrhage. Three of these patients did well on conservative management, while one of them developed ventriculitis. This patient managed aggressively, Broad spectrum antibiotic started and EVD done to deliver intrathecal antibiotic as well but could not be salvaged.

One patient suffered from wound CSF leakage

which was managed by placing the lumbar drain for over 7 days which lead to the stoppage of leakage and wound healed uneventfully. Later on, lumbar drain taken out.

None of our patients developed post operative seizures, as all patients had been given intravenous antiepileptic prophylactically post operatively for the period of seven days and then discontinued.

By comparison to other international studies, our results are not discouraging; outcomes and mortality rate are quite comparable to international studies.

In our study, although the rate of infection was 13.34% which is a bit higher as compare to 8% in George, Karl, Rick, Endoscopic third ventriculostomy⁶ and intracranial hemorrhage was 8.89% in comparison to 5% in Feng, Huang, Liao et al, outcome analysis: an Endoscopic third ventriculostomy in the management of obstructive hydrocephalus.⁷ Moreover, the risk of post operative wound CSF is minimal in our study i.e. 2.23% and none of our patient developed post operative seizures. The deficiency to meet the standard sterilization protocol and lack of proper post operative care are the main factors which led to the slightly higher rate of complications. These factors are under continuous scrutiny, hence in the following years appreciable improvement will be evident at our center. As the local studies are lacking the field of endoscopy, there is need to commence a multicenter study regarding the neuroendoscopy in Pakistan.

CONCLUSION

Endoscopic third ventriculostomy is a safe and effective modality of management for obstructive hydrocephalus. Although ETV is associated with some morbidity and mortality that is lesser as compare to ventriculoperitoneal shunt which is the well known procedure for obstructive hydrocephalus. Moreover, the low cost of

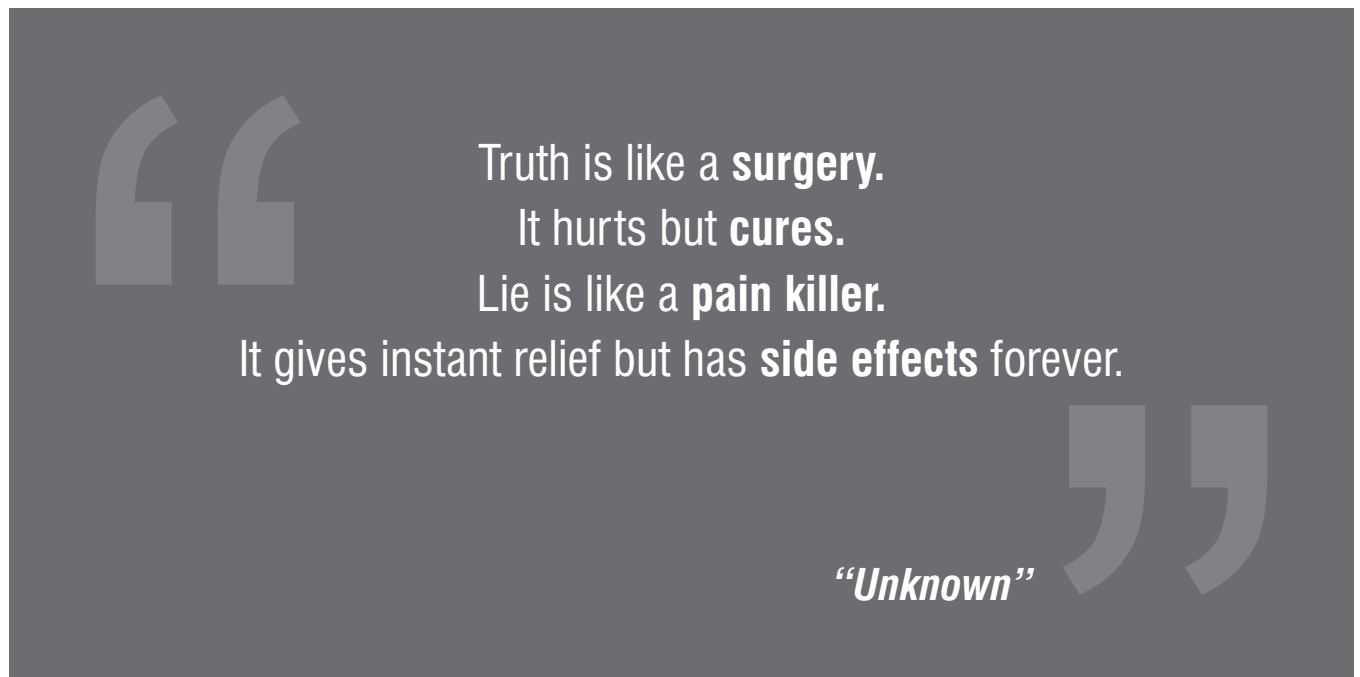
procedure and short hospital stays are extra benefits of Neuroendoscopy.

The results encourage the use of endoscopic third ventriculostomy in obstructive hydrocephalus. It should be the procedure of choice if expertise are available. Rather, it is suggested that endoscopic third ventriculostomy should be carried out in patients who develop acute obstructive hydrocephalus on emergency basis.





Copyright© 15 Nov, 2018.

REFERENCES

1. Mark S. Greenberg. **Hydrocephalus**. In: Handbook of Neurosurgery 6thed. Thieme. 2006:180-207.
2. Paul PW, Anthony M A. **Hydrocephalus in Children**. In: Setti SR, Richard GE. Principles of Neurosurgery. 2nd ed. Elsevier Mosby. 2005.
3. Prusseit J, Simon M, von der Brelie C, Heep A, Molitor E, Volz S et al. **Epidemiology, prevention and management of ventriculoperitoneal shunt infections in children**. J of Pediatric Neurosurg 2009; 5: 325-36
4. Rizwan MB, Abdullah H, Bashir, Attique R, Nayaz A, Ashraf S, et al. **Mechanical complication of ventricular catheter in ventriculoperitoneal shunt surgery and their management**. Pak J of Neurol 2004; 8: 83-7
5. Mumtaz A, Alamgir K, Hamzullah K, Khalid K. **J of pediatric Neurol**. 2009; 7: 165-67
6. George IJ, Karl FK, Rick A. **Endoscopic third ventriculostomy**. Neurosurg Focus 2005; 19: 1-4
7. Feng H, Huang G, Liao X, Fu K, Tan H, Pu H, et al. **Endoscopic third ventriculostomy in the management of obstructive hydrocephalus: An outcome analysis**. J Neurosurg 2004; 100: 626-33.
8. Oi S, Shimoda M, Shibata M, Honda Y, Togo K, Shinoda M, et al. **Pathophysiology of long-standing overt ventriculomegaly in adults**. J of Neurosurg 2000; 92: 933-40
9. Idowu OE, Falope LO, Idowu AT. **Outcome of endoscopic third ventriculostomy and Chhabra shunt system in noncommunicating non-tumor childhood hydrocephalus**. Journal of Peadiatric Neurosci, 2009; 4: 66-9.



AUTHORSHIP AND CONTRIBUTION DECLARATION

Sr. #	Author-s Full Name	Contribution to the paper	Author=s Signature
1	Nauman Shakeel	Data recording and analysis written the manuscript.	
2	Aaamir Aziz	Data recording and analyst.	
3	Muhammad Faaiq Ali	Data analyst	
4	Faheem Usmani	Data analyst	
5	Tariq Salahuddin	Main supervisor, script recording	