



FISTLUA-IN-ANO;

FREQUENCY OF HEALING IN PATIENTS WITH HIGH LYING FISTLUA-IN-ANO UNDERGOING VIDEO ASSISTED ANAL FISTULA TREATMENT (VAAFT).

Mohammad Zarin¹, Muhammad Asim Khan², Syed Asad Maroof Shah³

1. FCPS Gen Surgery (Pak), FMAS (Ind), MRCS (Eng) Associate Professor Department of Surgical D Unit Khyber Teaching Hospital Peshawar.
2. 4th Year General Surgery Resident Department of Surgical "D" Unit Khyber Teaching Hospital.
3. FCPS General Surgery Assistant Professor Department of Surgery Khyber teaching hospital, Peshawar.

Correspondence Address:

Dr. Mohammad Zarin
Room 86 Old Doctor Hostel
Khyber Teaching Hospital Peshawar.
drmzareen@yahoo.co.uk

Article received on:

20/10/2017

Accepted for publication:

25/09/2018

Received after proof reading:

31/01/2019

ABSTRACT... Objectives:To determine the frequency of healing in patients with high lying fistula in ano undergoing video assisted anal fistula treatment. **Study Design:** Descriptive cross sectional. **Setting:** Department of General Surgery, Khyber Teaching Hospital, Peshawar. **Period:** One year (1st April 2014 to 31st March 2015). **Materials and Methods:** Total of 153 patients were observed. Karl Storz Video equipment including Meinero Fistuloscope is used. Key steps are visualization of the fistula tract, correct localization of the internal fistula opening under direct vision and endoscopic treatment of the fistula. This is followed by an operative phase of fulguration of the fistula tract with cautery and using glycine solution mixed with manitol, curetting the tract with curette and fistula brush. Internal opening is closed with a Vicryl 1 suture. **Results:** Our study shows 80% patients were in age range 30-40 years, 17% patients were in age range 41-50 years, 3% patients were in age range 51-60 years. Mean age was 38 years with SD \pm 2.03. Seventy seven percent patients were male and 23% patients were female. Seventy percent patients had healing while 30% patients didn't had healing in the specified duration. **Conclusion:** The main feature of the VAAFT technique is that the procedure is performed entirely under direct endoluminal vision. Moreover, fistuloscopy helps to identify any possible secondary tracts or chronic abscesses. The VAAFT technique is sphincter-saving, and the surgical wounds are extremely small. Our preliminary results are very promising.

Key words: Healing, High Lying Fistula in Ano, Video Assisted Anal Fistula Treatment.

Article Citation: Zarin M, Khan MA, Shah SAM. Fistlua-in-ano; frequency of healing in patients with high lying fistlua-in-ano undergoing video assisted anal fistula treatment (VAAFT). Professional Med J 2019; 26(2):191-195.

DOI: 10.29309/TPMJ/2019.26.02.3078

INTRODUCTION

A fistula-in-ano, or anal fistula which is a chronic abnormal communication and is usually lined to some degree by granulation tissue. It runs from the ano-rectal lumen (the internal opening) outwards to an external opening on the skin of the perineum or buttock.¹ Open surgical treatments include traditional modalities like Fistulotomy and Fistulectomy for low lying fistulae but for high lying fistulae, there is a risk of incontinence if traditional modalities are being utilized.²

Video Assisted Anal Fistula Treatment (VAAFT) is among the new procedures devised for anal fistula. MeineroFistuloscope is used for identification of the external opening, entering fistuloscope in fistula tract and then the tract is cauterized with unipolar electrode. After cauterization the tract is curetted with curette or brush. After identification of the internal opening, it is closed with

absorbable suture. Video Assisted Ano Rectal Fistula Treatment is a novel therapy for anal fistula treatment which was originally devised by P. Meinero. Primary Healing rates were upto 73.5% after 2 to 3 months time and 87% after 1 year of the procedure.² Traditional techniques including Fistulectomy and cutting seton are among the the treatment options in which incontinence rate ranges upto 12% in cases of simple fistulas while the rate is higher in more complicated and recurrent cases.² Video Assisted Anal Fistula Treatment has been introduced in Pakistan recently with supposedly best outcome in the international literature.²

Our Unit has started performing this procedure and has shown promising results. It is a procedure considered to be of benefit and safe in high lying and complex anal fistulas as compared to anal fistula plug and conventional Seton placement.^{3,4}

One study shows that 96% of the patients who underwent fistulotomy and/or fistulectomy were healed and incontinence rates for flatus, soft stool and hard stool post-operatively were 30, 2 and 4% respectively.⁵Fistulectomy and Fistulotomy are still considered the best treatment options so far available for simple cases but is challenging in Complex Fistula in Ano.⁵ After a long term treatment with fibrin glue which was instilled through external orifice, (63.04 %) fistulas closed. It must be thought of as a preliminary option particularly for cryptoglandular and long fistulas.⁶LIFT is a procedure in which internal fistula tract is ligated and it needs long term follow up with higher earlier failure rates and the best healing rate reported to be 62% post-operatively.⁷ Trans-sphincteric fistulas are being treated with the use of Trans-anal advancement flaps with overall success rate of about 75%. Postoperatively 60% had normal continence. Total of 38 % had incontinence for gas or fecal soiling after the procedure while 12 % complained of accidental bowel movement.⁸

VAAFT is a minimal access (endoscopic) surgery and it has been reported to have no perianal wound and no post operative incontinence. As a new modality of treatment in anal fistula, there is not much regional or local data on it. We want to study it in our setup to compare the results with international studies.

OPERATIONAL DEFINITIONS

High Lying Fistula-in-ano

A high lying fistula is when perianal skin is abnormally communicated with the rectum above the ano-rectal ring.

Healing

Healing was defined on the basis of clinical examination as “absence of any perianal discharge or abscess and when both openings (internal and external) are closed at six weeks.”⁹

MATERIAL AND METHOD

This study was done in General Surgery Unit of Medical teaching institute, Khyber Teaching Hospital (KTH), Peshawar from March 2014 to

March 2015. Number of patients included in this study were 153 on the basis of following inclusion criteria.

- All patients of both gender, aging between 16 to 70 years
- Who are having high lying Fistula in Ano of more than two weeks duration
- Diagnosed on examination with Fistuloscope were included.

Following patients were excluded from this study:

- Patients having secondary Fistulas (due to Tuberculosis or crohn’s disease).
- Having colorectal carcinomas.
- Who are immunocompromised like diabetes.
- With Recurrent Fistula in Ano.
- With Low lying Fistula in Ano.

This study was conducted after approval from hospital ethical and research committee. All patients who are having Fistula in Ano were admitted to the ward through OPD. Work up of all the admitted patients was done by taking comprehensive history to exclude confounders and possible bias in the study results. All patients were underwent Digital Rectal Examination and Proctoscopy. All Patients who had their Base line Investigations done including full blood count, random blood sugar levels, hepatitis B & C profile with Enzyme Linked Immunosorbent Assay technique. Karl storz video equipment including MeineroFistuloscope is used. High lying fistula was diagnosed by examining patients under anaesthesia using fistuloscope. During this procedure, fistulous tract is visualized with the help of fistuloscope. After that, correct location of internal fistulous opening is visualized. Then fistula tract(s) whether single or multiple is fulgurated with the help of cautery and glycine solution under the direct endoscopic vision. After that, whole of the tract is cleaned using brush or curette. Internal opening is closed with a Vicryl 1 suture. All the patients had received same antibiotic metronidazole, one dose at the time of surgery and one dose post operatively. Patients were kept in the hospital for 24 hours unless there is indication to keep them for more time. Post operatively patients were assessed after 6 weeks at the follow up visit.

RESULTS

This study was done in General Surgery Unit of Medical teaching institute, Khyber Teaching Hospital (KTH), Peshawar from 1st April, 2014 to 31st March 2015. Number of patients included in this study were 153 who were having high fistula in ano and in which the frequency of healing was determined.

Age distribution among 153 patients was analyzed as 122(80%) patients were in age range 30-40 years, 26(17%) patients were in age range 41-50 years, 5(3%) patients were in age range 51-60 years. Mean age was 38 years with SD \pm 2.03. (as shown in Table-I)

Age	Frequency	Percentage
30-40 years	122	80%
41-50 years	26	17%
51-60 years	5	3%
Total	153	100%

**Table-I. Age distribution (n=153)
Mean and SD was 38 years \pm 2.03**

Among 153 patients, 118(77%) patients were male and 35(23%) patients were female. (as shown in Table No II)

Gender	Frequency	Percentage
Male	118	77%
Female	35	23%
Total	153	100%

Table-II. Gender distribution (n=153)

Duration of disease among 153 patients was analyzed as 58(38%) patients had fistula in ano < 1 month and 95(62%) patients had fistula in ano > 1 month. (as shown in Table-III)

Duration of Disease	Frequency	Percentage
< 1 month	58	38%
> 1 month	95	62%
Total	153	100%

Table-III. Duration of disease (n=153)

Status of healing among 153 patients was analyzed as 107(70%) patients had healing while 46(30%) patients didn't had healing. (as shown in

Table No IV)

Healing	Frequency	Percentage
Yes	107	70%
No	46	30%
Total	153	100%

Table-IV. Status of healing (n=153)

Stratification of healing with age and gender is given in Table-V-VI.

Healing	30-40 years	41-50 years	51-60 years	Total
Yes	85	18	4	107
No	37	8	1	46
Total	122	26	5	153

Table-V. Stratification of healing with age n=153)

After application of Chi Square test, P value was found to be 0.003

Healing	Male	Female	Total
Yes	83	24	107
No	35	11	46
Total	118	35	153

Table-VI. Stratification of healing with gender (n=153)

Chi Square test was applied in which P value was 0.002

DISCUSSION

Our study shows 80% patients were in age range 30-40 years, 17% patients were between 41-50 and 3% patients were in between 51-60 years. Mean age was 38 years with SD \pm 2.03. Seventy seven percent patients were male and 23% patients were female. Seventy percent patients had healing while 30% patients didn't.

In another study done by Meinero Pet al¹⁰ in which 136 anal fistula patients were treated with VAAFT and they were followed upto 3 months. The procedure was successful in 73.5%. Postoperatively, there was no case of fecal incontinence.

Schouten WR et al¹¹ had shown that the overall success rate was 75 %. Postoperatively 60 % had normal continence. Total of 38 % had incontinence

for gas or fecal soiling after the procedure while 12% complained of accidental bowel movement.

In another study conducted by Silveira CR et al¹², mean operating time was about half an hour. Identification of internal opening was successful in approximately 80% of the cases while in one study, 67% patients were found with the internal opening.¹³ Internal opening was closed using absorbable suture. They observed no preoperative or early postoperative complications but when followed for about a year, one patient came with recurrence. In one study, recurrence was observed in 3 out of 40 patients in five months follow up period.¹⁴

In another study conducted by Wilhelm A et al¹⁵ patients were followed for about 7 months and about 82% of them were healed primarily while in our study, healing occurred in 70% patients in the first two weeks. The remaining 30% patients had healing when observed at six weeks which was considered in our study as cut-off duration for healing. One patient presented with mild fecal soiling which improved after few weeks. No other complication was observed.

This is a fact that VAAFT is good at correctly identifying fistulous tracts and postoperatively, patients have got extremely small wounds as compared to open procedures. But, it should be kept in mind that when there is no external opening, insertion of fistuloscope becomes difficult. Sometimes, it becomes necessary to dilate the external wound in order to facilitate insertion of the scope. There is also possibility that either the internal opening or any complex tracts are missed. Some surgeons close internal opening using stapler which increases cost of the procedure. There is difficulty of manipulating the scope in short and acutely angled tracts as the scope is rigid. Therefore, improvement of the technique and further long term studies are required.

CONCLUSION

Uniqueness of VAAFT lies in the fact that whole of the procedure is done under direct vision. It helps to show us if there is/are any complex tract(s) or

other hidden chronic abscess cavities. Beauty of this technique is that it avoids injury to the anal sphincter and patient is having very minimal external wound. Our initial experience was quite encouraging and it is very important to establish its long term efficacy and recurrence rates by doing long term follow ups.

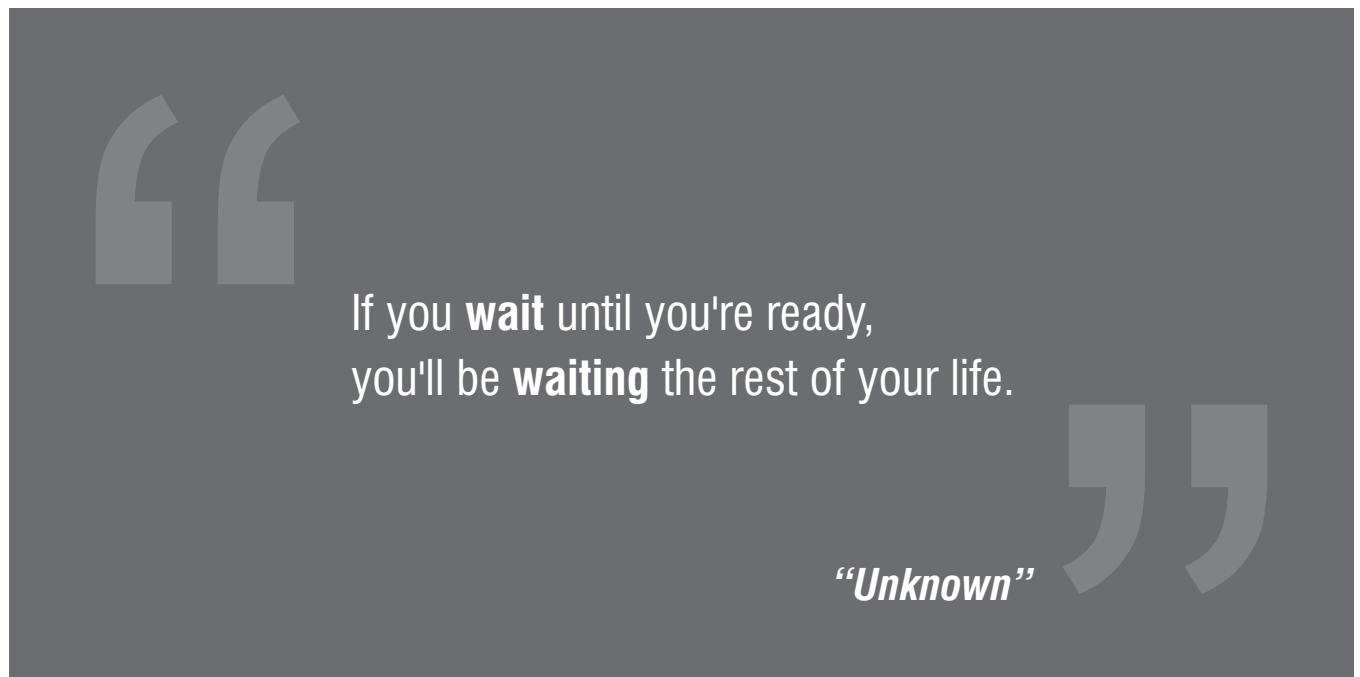
Copyright© 25 Sep, 2018.

REFERENCES



1. Chi-Ming P, Chung-Kei ND, Ho-Yin CM, Shiu-Ki LR, Heng-Tat H. **Recurrence pattern of fistula-in-ano in a Chinese Population.** J Gastrointest Liver Dis 2008 Mar;17(1):53-7.
2. vanKoperen PJ, Bemelman WA, Bossuyt PM, Gerhards MF, Eijssbouts QA, Van Tets WF, Janssen LW, Dijkstra FR, van Dalsen AD, Slors JF. **The anal fistula plug versus the mucosal advancement flap for the treatment of anorectal fistula (PLUG trial).** BMC surgery. 2008 Dec;8(1):11. <https://doi.org/10.1186/1471-2482-8-11>.
3. Sileri P, Cadeddu F, D'Ugo S, Franceschilli L, Blanco GD, De Luca E, Calabrese E, Capperucci SM, Fiaschetti V, Milito G, Gaspari AL. **Surgery for fistula-in-ano in a specialist colorectal unit: a critical appraisal.** BMC gastroenterology. 2011 Dec;11(1):120. doi: 10.1186/1471-230X-11-120.
4. Bleier JI, Moloo H. **Current management of cryptoglandular fistula-in-ano.** World Journal of Gastroenterology: WJG. 2011 Jul 28;17(28):3286. doi: 10.3748/wjg.v17.i28.3286.
5. Mahajan MK, Gupta V, Anand SR. **Evaluation of fustulectomy and primary skin grafting in low fistula in Ano.** JK science. 2007;9:68-71.
6. Bhatti Y, Fatima S, Shaikh GS, Shaikh S. **Fistulotomy versus fistulectomy in the treatment of low fistula in ano.** Rawal Med J. 2011;36(4):284-6.
7. Shawki S, Wexner SD. **Idiopathic fistula-in-ano.** World Journal of Gastroenterology: WJG. 2011 Jul 28;17(28):3277. doi: 10.3748/wjg.v17.i28.3277.
8. Fucini C, Giani I. **Why do we have to review our experience in managing cases with idiopathic fistula-in-ano regularly?.** World Journal of Gastroenterology: WJG. 2011 Jul 28;17(28):3297. doi: 10.3748/wjg.v17.i28.3297.
9. Buchanan GN, Bartram CI, Phillips RK, Gould SW, Halligan S, Rockall TA, Sibbons P, Cohen RG. **Efficacy of fibrin sealant in the management of complex anal fistula.** Diseases of the colon & rectum. 2003 Sep 1;46(9):1167-74. DOI:10.1097/01.

DCR.0000084408.85802.A2. 2014 Mar;27(1):77-81.

10. Meinero P, Mori L. **Video-assisted anal fistula treatment (VAAFT): A novel sphincter-saving procedure for treating complex anal fistulas.** Techniques in coloproctology. 2011 Dec 1;15(4):417-22.DOI10.1007/s10151-011-0769-2.
11. Schouten WR, Zimmerman DD, Briel JW. **Transanal advancement flap repair of transsphincteric fistulas.** Diseases of the colon & rectum. 1999 Nov 1;42(11):1419-22.PMID:10566529.
12. Mendes CR, FERREIRA LS, Sapucaia RA, Lima MA, Araujo SE. **Video-assisted anal fistula treatment: technical considerations and preliminary results of the first Brazilian experience.** ABCD. ArquivosBrasileiros de CirurgiaDigestiva (São Paulo). 2014 Mar;27(1):77-81.
13. Grollich T, Skricka T, Robek O, Kala Z, Hemmelová B, Hrivnák R. **Role of video assisted anal fistula treatment in our management of fistula-in-ano.** ActaChirurgicalugoslavica. 2014;61(2):83-5.
14. Zarin M, Khan MI, Ahmad M, Ibrahim M, Khan MA. **VAAFT: Video assisted anal fistula treatment; bringing revolution in fistula treatment.** Pakistan journal of medical sciences. 2015 Sep;31(5):1233. doi: 10.12669/pjms.315.6836.
15. Wilhelm A. **A new technique for sphincter-preserving anal fistula repair using a novel radial emitting laser probe.** Techniques in coloproctology. 2011 Dec 1;15(4):445-9.doi: 10.1007/s10151-011-0726-0.



AUTHORSHIP AND CONTRIBUTION DECLARATION

Sr. #	Author-s Full Name	Contribution to the paper	Author=s Signature
1	Mohammad Zarin	Concept, design, drafting	
2	Muhammad Asim Khan	Concept, deisgn, literature review, Manuscript writing.	
3	Syed Asad Maroof Shah	Data collection and interpretation/analysis, Final drafting.	