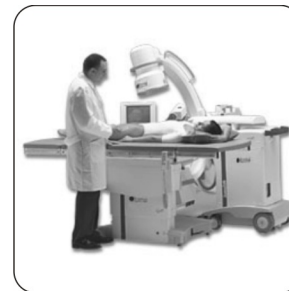

ORIGINAL

PROF-1279

EXTRACORPOREAL SHOCK WAVE LITHOTRIPSY; EFFICACY OF IN SITU ECHOGUIDANCE IN UPPER AND LOWER URETERAL CALCULI.

**DR. AMANULLAH**

Assistant Professor
Deptt: Of Nephrourology
CMCH, Larkana.

DR. ABDUL RASHEED SHAIKH

Associate Professor
Deptt: Of Nephrourology
CMCH, Larkana

DR. QURBAN ALI SHAIKH

Professor and HOD
Deptt: Of Nephrourology
CMCH, Larkana.

Dr. Malik Hussain Jalbani

Associate Professor
Deptt: OF Nephrourology
CMCH, Larkana.

ABSTRACT... amanullah7860@yahoo.com. **Objective:** To assess efficacy of ESWL as a single modality in upper and lower ureteric calculi. **Setting:** department of Nephro-Urology Chandka Medical College Hospital, Larkana. **Period:** January 2003 to April 2006. **Methods and materials:** 62 patients underwent ESWL. Upper and lower ureteral calculi were treated by using Dornier MPL-9000 Lithotripter with ultrasound localization. **Results:** Among 62 cases 56(90.3%) patients had upper ureteric calculi, whereas 06(9.7%) patients had lower ureteric calculi. Size of stones ranged from 0.5 mm to 18mm having mean size of 10mm. All patients were followed for period of 6 weeks. Of these 62 patients 58 patients were stone free at the end of 2 weeks follow up. In 2 cases stones failed to fragment, where as 2 cases failed to attend out patient department for follow up. **Conclusion:** This study concluded that in situ echoguided ESWL was effective modality of treatment for upper and lower ureteric stones. Localization of ureteric stones with ultrasound has the advantage of elimination of radiation exposure to the patient and lithotripsy team.

Key words: Ureteric calculi, ESWL

INTRODUCTION

Urinary lithiasis has been a major urological problem, especially in stone belt countries like Pakistan. The earliest dating recorded cases of bladder and kidney stones were found in Egyptian mummies dating back to 4800 B.C¹. Urolithiasis constitutes about 10% to 25% of the total work load in the urological practice².

Since the early 1980s Extracorporeal Shock Wave

Lithotripsy (ESWL) has proved to be a safe and effective technique for fragmentation of renal stones^{3,4}. Later on ureteric stones were included using radiological imaging by fluoroscope. The disadvantages of radiation exposure with fluoroscopy both the patient and lithotripsy team are well documented. The visualization of ureteric stones on ultrasound for ESWL treatment is some times difficult because imaging of full ureter with ultrasound is not possible. Therefore, we selected a group of those

patients who has ureteric stones located at extreme level of ureter, either at upper or lower end. The image of stone location at these levels is quite possible with ultrasound. Lithotripsy machine installed in our institution has dual imaging system ultrasound and fluoroscope, but we have tried to locate upper and lower ureteric calculi by ultrasound because ultrasound localization of ureteral calculi has advantage of eliminating radiation exposure to patient, and lithotripsy team.

The aim of our study was to see efficacy of in situ echoguided ESWL of upper and lower ureteral calculi with Dornier MPL-9000 lithotripter.

PATIENTS AND METHODS

Between January 2003 and April 2006, a total of 62 cases whose ureteric stones were localized by ultrasound were enrolled into this study out of 100 patients of ureteric stones seeking treatment at the department of Nephrourology Chandka Medical College Hospital, Larkana. The criterion for selection of patient was preferably adult patients having single ureteric stone located at upper or lower end of ureter. A prescribed proforma was filled for each of these 62 cases. This Proforma contained demographic data and data about the clinical features of the patients they presented with. The history, physical examination and investigations were performed for each patient. All patients were treated with Dornier MPL-9000 lithotripter on an out-patient basis. No general or regional anesthesia was given, in few cases only intramuscular analgesia was used to relieve pain during ESWL.

The Dornier MPL-9000 is a multipurpose lithotripter, generating an electrohydraulic shock wave by a spark gap at the primary focus. A semi-ellipsoidal reflector reconverges the shock wave at the second focal point (F2). The Dornier MPL-9000 lithotripter is equipped with fluoroscope and a high resolution, real time ultrasound transducers for stone localization.

The shock waves were synchronized with the R-wave of the electrocardiogram to avoid cardiac dysrhythmias. In each session 1600 -2200 shock waves were administered with the voltage ranged from 14 kv to 18 kv.

Treatment time ranged from 30 to 45 minutes.

In upper ureteric stones the patient was placed in the lateral decubitus position over the water cushion of the lithotripter. Initially the target cross was positioned at the dilated pelviureteric junction and the dilated ureter was followed down until the stone appeared.

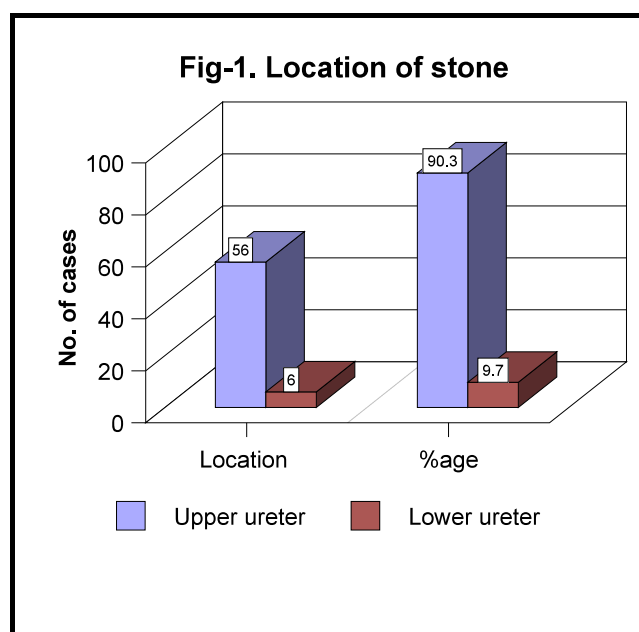
For lower ureteric stones an anterior approach was used. The patient placed in the prone position. The water cushion of the lithotripter was kept on hypogastric region. A full urinary bladder was required to act as an acoustic shadow for visualization of lower ureter.

All Patients were followed up fortnightly for 6 weeks. In every case check X-ray KUB and Ultrasound was performed to assess the outcome.

RESULTS

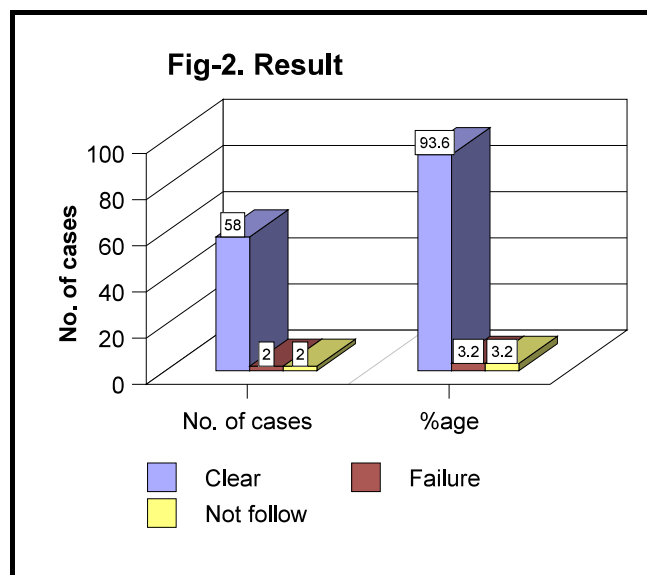
Our study comprises of 62 selected adult patients among them 47 (75%) were males and 15 (24%) females. The male to female ratio was 2:1. The mean age was 30 + years (mean + SD) ranging from 8 to 60 years.

In 56 (90%) and 6 (9.6%) cases, the stone was present in upper and lower end of ureter respectively (Fig.No.1).



In 32 (51%) cases the stone was present on left side and in 30 (49%) on right side. The size of stone ranged from 0.5 mm to 18 mm, mean size was 10 mm.

Fifty eight (93%) cases were stone free after one session of ESWL, in 2 (3%) cases ESWL failed to disintegrate stones, remaining 2 (3%) cases lost follow-up (Fig.No.2).



No major complications were observed during follow up of these patients, except pain and mild hematuria in first 24 hours.

DISCUSSION

The Dornier MPL-9000 lithotripters with ultrasound system allow good visualization of upper and lower ureteric stones. The principal advantage of the ultrasound in In situ ESWL treatment is continuous stone monitoring with an immediate correction of the focal area positioning after any accidental movement of the patient or of the stone. The advantages of ultrasound localization over fluoroscopy are superceded, but considerable experience is required to identify ureteric stones by ultrasound.

In our study fifty eight (93%) cases were stone free after one session of ESWL treatment, these results are comparable with the results of R. Frabboni, F.R.Jermini and Voce S., who reported 96%, 90% and 95.5% respectively success under the same selection

criteria^{5,6,7}.

We observed no fragmentation in stone > 15 mm in diameter, similar observation was reported by Tiselius⁸. We did not come across with major complications except pain and mild hematuria in first 24 hours. These results are comparable to the study presented by R. Frabboni. In our study the lithotripsy was done on the patients while they being in prone position and in none of the cases under this study developed melena and other gastrointestinal symptoms. This is not compatible with the study conducted by Jenkins et al⁹, who reported the gastrointestinal symptoms while the lithotripsy being carried out in the patient in prone position

CONCLUSION

This study concludes that In situ echoguided ESWL is effective method for the treatment of both upper and lower ureteric stones. It eliminates the hazard of radiation to the patient and lithotripsy team but requires expertise.

REFERENCES

1. Mani Mevon, m.d. **Urinary lithiasis Campbell's Urology** 7th ed. 1998. p.p 2662.
2. Javed SH, Khan JH, Iqbal Z. Iqbal S. Khan FA. **Aetiology upper tract Urolithiasis in RahimYar Khan.** Pak.Post.med J 1993 4 (2); 81-98.
3. Chaussy C, Schmidt E, Jocham D, Brendel W, Forssmann B, Walter V. **First clinical experience in situ with extracorporeally induced destruction of kidney stones by shock waves.** J Urol 1982; 127:417-20.
4. Drago JR, Nesbitt JA, Swith JJ et al. **ESWL treatment of urinary calculi.** Urology 1989; 33: 400-3.
5. R. Frabboni. **In situ echoguided extracorporeal shock wave lithotripsy of ureteric stones with the Dornier MPL-9000: a multicentric study group.** Br J Urol 1994 May;73(5):487-93.
6. Jermini FR. **Noninvasive anesthesia, analgesia and radiation-free extracorporeal shock wave lithotripsy for stones in the most distal ureter: experience with 165 patients.** J Urol. 2002 Aug;168(2):446-9.
7. Voce S. **"In situ"echo-guided extracorporeal shock**

- wave lithotripsy of ureteral stones.** Methods and results with Dornier MPL-9000. Scand J Urol Nephrol.1993;27(4):469-73.
8. Tiselius HG, **Anaesthesia-free in situ extracorporeal shock wave lithotripsy of ureteral stones**, J Urol 1991; 146:8.
9. Jenkins AD, Gillenwater JY, **Extracorporeal Shock wave Lithotripsy in the prone position: treatment of stones in the distal ureter or anomalous kidney**, J Urol 1988; 139: 911-15.

**WHEN YOU DON'T GET ANYTHING;
YOU GET EXPERIENCE.**

Shuja Tahir