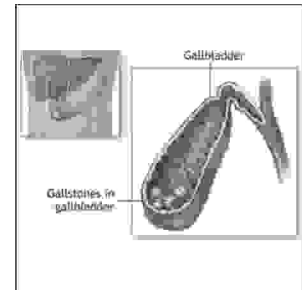


ORIGINAL

PROF-1306

## ACUTE ABDOMEN; CAUSES



**DR. MUHAMMAD ASIF**  
**FCPS (General Surgery)**  
 Surgical Specialist  
 PAF Hospital, Lahore.

**DR. DANISH ALMAS**  
**FCPS (General Surgery)**  
 PNS Hospital, Hafeez, Islamabad.

**DR. JAVED SAJJAD HASHMI**  
**FCPS (General Surgery)**  
 PAF Hospital, Islamabad.

**ABSTRACT...** [masifazim@hotmail.com](mailto:masifazim@hotmail.com) **Introduction:** The term “acute abdomen” denotes any sudden spontaneous non-traumatic disorder whose chief manifestation is in the abdominal area. There is frequently a progressive underlying intra-abdominal disorder, the correct early diagnosis and treatment of which is essential for a favorable outcome. **Objectives:** (I) To find out the most common causes of acute abdomen. (II) To compare the preoperative assessment with postoperative diagnosis. **Design:** A Non-interventional Analytical (Comparative) study. **Setting:** Emergency department of Combined Military Hospital Kharian. **Period:** Oct 2001 to Mar 2002. **Patients & Methods:** Total of 220 patients who presented with acute abdomen. **Results:** The most frequent cause was found to be Acute Appendicitis, followed by Nonspecific abdominal pain, acute cholecystitis, acute intestinal obstruction and perforated duodenal ulcer. Preoperative diagnosis was wrong in 9.5% (n=21) of cases. **Conclusion:** Acute appendicitis was found to be the most common cause of acute abdomen and the single most important cause of acute abdominal pain causing great diagnostic difficulties. the preoperative diagnostic accuracy can be increased especially in female of child bearing age by using modern diagnostic tools especially laparoscopy.

**Key words:** Acute Abdomen, Abdominal Pain, Abdominal Emergencies

### INTRODUCTION

The acute abdomen refers to the clinical situation in which an acute change in the condition of the intra abdominal organs, usually related to inflammation or infection, demands immediate and accurate diagnosis<sup>1</sup>. Acute abdominal pain is one of the most frequently encountered symptoms in patients seeking emergency

department attention and is the most common presenting complaint in patients with surgical diseases of the abdomen<sup>2</sup>. From the surgical point of view acute abdominal pain is the cardinal symptom of acute abdomen.

The syndrome of acute abdominal pain generates a

large number of hospital visits. Conditions resulting in an acute abdomen can cause serious complications or even death, especially if there is a delay in diagnosis and appropriate therapy, but as pointed out by Cope, "The term acute abdomen should not be equated with the invariable need for operation"<sup>3</sup>.

The range of disease, extends from the relatively trivial to the immediately life-threatening and attempts to reach a diagnosis must sometimes be curtailed in the interests of immediate treatment. More commonly there is time to take a history, to examine the patient, and to organize the investigations, which will be helpful in establishing a diagnosis and planning treatment. Accurate recording of the relevant facts is vital and a clear understanding of the anatomy and pathophysiology of intra-abdominal disease is necessary for both diagnosis and treatment. These patients are therefore ideal for training junior members of a surgical team.

The immediate feedback that an emergency operation provides on the accuracy and the adequacy of the preoperative assessment and preparation is another reason why the patient with an acute abdomen is an important part of surgical training.

The acute abdomen is test of clinical acumen of the clinician. An accurate and comprehensive history of the events surrounding the onset of pain and knowledge of the nature of pain, its location and accompanying symptoms are crucial in developing a differential diagnosis. The vital signs may be normal during the initial phases of the illness, with an elevated temperature and hypotension occurring in the latter stages. Information from the patient's history, physical examination, laboratory tests, and imaging studies usually permits a reasonably correct diagnosis, but uncertainty can still remain. Because appendicitis is a common disease, it must remain in the differential diagnosis of any undiagnosed patient with persistent abdominal pain, particularly the right lower quadrant pain<sup>4</sup>.

The rationale of the study is to find out the frequencies and patterns of different diseases presenting as acute

abdomen specific to the locality where the study is carried out; To judge the importance and accuracy of clinical diagnosis by comparing pre-operative and post-operative diagnosis; To prioritize the resources according to the most common causes of acute abdomen; To find out the importance of a variety of laboratory and imaging modalities in confirming the diagnosis, so that the facilities can be provided if not already existing and last but not the least; To acquaint ourselves of the rare causes of acute abdomen presenting in the common way.

### **PURPOSES OF STUDY**

Objectives of this study were;

- 1) To find the most common causes of acute abdomen and
- 2) To compare the preoperative and post operative diagnoses.

### **MATERIALS AND METHODS**

The study was carried out in the emergency department of Combined Military Hospital Kharian from Oct 2001 to Mar 2002. Most of the patients were soldiers, their families and dependent parents. All patients presenting with non-traumatic acute abdomen to the emergency department of Combined Military Hospital Kharian were included in the study.

On arrival in the emergency department detailed history and clinical examination along with routine laboratory and radiological investigations were obtained and a preoperative diagnosis was made followed by operative management, if indicated, which either confirmed or refuted the preoperative diagnosis.

**Study design:** Non-interventional analytical (comparative) type.

- 1) Sampling technique: Non probability convenient sampling.
- 2) Sample size: 220 patients were included in the study.
- 3) Inclusion criteria:
  - a. Patients of all age groups.
  - b. Both male and female patients were

- included.
- 4) Exclusion criteria:
    - a. All patients with blunt and penetrating trauma to the abdomen.
    - b. Patients with medical causes of acute abdomen.
  - 5) Data was collected from the patient's proforma and results were analyzed by calculating the frequencies of the causes of acute abdomen. The preoperative and postoperative causes of these cases were then compared to find out the clinical accuracy of diagnosis.

## RESULTS

The most frequent cause was found to be acute appendicitis (21.4%), followed by nonspecific abdominal pain (15.4%), acute cholecystitis (12.7%), acute intestinal obstruction (14.5%), perforated duodenal ulcer (11.8%), renal colic (9%), acute pancreatitis (4%), acute gynaecological disorders (4%), mesenteric ischemia (0.9%), meckel's diverticulitis (1.3%), gastrointestinal perforation (1.3%), ileo-caecal tuberculosis (1.3%), perforated liver cell carcinoma (0.4%), Ruptured giant liver abscess (0.4%), emphysematous pyelonephritis (0.4%) and typhlitis (0.4%).

Preoperative diagnosis was wrong in 9.5% (n=21) of cases. Negative appendicectomy rate of 27.7% (n=18) was found. On seven (10.8%) occasions no other pathology was found and patients were labelled as having NSAP, five (7.7%) cases of acute gynaecological problems were identified after opening the abdomen through gridiron incision on suspicion of acute appendicitis. Three (4.6%) cases of meckel's diverticulitis, and 01 case (1.5%) each of ileo-caecal tuberculosis, typhlitis and right ureteric calculus was found.

Appendicectomy was performed in all above cases except in ileo-caecal tuberculosis and typhlitis, to avoid future diagnostic confusion. In the case of right ureteric calculus preoperative USG abdomen revealed right sided mild hydronephrosis but no evidence of stone was found, it was confirmed only after an IVU which was performed

due to the persistence of symptoms after appendicectomy.

One case (0.45%) each of perforated jejunal diverticula and perforated appendix with free air under diaphragm was pre-operatively diagnosed as perforated duodenal ulcer. One patient, in whom left ureteric stenting was done for ascending pyelography, developed fever, severe abdominal pain and distension after the procedure, plain X-ray abdomen revealed free air under diaphragm, emergency exploratory laparotomy was carried out on the suspicion of iatrogenic gut injury; but peroperatively no breach in gastrointestinal tract was found, rather emphysematous pyelonephritis was confirmed.

## DISCUSSION

Common things occur commonly. The most common surgical causes of acute abdominal pain in a patient admitted to a hospital anywhere in the world is acute appendicitis. Our study also revealed acute appendicitis to be the most common cause followed by NSAP (Non specific abdominal pain).

In our study preoperative diagnosis was wrong in (n=21) 9.5% of cases, indicating the need for using other diagnostic tools besides detailed history, clinical examination and routine investigations.

It is recommended that ultrasonography of abdomen and pelvis should be done routinely in every female patient with acute lower abdominal pain to rule out gynaecological causes of acute abdomen. In our study we did not use ultrasonography routinely in every female patient leading to misdiagnosis of five cases of acute gynaecological emergencies as acute appendicitis. We had a negative appendicectomy rate of 27.7%, although about 25 to 40 % negative appendicectomy rate is still acceptable<sup>5</sup>. This figure can be brought down by using diagnostic laparoscopy, in patients having difficulty in clinical diagnosis.

A comparison of different studies with that of our study is shown in table-I. Diagnostic laparoscopy was used in the

study conducted at civil hospital Quetta, on patients in whom the diagnosis could not be made clinically. There was no case labelled as having NSAP, clearly indicating the high diagnostic yield of laparoscopy<sup>6</sup>. A similar study conducted at the University Of Ghana Medical School, Accra, revealed comparable results to that of our study<sup>7</sup>.

The clinical spectrum of the acute abdomen in our as well as in this study showed that the surgeons in developing countries are facing challenges similar to those of their counterparts in developed countries and the most important diagnostic distinction surgeons have

to make is that between acute appendicitis and non specific abdominal pain. Series of 173 cases of acute abdominal surgical emergencies from a hospital in rural sierra Leone revealed acute gynecological emergencies, especially ectopic pregnancy, and intestinal obstruction, majority of which was due to strangulated hernia to be the most common causes followed next in list by acute appendicitis<sup>8</sup>. Analysis of 3727 patients during the first quarter of 1995, at the surgical clinics of the nine hospitals with emergency departments in the country of Stockholm, revealed the frequencies of different causes of acute abdomen<sup>9</sup> as shown in table-I.

**Table-I. A comparison of different studies with that of our study is shown below.**

Causes	1	2	3	4	5
Acute appendicitis	21.4	60	23.5	10.9	08
NSAP	15.4	-	21.4	-	24
Acute cholecystitis	12.7	18.6	-	-	09
Acute intestinal obstruction	14.5	1.4	10.8	29.5	07
Perforated DU / Peptic ulcer	11.8	-	9.2	4.6	06
Renal colic	9	-	-	-	06
Acute pancreatitis	4	-	-	-	05
Acute gynecological disorders	4	14.3	9.5	34	-
Acute mesenteric ischaemia	0.9	-	-	-	-
Acute mecke's diverticulitis	1.3	-	-	-	-
Gastrointestinal perforation	1.3	2.8	-	-	-
lieo-caecal tuberculosis	1.3	-	-	-	-
Intra abdominal malignancy / perforated liver cells carcinoma	0.45	-	-	-	-
Ruptured giant liver abscess	0.45	1.4	-	-	-
Emphysematous pyelonephritis	0.45	-	-	-	-
Typhlitis	0.45	-	-	-	-
Pelvic abscess	-	1.4	-	-	-
Acute diverticulitis	-	-	-	-	5
Gastrointestinal haemorrhage	-	-	-	-	5
Others	-	-	-	20.8	19

**Key:** 1) % of own study 2) Study conducted at civil hospital Quetta 3) Study conducted at University of Ghana Medical School, Accra. 4) Study Conducted at Rural Sierra Leone 5) Study conducted at the Surgical Clinics of Stockholm.

A study carried out at JPMC Karachi, revealed that about 20% of all admissions for the abdominal conditions were of intestinal obstruction while this number was 13% in our study<sup>10</sup>.

Another study conducted in Germany revealed that the most frequent cause was acute appendicitis, followed by cholecystitis and by diverse forms of ileus. These three diseases together were the causes of acute abdomen in more than 80% of cases<sup>11</sup>. Analysis of 229 cases of acute abdomen surgically managed at Yirgalem Hospital from Jan to Dec 1997 revealed small intestinal obstruction due to volvulus, the most common cause, followed by acute appendicitis, large intestinal obstruction due to volvulus of sigmoid colon, typhoid perforation, primary peritonitis, perforated gastroduodenal ulcer, abdominal tuberculosis, and empyema of gallbladder in that order, were the other observed causes<sup>12</sup>.

Making the correct diagnosis is never easy. It demands attention to detail in taking the history and examining the patient and clarity of thought in analyzing the information that is obtained. Investigations may help but in many places in the world there are no facilities for further investigations. There the management of every patient depends entirely on the clinical skills of the doctor. Patients labelled as having NSAP does not mean that there was no cause. It does mean that our skill in making a diagnosis needs to be improved and new diagnostic tools should be used wherever necessary to improve diagnostic accuracy and better patient management.

## CONCLUSION

Acute appendicitis was found to be the most common cause of acute abdomen and the single most important cause of acute abdominal pain causing great diagnostic difficulties, with a negative appendicetomy rate of 27.7%. NSAP, acute cholecystitis, intestinal obstruction, perforated duodenal ulcer, renal colic, acute pancreatitis and acute gynaecological disorders were among other major causes of acute abdomen.

Meckel's diverticulitis, mesenteric ischaemia, ileocaecal tuberculosis, perforated liver cell carcinoma, ruptured giant liver abscess, emphysematous pyelonephritis and typhilitis were among the rare causes of acute abdomen.

Although detailed medical history, clinical examination and routine investigations can lead to correct preoperative diagnosis in more than of 90% of cases, the preoperative diagnostic accuracy can be increased especially in female of child bearing age by using modern diagnostic tools especially laparoscopy.

## REFERENCES

1. Kauffman GL. **Acute Abdomen** In: Corson JD, Williamsons RC eds. *Surgery*. 1<sup>st</sup> ed. Spain: Mosby International Limited, 2001:1-14.
2. Vitello JM. **Acute Abdominal pain** In: **Manual of Surgical Therapeutics**. 8<sup>th</sup> ed. Boston: Little Brown, 1993:153.
3. Cope Z. **The principles of diagnosis in acute abdominal disease** In: Cope's early diagnosis of the acute abdomen. 19<sup>th</sup> ed. New York: Oxford University Press, 1996:3-18.
4. Borgstein PJ, Gordijn RV, Ejsbouts QA, Cuesta MA. **Acute appendicitis - a clear-cut case in men, a guessing game in young women: a prospective study of the role of laparoscopy**. *Surg Endosc* 1997; 11: 923-927.
5. Bhopal FG, Khan JS, Iqbal M. **Surgical audit of acute appendicitis**. *Jcpsp* 1999; 9(5) 233-6.
6. Baloch MA. **Laparoscopy in acute abdomen**. *Journal of surgery Pakistan* 1998; 3(2): 6-8.
7. Naader SB, Archampong EQ. **Clinical spectrum of acute abdominal pain in Accra, Ghana**. *West Afr J Med* 1999; 18(1) 13-6.
8. McConkey SJ. **Case series of acute abdominal surgery in rural Sierra Leone**. *World J Surg* 2002; 26 (4): 509-13.
9. Fengo G, Boijesen M, Enochsson L, Goldinger M, Grondal S, Lundquist P et al. **Acute abdomen calls for considerable care resources**. *Lakartidningen* 2000; 97 (37): 4008-12.
10. Malik K, Ahmed W, Channa A, Khan A, Waheed I. **The pattern of the intestinal obstruction in JPMC, Karachi**. *Jcpsp* 1991; 1(1): 32-5.
11. Largiader J. **Acute abdominal pain, surgeons view point**. *Schweiz Rundsch Med Prax* 1977; 86(6): 209-13.
12. Asefa Z. **Pattern of acute abdomen in Yirgalem hospital, Southern Ethiopia**. *Ethiop Med J* 2000; 38(4): 227-35.